

Case of Cyanotic Heart Disease with Partial Anomalous Pulmonary Vein Connection for Cesarean Section

Nagasobbanaa Manukaran¹, Balaji J.², Ravi Madhusudhana³

How to cite this article:

Manukaran Nagasobbanaa, Balaji J., Ravi Madhusudhana. Case of Cyanotic Heart Disease with Partial Anomalous Pulmonary Vein Connection for Cesarean Section. Indian J Anesth Analg. 2024;11(1) 41-47.

Abstract

Introduction: Partial anomalous pulmonary venous connection is the type of cyanotic disease defined as one or more, but not all pulmonary veins drain directly either into a systemic vein or into the right atrium. Subarachnoid block in the form of spinal anesthesia is given as it minimizes SVR changes, and provides sufficient anesthesia of perineum/pelvic organs, sensory and motor blockade of lower limbs, allowing early ambulation, voiding, and hospital discharge.

Case Report: A 29-year-old female, G2P1L1, BMI of 25 with 32 weeks 5 days gestational age with 8 months of amenorrhea posted for emergency lower segment cesarean section (LSCS). Preanaesthetic evaluation was done and the patient underwent LSCS under spinal anesthesia without any intraoperative difficulty or complications.

On POD-9, the patient developed breathlessness with a fall in oxygen saturation and required Intensive care unit (ICU) support. A 64-slice CT pulmonary angiogram was done and showed changes suggestive of Partial Anomalous Pulmonary Vein Connection (PAPVC).

The patient was worked up, diagnosed with PAPVC, and symptomatic treatment initiated. Once symptomatically better, prophylactic management is advised and the patient is discharged.

Conclusion: Patients with PAPVC with stable hemodynamics can be managed successfully with spinal anesthesia as the mode of anesthesia for surgical procedures.

Keywords: Partial anomalous pulmonary venous connection; Spinal anesthesia; Pregnancy; LSCS.

Key Messages: Patient coming with Total anomalous pulmonary vein connection will

have gross defect with haemodynamic imbalance, our case came with partial pulmonary venous connection with asymptomatic patient who had progressed to adulthood. Her condition was detected post-partum period when she developed drop in saturation and was further evaluated after her uneventful caesarean section under Subarachnoid block. Hence, this case was managed successfully under regional anesthesia. Screening ECHO should it be done in all parturients is a recommendation/query from our article.

Author's Affiliation: ¹Junior Resident, ²Consultant, ³Professor, Department of Anesthesiology, Sri Devaraj Urs Medical College, Sri Devaraj Urs Academy of Higher Education and Research, Kolar 563101, Karnataka, India.

Corresponding Author: Ravi Madhusudhana, Professor, Department of Anesthesiology, Sri Devaraj Urs Medical College, Sri Devaraj Urs Academy of Higher Education and Research, Kolar 563101, Karnataka, India.

E-mail: ravijaggu@gmail.com

Received on: 21.11.2023

Accepted on: 02.01.2024

INTRODUCTION

Cyanotic heart diseases are a group of diseases with heart defects that are present at birth, whereby these defects result in a low blood oxygen level due to the presence of right to left shunts. Among the list of cyanotic heart diseases are total and partial anomalous venous connections.

Partial anomalous pulmonary venous connection is the type of cyanotic disease defined as one or more, but not all pulmonary veins drain directly either into a systemic vein or into the right atrium. It is often detected accidentally in adults with right heart dilatation during work-ups. There are various possible anomalous connections, the most common being a left upper pulmonary vein draining to the superior vena cava. Concomitant pulmonary hypertension can be present simultaneously, however, is uncommon. Symptoms may be absent or minimal depending on the number of pulmonary veins involved in the anomalous connection.

The blood shunting through ASD in partial anomalous pulmonary venous circulation (PAPVC) is regulated by the ratio of systemic vascular resistance (SVR) to pulmonary vascular resistance (PVR). Thus, as SVR increases (adulthood), there is a drop in right-to-left shunting. As for PVR, assuming no infundibular or valvular pulmonary stenosis changes the pulmonary blood flow inversely to a lesser degree. The major intraoperative concern is the development of cyanotic spells due to changes in the circulation dynamics.

CASE REPORT

A 29-years old female, G2P1L1, BMI of 25 with 32 weeks 5 days gestational age with 8 months of amenorrhea with good fetal movement appreciation was referred to the hospital in view of intrauterine growth retardation of the fetus with brain sparing effect for further management.

During the antenatal follow-up of the current pregnancy done at a private nursing home, the patient was evaluated and echocardiography revealed a left ventricular ejection fraction of 56%, pulmonary artery hypertension, (PASP) - 50 mmHg, dilated right-sided chambers, mild tricuspid regurgitation, reduced right ventricular function, intra-atrial septum which is intact, thin at fossa ovalis.

The patient has also a history of undergoing a lower segment cesarean section (LSCS) 6 years ago

due to non-progressive labor at SNR hospital. It was uneventful and the child is healthy and alive now. The previous LSCS was done under spinal anesthesia.

On admission, Haematological parameters were normal. (Haemoglobin: 17.5 g/dl, RBC: 5.62 mil/mm, PCV: 50.9%, Platelets 173 T/mm³, WBC 13.97 T/mm³ m%). The coagulation profile was within normal limits. (PT: 16.1, INR: 1.3, BT: 2'30", CT: 4'30") Liver Function Test (LFT) was normal. Renal Function Test (RFT) was normal. On examination, the patient was conscious, and oriented to time, place, and person. Pallor was present. No clubbing, icterus, lymphadenopathy, clubbing, cyanosis, or edema.

During the pre-anesthetic evaluation, the patient was stable vital parameters wise. (Pulse: 88 beats per minute, blood pressure 120/80 mmHg, Respiratory rate: 18 cycles per minute, Temperature: Afebrile). Examination of the cardiovascular system revealed loud p₂, S1S2 heard while examination of the respiratory system revealed normal vesicular breath heard. Central nervous system examination showed a conscious and oriented patient (GCS 15/15). Examination of pupils revealed bilaterally reactive pupils. Abdominal examination revealed a uterus of 30-32 week size, cephalic presentation, and Pfannenstiel scar present.

Given the urgent nature of surgery with Doppler changes suggestive of fetal distress and a history of previous LSCS, the patient was planned for emergency LSCS under spinal anesthesia. The case was accepted for surgery under ASA IV (E) physical status and written informed consent was obtained.

In the pre-operation theatre area, an 18G IV cannula was secured and checked for patency, and IV fluid was initiated after ensuring all intravenous line tubing was free of air bubbles. A test dose of antibiotics was given before shifting into the Operation Theatre (OT).

Upon shifting into OT, the temperature was fixed at 22 °C, and baseline vitals were noted. (Baseline BP 130/100 mmHg, heart rate (HR) 110/min, and SpO₂-94%. After ensuring the IV line was patent and IV fluid was on flow, the patient was made to sit.

Following aseptic precautions, parts were painted and draped. With sterile precautions, L3-L4 space was identified using anatomical landmarks. Using a 25G Quincke needle, lumbar puncture was done at L3-L4 space, and after confirming continuous backflow of cerebrospinal fluid (CSF) and negative aspiration of blood, subarachnoid block given

with 2 ml of 0.5% Bupivacaine (hyperbaric). After ensuring adequate motor and sensory blockade was achieved (till T6), the surgical procedure started. A single live female baby weighing 1.14 kg was delivered. The baby cried immediately after birth and was shifted to the Neonatal Intensive Care Unit (NICU) because of low birth weight and preterm for further management.

The duration of the surgery was around one and a half hours. Intraoperatively, the patient remained stable with arterial oxygen saturation (SaO₂) ranging between 94-88%. She was supplemented with oxygen-5L/min via face mask when the intra-operation SaO₂ dropped to less than 90%. Normal saline and Ringer lactate were used as maintenance fluid during surgery and about 450 ml of blood was lost and 300 ml of urine output replaced. Warmer was placed at 35°C to avoid hypothermia. She was comfortable throughout the procedure while maintaining stable vitals. After the surgical procedure, she was shifted to the post-operation area where she maintained stable vitals and was monitored till the spinal anesthesia had regressed with the gradual return of motor movements.

However, on Post-operative Day (POD)-9, the patient complained of persistent breathlessness, and room air SaO₂ dropped to 60%. Immediately, oxygen therapy of 15 L via face mask was started and the patient was shifted to the Intensive Care Unit (ICU) for further management. In ICU, initially, 15 L oxygen therapy continued, since there was no improvement in SaO₂, the patient was put on a High flow mask (humidified) with 15 L oxygen. Physician opinion was sought for breathlessness.

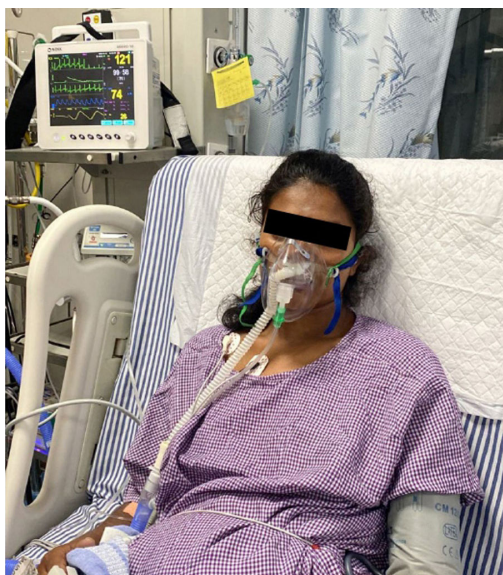

Fig. 1: POD-9, Patient on High-flow nasal cannula along with face mask.

Reproduced with the Permission of the Patient

Electrocardiography (ECG) and repeat 2D-echocardiogram were done as per physician orders. As the ECG showed changes suggestive of Right axis deviation and Repeat 2D-echocardiogram reported dilated Right Atrium (RA) and right ventricle (RV), mildly dilated pulmonary artery (PA), Mild regional wall motion abnormality (RWMA), Mild mitral regurgitation (MR), Mild tricuspid regurgitation (TR), Mild aortic regurgitation (AR), mildly dilated inferior vena cava (IVC), RV dysfunction, PAPVC+, left ventricular ejection fraction (LVEff): 60%, cardiologist was consulted regarding further management of the patient.

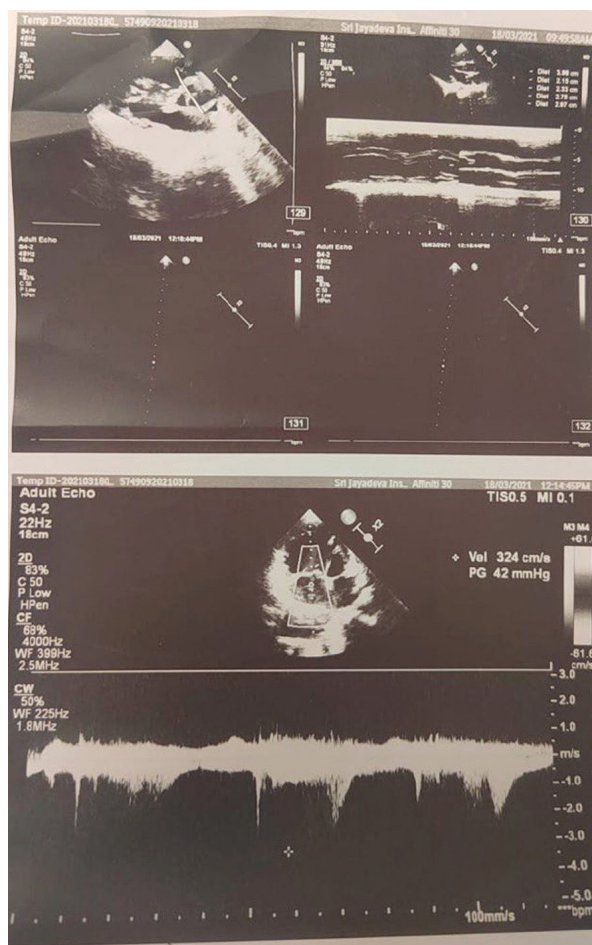


Fig. 2a: 2D-echocardiogram shows dilated Right Atrium (RA) and right ventricle(RV), mildly dilated pulmonary artery (PA), Mild regional wall motion abnormality (RWMA), Mild mitral regurgitation (MR), Mild tricuspid regurgitation (TR), Mild aortic regurgitation (AR), mildly dilated inferior vena cava (IVC), RV dysfunction, PAPVC+, left ventricular ejection fraction (LVEff): 60% (Reproduced with the permission of the patient)

The cardiologist in return had requested a 64-slice CT pulmonary angiogram which showed the right upper lobe pulmonary vein drains into the posterolateral aspect of superior vena cava (SVC)

approximately 44 mm cranial to SVC-RA junction: Suggestive of PAPVC. Nor features suggestive of sinus venosus anomaly. The main pulmonary

artery measures 37 mm, dilated. Right middle pulmonary vein, and right inferior pulmonary vein drain into LA.

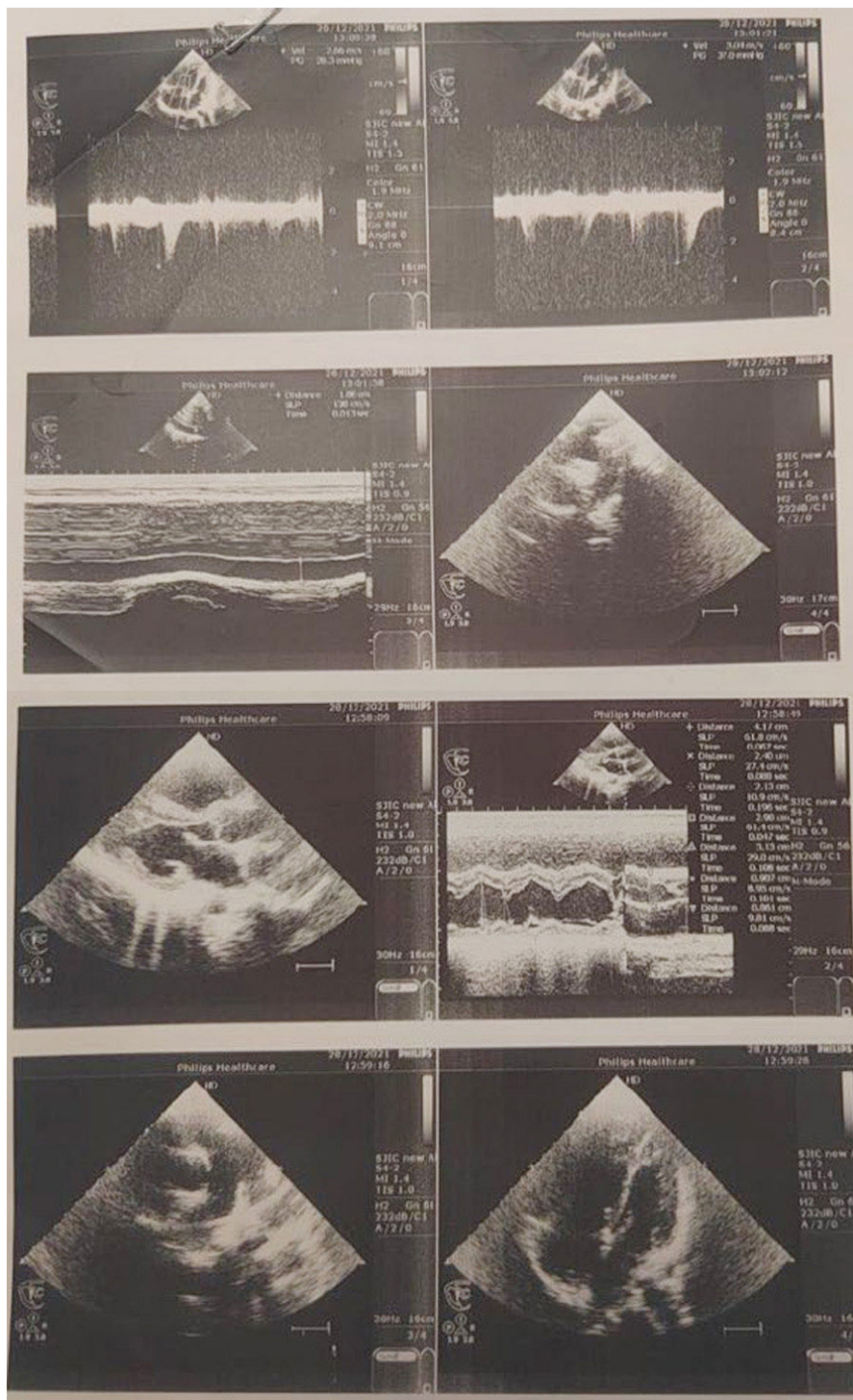


Fig. 2b: 2D-echocardiogram shows dilated Right Atrium (RA) and right ventricle (RV), mildly dilated pulmonary artery (PA), Mild regional wall motion abnormality (RWMA), Mild mitral regurgitation (MR), Mild tricuspid regurgitation (TR), Mild aortic regurgitation (AR), mildly dilated inferior vena cava (IVC), RV dysfunction, PAPVC+, left ventricular ejection fraction (LVEF): 60%

(Reproduced with the permission of the patient)

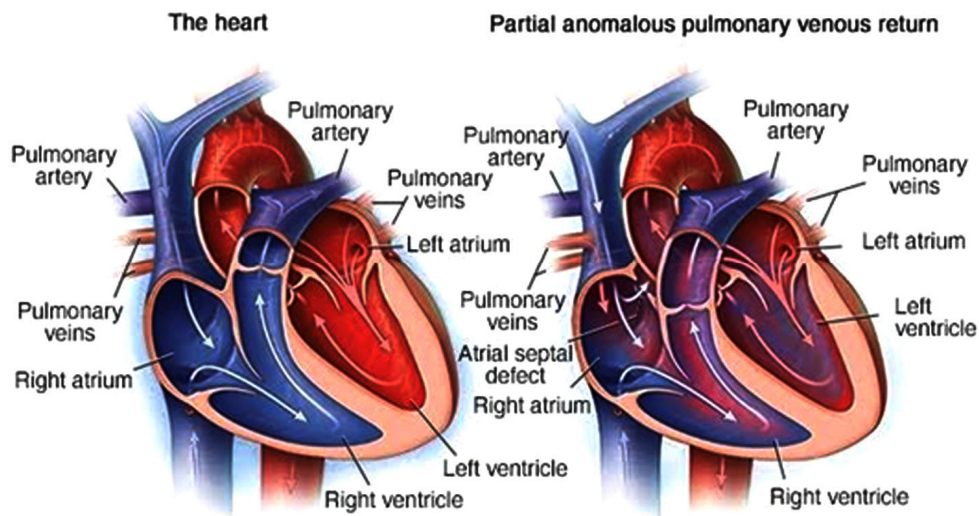


Fig. 3: Comparison of anatomy of normal heart and anatomy of partial anomalous venous connection. (Taken from: Mayo foundation for medical education and research)

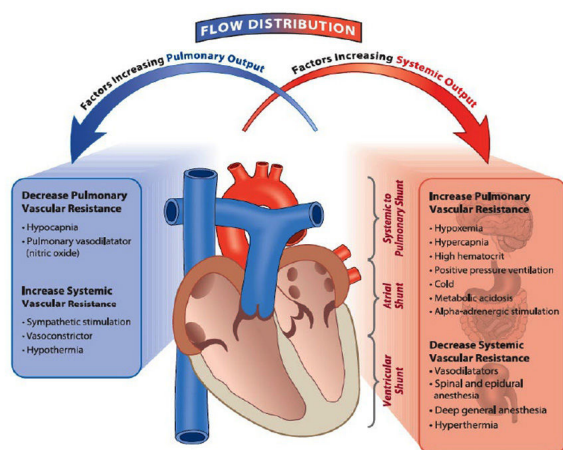


Fig. 4: Factors affecting pulmonary and systemic output of the heart

(Taken from: Cannesson, M. et al. (2009) 'Anesthesia for noncardiac surgery in adults with congenital heart disease', *Anesthesiology*, 111(2), pp. 432-440. doi:10.1097/aln.0b013e3181ae51a6.)

Thus, considering all of her clinical examination findings and radiological evidence, the patient was diagnosed with PAPVC. She was initiated with Furosemide 1 mg/hr infusion as per the orders of the cardiologist. Throughout her course stay in the ICU, peripheral cyanosis was observed and her SaO₂ maintained around 65-70% despite high flow mask (humidified) support. The patient was initiated on Tablet Metoprolol succinate 25 mg OD; advised to continue till further orders and Injection enoxaparin sodium 60 mg/0.6 ml for deep vein thrombosis prophylaxis. She too was counseled regarding regular cardiology follow-up for further management along with the need for family planning concerning her condition.

DISCUSSION

Congenital heart defects are the most common group of birth defects, occurring in live births. The majority of untreated patients born with congenital heart disease die in infancy or childhood, and only 15-25% survive into adulthood. Advances in prenatal diagnosis, interventional cardiology, pediatric cardiac surgery, anesthesia, and critical care have resulted in the survival of approximately 90% of these children to adulthood. Anomalous pulmonary venous connection is a rare congenital heart disease, involving the complete drainage of blood from pulmonary veins into the right side of the heart. Depending on the site of drainage of pulmonary veins (PV), it is classified into total and partial anomalous venous connection. Partial anomalous pulmonary venous connection (PAPVC) is often regarded as a potentially disastrous form of congenital heart disease where most of the pulmonary blood flows to the systemic venous circulation rather than the left atrium.³

The amount of shunting of blood through ASD in partial anomalous pulmonary venous circulation is determined by the ratio of systemic vascular resistance (SVR) to pulmonary vascular resistance (PVR). As SVR is increased, right-to-left shunting decreases.² To a smaller extent change in PVR will also have a reciprocal relationship on the pulmonary blood flow, although the primary factor governing pulmonary blood flow is the presence of infundibular or valvular pulmonary stenosis. The greatest perioperative concern is the

development of cyanotic spells due to spasms of the hypertrophied pulmonary infundibulum. Both, tachycardia and increased myocardial contractility can lead to infundibular spasm. Another mechanism for such hypercyanotic episodes is decreased SVR increasing right to left shunting through VSD. Systemic blood pressure less than 60 mmHg can trigger hypercyanotic episodes.

The presentation of PAPVC is highly variable and depends upon the type of PAPVC, presence or absence of obstruction, age of the patient, hemodynamic response to therapy, level of desaturation, and component of PAH.^{1,5} Accordingly, the anesthetic and hemodynamic goals are also variable. Regardless of the specific anesthetic technique, the hemodynamic goals are to maintain the cardiac output (CO) and to minimize pulmonary edema and PAH.³ Perioperatively, continuous attention should be given to oxygenation, ventilation, acidosis, volume status, and anesthetic depth to avoid further exacerbation of PVR, as the RV may also struggle to maintain cardiac output in the face of elevated pulmonary artery pressures.^{2,3}

Hence, notably pregnant PAPVC patients are anticipated to have surmounted maternal and fetal risk.⁴ The complications associated with pregnancy majorly depend on the underlying maternal cardiac disease causing cyanosis. These patients, especially those with raised pulmonary artery pressure, are more prone to succumb to heart failure. As chronic cyanosis leads to a deranged coagulation profile, bleeding as well and thrombosis, pregnant cyanotic heart disease patients are regarded as high risk.¹ Furthermore, fetal complications including prematurity, low birth weight, abortion, and stillbirths are anticipated and the degree of severity is based on the degree of maternal cyanosis.

There are no evidence-based recommendations to guide the anesthetic management of patients with PAPVC undergoing noncardiac surgery. Given the large scope of abnormalities encompassed, it is also impossible to propose a single approach for anesthetic management that would address every possible defect. However, a major objective of intraoperative management is to promote tissue oxygen delivery by preventing arterial desaturation, maintaining a balance between pulmonary and systemic flows, and by optimizing hematocrit. Survival in TAPVC depends on pulmonary vascular resistance (PVR), size of ASD, and degree of obstruction in PV.

The patient remained asymptomatic due to majorly unobstructed PV.^{2,3,4} Pregnancy can further

complicate PAPVC. These patients already have right-sided volume overload and physiological changes of pregnancy like increased HR, blood volume and cardiac output (CO) predispose them to right-sided heart failure. Uncorrected PAPVC is an indication for termination of pregnancy:

Thus, the primary goals of anesthetic management in the case of PAPVC are directed toward maintaining SVR, reducing PVR, and maintaining mild myocardial depression.¹ As the right ventricular outflow obstruction may worsen in PAPVC patients owing to sympathetic stimulation post-anesthesia induction; the optimal anesthesia plan in these patients should be to maintain/improve the Sao₂ besides maintaining cardiovascular stability.

The Anesthetic Goals in this Patient Specifically were:

1. Preserve the right to left intracardiac shunt
 2. Maintain CO (maintain HR, contractility, preload)
 3. Maintain PVR/SVR ratio
- I. Increase in ratio:** Decreased pulmonary blood flow (PBF) and worsening hypoxemia
- II. Decrease in the ratio:** Increased PBF, pulmonary edema, and decreased CO
4. **De-air IV lines:** Avoid paradoxical air embolism

Subarachnoid block in the form of spinal anesthesia was chosen for this patient since it minimizes SVR changes besides nullifying the cardiac depressant effects of general anesthesia drugs.^{1,4} It is also proven that spinal anesthesia is safe, and provides sufficient anesthesia of perineum/pelvic organs, sensory and motor blockade of lower limbs, allowing early ambulation, voiding, and hospital discharge.

The prognosis for patients with PAPVC can vary depending on the severity of the condition and any associated complications. In general, however, early diagnosis and treatment can improve outcomes and reduce the risk of long-term complications. It is important for patients with PAPVC to receive ongoing medical care and monitoring to manage their condition effectively.^{3,5}

In the post-operative period, patients with PAPVC should be managed preferably if possible in a post-operative intensive care unit experienced with caring for adults with congenital heart disease. The major risks during the post-operative include bleeding, dysrhythmias, and thromboembolic

events. As the patient also has pulmonary hypertension, oral pulmonary vasodilators such as sildenafil and inhaled nitric oxide may be beneficial.³

CONCLUSION

In conclusion, patients with PAPVC with stable hemodynamics can be managed successfully with spinal anesthesia as the mode of anesthesia for surgical procedures. However, managing patients with PAPVC undergoing surgery under spinal anesthesia requires careful consideration of their underlying cardiac condition and close monitoring during the procedure. Anesthesiologists must be aware of potential hemodynamic changes caused by both PAPVC and spinal anesthesia to ensure optimal patient outcomes.

REFERENCES

1. Aravindan A, Pangasa N, Subramaniam R, Sirivella PK. Total anomalous pulmonary venous connection—anesthetic management for incidental surgery in a rare presentation. *Journal of Anaesthesiology Clinical Pharmacology*. 2022; 38(4):672.
2. Datt V, Wadhwa R, Kumar M, Sharma V, Chaudhary R, Virmani S. Perioperative anesthetic management for surgical repair of an adult with Supracardiac total anomalous pulmonary venous communication and pulmonary hypertension: A case report and mini-review. *Journal of Anaesthesia and Critical Care Reports*. 2021;7(3).
3. N Shetty DS. Anesthetic management of a case of partial anomalous pulmonary venous circulation for drainage of brain abscess: A case report. *IOSR Journal of Dental and Medical Sciences*. 2013;11(4):67-70.
4. Ture P, Shaikh S, Hungund S, Roopa S. Anaesthetic management of a rare case of single ventricle heterotaxy syndrome for emergency cesarean section. *Indian Journal of Anaesthesia*. 2015; 59(7):439.
5. Fong J, Druzin M, Gimbel AA, Fisher J. Epidural anesthesia for Labour and. *Canadian Journal of Anaesthesia*. 1990;37(6):680-4.

