

# Anaesthetic Management for Rt Emphysematous Pyelonephritis with Grade I Hydroureteronephrosis with Perinephric Abscess with Left Lobar Pneumonia

Kotlo Rukmini Seshadri<sup>1</sup>, Sinchana Bhagawan<sup>2</sup>, Ravi Madhusudhana<sup>3</sup>, Sujatha M. P.<sup>4</sup>

## How to cite this article:

Kotlo Rukmini Seshadri, Sinchana Bhagawan, Ravi Madhusudana *et al.* Anaesthetic Management for Rt Emphysematous Pyelonephritis with Grade I Hydroureteronephrosis with Perinephric Abscess with Left Lobar Pneumonia. Indian J Anesth Analg. 2024;11(1) 17-21.

## Abstract

**Introduction:** A perinephric abscess is usually a complication of urologic infection which results from fat necrosis. Before the era of antibiotics, perinephric abscesses were due to prolonged bacteremia. More than 3/4 of perinephric abscesses are now due to complications of urinary tract infections.

**Case Report:** We present a 71 year old female case with Right Emphysematous Pyelonephritis

Grade I Hydroureteronephrosis with left perinephric abscess, left lobar pneumonia posted for bilateral DJ stenting with perinephric drain placement under continuous spinal anesthesia. Presented with H/o lower back pain, associated with fever since 3 days and H/o burning micturition, since 6 months. She is known case of Type 2 DM since 23 years and on Inj. Biphasic Insulin, Tablet vildagliptin, Tablet Dapaglifazone, known case of hypothyroidism and on tablet Thyroxin 50 mg OD in morning. H/o stroke 20 years back right side Upper & lower limb affected. H/o previous appendectomy 20 years back, CT-KKUB suggestive of Emphysematous Pyelonephritis, right side with grade I HUN, left perinephric fat with ill diffused hypodense area in upper lobe of left kidney. Non obstructive left renal calculus 4.0mm.

ECG shows RBBB, Saturation was 92% on Roomair, On ABG analysis severe metabolic acidosis found. We planned to administer continuous spinal anesthesia. Patient was explained about the continuous spinal anesthesia & written informed consent was taken. Tablet Alprazolam 0.25 mg, and tablet Rantac, 15 was given previous night and in morning on the day of surgery. Nil per oral is maintained 8 hours before surgery. A 18 Gauge IV cannula was secured, a 5 lead Electrocardiogram, Pulse Oximeter, NIBP and ETCO<sub>2</sub> monitoring was done. Under strict aseptic precautions, L3 L4 space was identified and using 18G tuohy needle, Lumbar puncture is done. Injection Bupivacaine 0.8cc given, block is achieved till T8 level. Surgery was lasted for one and half hour. Vitals were stable. Patient shifted to recovery room and was under observation for an hour, patient was shifted to post operative ward.

**Conclusion:** This is an Original case report, which provide a successful management of anesthesia, of bilateral DJ stenting with perinephric drain placement

**Author's Affiliation:** <sup>1</sup>Postgraduate Resident, <sup>3,4</sup>Professor, Department of Anesthesiology, Sri Devaraj Urs Medical College, SDUAHER, Kolar 563101, Karnataka, India, <sup>2</sup>Consultant, Department of Anaesthesiologist, Brains Hospital, Bangalore 560063, Karnataka, India.

**Corresponding Author:** Ravi Madhusudhana, Professor, Department of Anesthesiology, Sri Devaraj Urs Medical College, SDUAHER, Kolar 563101, Karnataka, India.

E-mail: [ravijaggu@gmail.com](mailto:ravijaggu@gmail.com)

Received on: 03.10.2023

Accepted on: 29.11.2023

under continuous spinal anesthesia. Anesthesia Management for Right Emphysematous Pyelonephritis with grade I HUN. With perinephric abscess with left lobar Pneumonia.

**Keywords:** Emphysematous Pyelonephritis; HUN; Perinephric abscess; Lobar Pneumonia.

**Key Messages:** Elderly patients have increased risk for peri operative mortality and morbidity due to additional comorbidities such as heart diseases, lung pathologies, continuous spinal anaesthesia is preferred due to advantages such as maintenance of cardiovascular system, this case presents anaesthetic approach with continuous spinal anesthesia with low dose hyperbaric bupivacaine, provided safe and efficient blockade during the surgery with minimal hemodynamic changes.

## INTRODUCTION

Perirenal fat necrosis leads to perinephric abscess. A perinephric abscess frequently develops as a side effect of urologic infection. Before the invention of antibiotics, chronic bacteremia with *Staphylococcus aureus* and hematogenous seeding were the main causes of perirenal abscesses.<sup>1</sup> Currently, complications from a urinary tract infection account for more than 75% of perinephric abscesses. A perinephric abscess is more widespread and impacts Gerota's fascia and the renal capsule.

The most common causes of perinephric abscesses are polymicrobial infections or gram negative enteric bacilli. *Escherichia coli*, *Staphylococcus aureus*, and *Klebsiella pneumoniae* are the most typical pathogens. A majority (51.4%) of perinephric abscesses are caused by *Escherichia coli*. *Staphylococcus aureus* perinephric abscesses are often brought on by hematogenous seeding of infection.<sup>2</sup>

DJ stenting is a common procedure for obstructive uropathies, the anesthetic management of this case was challenging because of complications such as low saturation, (left lobar Pneumonia) right bundle branch block, we report successful anesthetic management of case posted for Double J stenting with perinephric drain Placement.

## CASE REPORT

A 71 year old female case of right emphysematous pyelonephritis with Grade I HUN with left perinephric abscess with left lobar pneumonia, posted for bilateral DJ stenting with perinephric

drain placement, came with H/o lower back pain, associated with fever since 3 days and H/o burning micturition, since 6 months. She is known case of Type 2 DM since 23 years and on Inj. Biphasic Insulin, Tablet vildagliptin, Tablet Dapaglifazone, known case of hypothyroidism and on tablet Thyroxin 50 mg OD in morning. H/o stroke 20 years back right side Upper & lower limb affected. H/o previous appendectomy 20 years back,

CT-KKUB suggestive of Emphysematous Pyelonephritis, right side with grade I HUN, left perinephric fat with ill diffused hypodense area in upper lobe of left kidney. Non obstructive left renal calculus 4.0mm. ECG shows RBBB, Saturation was 92% on Roomair, On ABG analysis severe metabolic acidosis found. After discussing with Urology team, we planned to administer continuous spinal anesthesia. Patient was explained about the continuous spinal anesthesia & written informed consent was taken. Tablet Alprazolam 0.25 mg, and tablet Rantac, 150 mg was given previous night and in morning on the day of surgery. Nil per oral is maintained 8 hours before surgery. The plan was to take under continuous Spinal anesthesia. A 18 Gauge IV cannula was secured, a 5 lead Electrocardiogram, Pulse Oximeter, NIBP and ETCO<sub>2</sub> monitoring was done.

Under strict aseptic precautions, parts were painted and draped, L3, L4 space was identified using anatomical landmark technique and using 18G tuohy needle, Lumbar puncture is done. After confirming free backflow of CSF, drug is injected via catheter after negative aspiration, Injection Bupivacaine 0.8cc given, block is achieved till T8 level. Surgery was lasted for one and half hour. Vitals were stable. Patient shifted to recovery room and was under observation for an hour, patient was shifted to post operative ward.

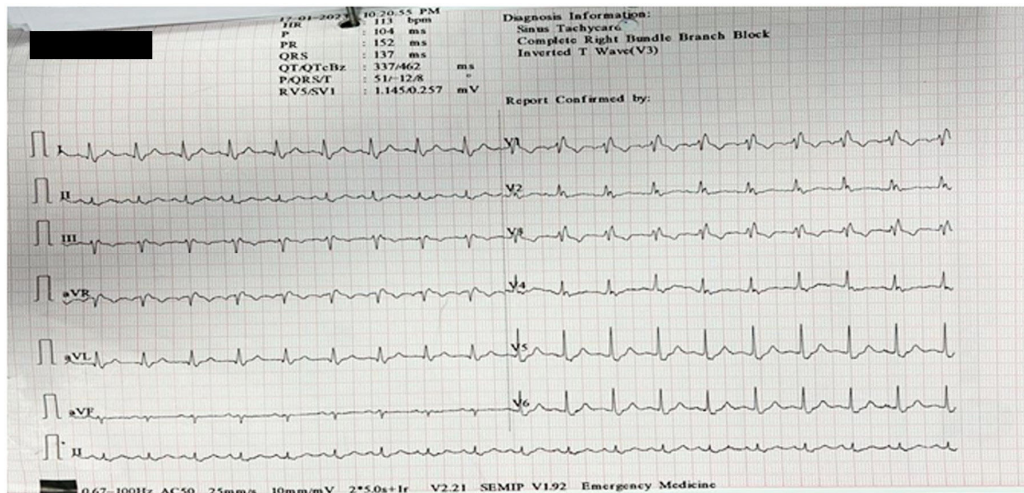


Fig. 1: ECG showing RBBB

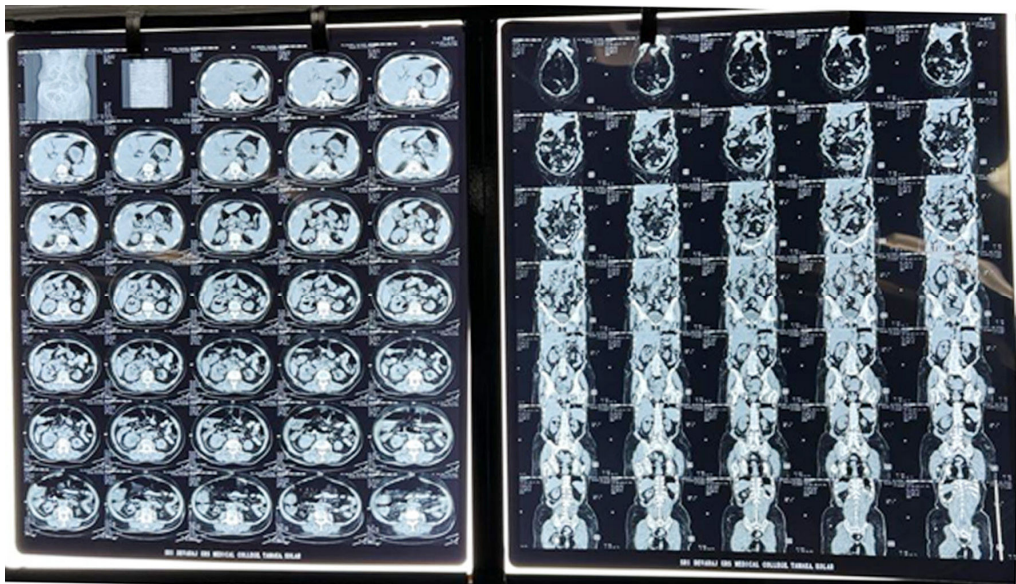


Fig. 2: CT Showing the Perinephric Abscess and Lobar Pneumonia

## DISCUSSION

A similar urologic infection may spread locally or hematogenously from a centre beyond the kidney, resulting in a perinephric abscess. These abscesses are typically brought on by pyelonephritis and an ascending infection from the urine bladder. With local spread, the kidney infection migrates outside into the perirenal fat. It might potentially be the outcome of a staphylococcus-related renal abscess of the cortex that burst through the capsule. It is possible for non-renal contiguous infections to cause perinephric abscesses. These infections can result from trauma, be an extension of an infection in the liver, cervix, pancreas, gallbladder,

or appendix, or they can be caused by small bowel Crohn's disease or spinal osteomyelitis.<sup>3</sup>

Diabetes mellitus, pregnancy, urinary tract infection, and anatomical abnormalities are all risk factors for perinephric abscess. Nephrolithiasis, including big staghorn stones, neurogenic bladder, vesicoureteral reflux, obstructive tumour, papillary necrosis, and polycystic kidney disease are among the disorders of the urinary system. Perinephric abscess patients typically appear with non-specific symptoms. Patients frequently exhibit an insidious onset of tiredness, flank discomfort, and fever. With the spread of the illness, they may refer discomfort to the leg or groin area. Many people with perinephric abscesses typically do not exhibit symptoms like dysuria and frequent urination that are typical of



urinary tract infections.<sup>4</sup> Patients who are elderly or who have autonomic neuropathy, or who have diabetes or a history of persistent drinking, have more passive symptoms. Patients may also have chest discomfort when a lung extension and concomitant empyema are present, as well as right upper quadrant pain from a perinephric abscess that has spread to the liver.<sup>5</sup>

Leukocytosis and underlying kidney function can be evaluated with routine blood testing, which includes a chemical panel and complete blood count (CBC). Proteinuria and pyuria are detected by urine testing. In cases of perinephric abscess, urine testing may be normal because the abscess may not be in contact with the collecting system. Since there is no connection with the collecting system in a patient who develops a perinephric abscess from hematogenous seeding, the urine analysis is also normal. Due to hematogenous seeding of infection, blood cultures in patients with perinephric abscess may develop bacterial pathogens. Leukocytosis is a rather general indicator. Acidosis may also be seen at first in diabetics. C-reactive protein (CRP) and erythrocyte sedimentation rate (ESR), two inflammatory indicators, are usually increased.<sup>6</sup>

Different radiographic imaging techniques can be used to visualise abnormalities, but computed tomography (CT) with contrast enhancement is the recommended imaging modality. A perinephric abscess may be suggested by abnormalities that appear on plain radiography. The lack of the psoas margin, the presence of an abdominal mass, an enlarged kidney with poorly defined boundaries, a radio-opaque stone, and a poorly defined kidney shadow are among these radiological anomalies. When there is a horizontal gap between the urine (low density) and pus on ultrasound, it is indicative of abscess suppuration (more dense fluid). The best method for locating perinephric abscesses is computed tomography (CT) with contrast since it can both locate and quantify the abscess. Additionally, perinephric suppuration to nearby tissues such the liver, mediastinum, and diaphragm can be evaluated using enhanced CT.<sup>7</sup>

Antimicrobial medications combined with PCD are advised as the first line of therapy for a big perinephric abscess (>3 cm), as the abscess may spread to other nearby retroperitoneal organs as well as the perinephric space. However, surgical procedures should be seriously considered if medicinal treatment is ineffective for treating the abscess. Despite the fact that perinephric drains are often utilised following all types of renal procedures, there isn't enough proof to suggest

that they have any effect on the development of urinomas or infections. Since 1967, ureteric stents a kind of internal stent have been used for internal drainage. In general, ureteral stenting is indicated as a pre or post-operative adjuvant to ureteral surgery as well as to treat either intrinsic or extrinsic ureteral blockage.<sup>8</sup>

## CONCLUSION

Pyelonephritis complications or hematogenous infection spread are two conditions that might lead to a perinephric abscess. Diffuse liquefaction between the Gerota's fascia and renal capsule is typically an abscess. Non-specific signs and symptoms include fever, flank discomfort, and occasionally dysuria. Proteinuria and pyuria may also be detected in tests. ESR and CRP are common examples of inflammatory indicators that are high. This is an Original case report, which provide a successful management of anesthesia, of bilateral DJ stenting with perinephric drain placement under continuous spinal anesthesia. Anesthesia Management for Right Emphysematous Pyelonephritis with grade I HUN. With perinephric abscess with left lobar Pneumonia.

*Conflict of Interest:* None

## REFERENCES

1. Lee BE, Seol HY, Kim TK, Seong EY, Song SH, Lee DW, Lee SB, Kwak IS. Recent clinical overview of renal and perirenal abscesses in 56 consecutive cases. *Korean J Intern Med.* 2008; 23:140-8.
2. Liu XQ, Wang CC, Liu YB, Liu K. Renal and perinephric abscesses in West China Hospital: 10-year retrospective-descriptive study. *World J Nephrol.* 2016 06;5(1):108-14.
3. Chika N. Okafor; Elizabeth E. Onyeaso. Perinephric abscess. NCBI Bookshelf. A service of the National Library of Medicine, National Institutes of Health. StatPearls [Internet]. Treasure Island (FL): Stat Pearls Publishing; 2022.
4. Coelho RF, Schneider-Monteiro ED, Mesquita JL, Mazzucchi E, Marmo Lucon A, Srougi M. Renal and perinephric abscesses: analysis of 65 consecutive cases. *World J Surg.* 2007; 31(2):431-6.
5. Tsukagoshi D, Dinkovski B, Dasan S, Jethwa J. Perinephric abscess secondary to a staghorn calculus presenting as a subcutaneous abscess. *CJEM.* 2006; 8(4):285-8.
6. Hutchison FN, Kaysen GA. Perinephric abscess: the missed diagnosis. *Med Clin North Am.* 1988;

- 72(5):993-1014.
7. Lee IH, Shin HS, Ahn DJ. A forgotten double-J ureteral stent resulting in an emphysematous perinephric abscess: A case report. *Medicine (Baltimore)*. 2022;101(25):e29418. Published 2022
  8. Banale K, Rana KS, Panchabhai SV, Srihari S, Calcuttawallah M, Nagare K. Role of perinephric drain in the era of internal drainage (DJ stent) in open renal surgery. *Med J DY Patil Univ* 2014; 7:29-32.

