

# Role of Low Level Laser Therapy in Pediatric Burn Wound

Karavadi Anuradha<sup>1</sup>, Ravi Kumar Chittoria<sup>2</sup>, Amrutha<sup>3</sup>

## How to cite this article:

Karavadi Anuradha, Ravi Kumar Chittoria, Amrutha. Role of Low Level Laser Therapy in Paediatric Burn Wound. *Pediatr. Edu. Res.* 2023;11(3): 95-98.

## Abstract

Burn is defined as a traumatic injury of thermal origin, which affects the organic tissue. Low-level laser therapy (LLLT) has gained great prominence as a treatment in this type of injury. The aim of this case report is to assess the role of Low level laser therapy in healing of wounds in burn wounds in paediatric burns patients. Normal wound healing takes around 3 weeks with epithelisation at 1mm/day. The advanced wound healing therapies help in expediting the advancement of epithelial edge of the wound.

**Keywords:** LLLT; Paediatric burns; Wound healing.

## INTRODUCTION

Burns injury is one of the important factors contributing to mortality in a developing country like India. Aim of this case report is to assess the role of Low level laser therapy in healing of wounds in burn wounds in paediatric burns patients. A delay in burn wound healing increases patients' pain and discomfort, the rate of infection all of which can be reduced to a certain extent by the use of LLLT. Clinical examination of the wound and donor site before and after the use of Low level

laser therapy was done. The normal pace of wound healing and epithelialization is at the rate of 1mm/day. Optimum recovery requires the wound bed and the patient to be fit. The advanced wound healing therapies like LLLT aim to hasten the process of wound healing by expediting the epithelization in wounds<sup>3</sup>. Many newer techniques have been used to improve the epithelializations such as LLLT.

## MATERIALS AND METHODS

The study is done in a tertiary care hospital in South India. The subject is a 4 year old female patient, with no known comorbidities, the patient has alleged history of accidental scald burns on left hand and forearm while she accidentally dipped her hand on hot boiled water (Fig. 1). Patient sustained second degree deep and superficial burns on left hand and distal half of forearm, circumferential, capillary refill time <3. Admitted in Burns ICU, managed with antibiotics, IV Fluids, analgesics. Dermabrasion assisted early serial excision, regenerative scaffold, LLLT (Fig.

---

**Author's Affiliation:** <sup>1</sup>Junior Resident, Department of General Surgery, <sup>2</sup>Professor, <sup>3</sup>Senior Resident, Department of Plastic Surgery, Jawaharlal Institute of Postgraduate Medical Education and Research, Pondicherry 605006, India.

**Corresponding Author:** Ravi Kumar Chittoria, Professor, Department of Plastic Surgery, Jawaharlal Institute of Postgraduate Medical Education and Research, Pondicherry 605006, India.

**E-mail:** drchittoria@yahoo.com

**Received on:** 17.01.2024

**Accepted on:** 22.02.2024

2), cyclical Negative Pressure Wound Therapy (NPWT) done. Split Skin Grafting (SSG) of the raw area done (Fig. 3). LLLT was done 4 times following which the patient wound improved well (Fig. 4).

Currently the general condition of the patient is fair.

## RESULTS

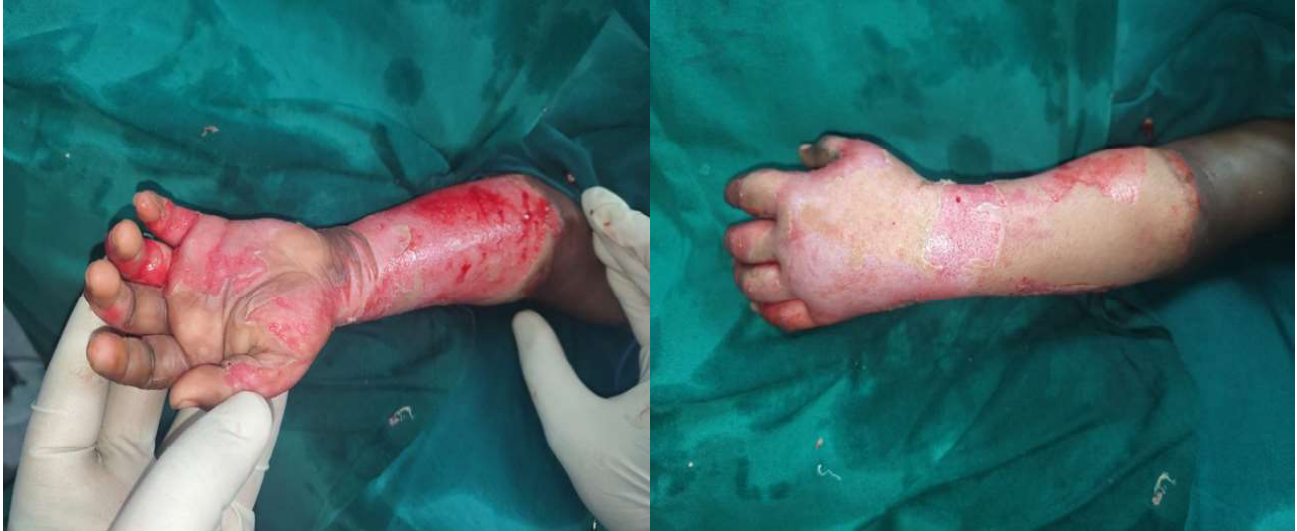

Fig. 1: Second-degree burns at the time of admission

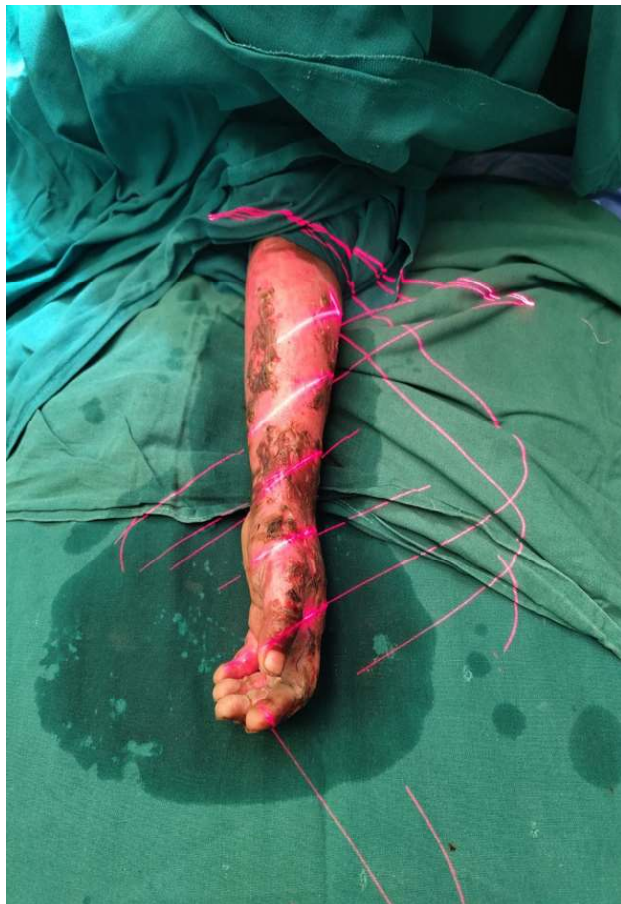

Fig. 2: Low level laser therapy after serial debridement

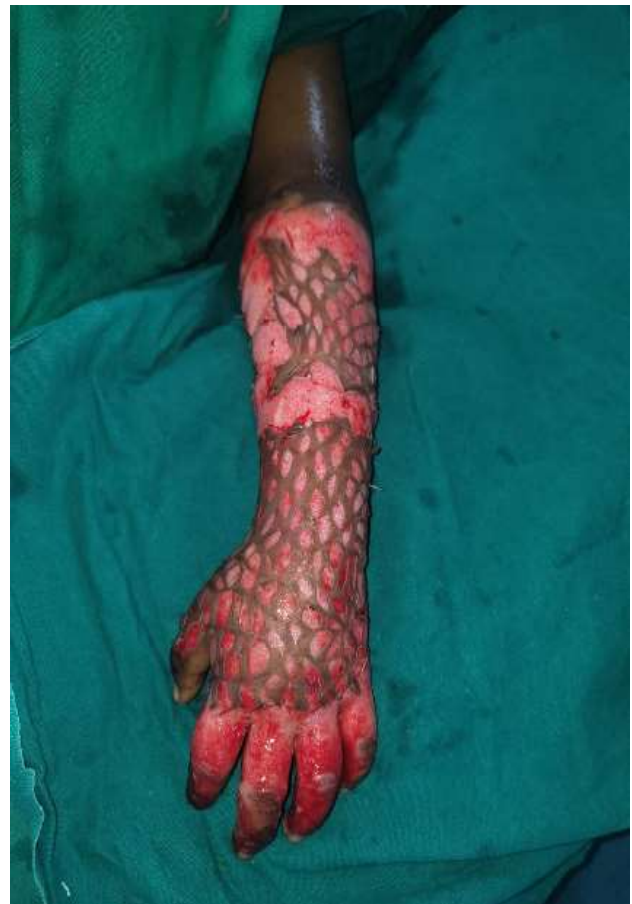

Fig. 3: Split skin grafting

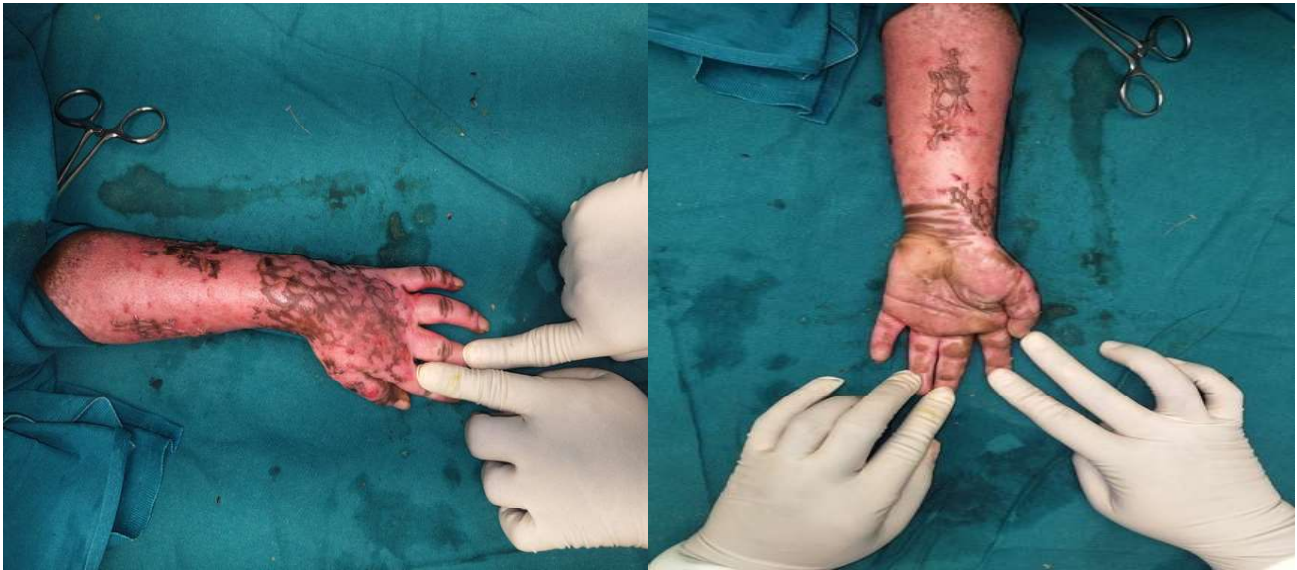


Fig. 4: Healed wound after four sessions of Low-level laser therapy

By the above observations, LLLT is useful in improving the wound healing of burns in this patient as evident in the post procedure findings. (Fig. 4)

## DISCUSSION

Low level laser therapy is generated from G-As (gallium-arsenide) laser. LLLT acts by photobiomodulation. It has effect on cell proliferation, metabolism, angiogenesis, apoptosis and inflammation. Effective LLLT utilises wavelength of red to near infrared (600-1070 nm).<sup>1</sup> Low-level laser therapy (LLLT) has gained great prominence as a treatment in this type of injury.<sup>4</sup> LLLT acts on cytochrome oxidase, promotes nuclear factor kappa b which promotes cell proliferation and anti-apoptotic action. It also upregulates VEGF<sup>5</sup> which promotes angiogenesis.<sup>7,8</sup> At cellular level it acts on mitochondria and photoreceptors located in cell membranes, releasing a cascade of events that leads to the bio stimulation of various cellular processes.<sup>4</sup> Low level laser is applied by scanning mode and adjusted to cover the region of the wound. Application is for 5-10 minutes per weekly session. It has a stimulatory effect on raw areas and wounds by improving granulation. LLLT has been shown to reduce the thickness of hypertrophic scars which was studied by comparing the skin thickness pre and post application.<sup>6</sup> It softens scars by reducing fibrous tissue formation, improves blood supply and promotes nerve regeneration. It has an anti-inflammatory action, the mechanism of which is not clearly elucidated. LLLT was being used in maxillofacial surgeries and oral mucositis after head and neck surgeries and its usefulness in

plastic surgery must be similarly explored using high-quality human clinical studies,<sup>5</sup> as so far role of LLLT in animal studies is available but studies on humans are lacking.

## CONCLUSION

LLLT helped in Wound Bed Preparation (WBP), and take of skin grafting. Hence improved overall healing of burns wounds.

## REFERENCES

1. Karu T. Photobiological fundamentals of low power laser therapy. *IEEE J Quantum Electron* 1987;QE23(10):1703.
2. Molecular mechanism of the therapeutic effect of low intensity laser irradiation.
3. Mester E, Spiry T, Szende B, Tota JG. Effects of laser rays on wound healing. *Am J Surg* 1971;122:532-5 Brassolatti, P., de Andrade, A. L. M., Bossini, P. S., Otterço, A. N., & Parizotto, N. A. (2018).
4. Evaluation of the low-level laser therapy application parameters for skin burn treatment in experimental model: a systematic review. *Lasers in Medical Science*, 33(5), 1159-1169.
5. Hersant, B., SidAhmed-Mezi, M., Bosc, R., & Meningaud, J. P. (2015). Current Indications of Low-Level Laser Therapy in Plastic Surgery: A Review. *Photomedicine and Laser Surgery*, 33(5), 283-297.
6. Alsharnoubi, J., Shoukry, K. E.-S., Fawzy, M. W., & Mohamed, O. (2018). Evaluation of scars

- in children after treatment with low-level laser. *Lasers in Medical Science*.
7. Andrade FSSD, Clark RMO, Ferreira ML. Effects of low-level laser therapy on wound healing. *Rev Col Bras Cir. [periódica Internet]* 2014;41(2).
  8. Vaghardoost, R., Momeni, M., Kazemikhoo, N., Mokmeli, S., Dahmardehei, M., Ansari, F, Sassani, S. (2018). Effect of low-level laser therapy on the healing process of donor site in patients with grade 3 burn ulcer after skin graft surgery (a randomized clinical trial). *Lasers in Medical Science*, 33(3), 603-607.
  9. Renno, A. C. M., Iwama, A. M., Shima, P., Fernandes, K. R., Carvalho, J. G., De Oliveira, P., & Ribeiro, D. A. (2011). Effect of low-level laser therapy (660 nm) on the healing of second-degree skin burns in rats. *Journal of Cosmetic and Laser Therapy*, 13(5), 237-242.
  10. Schindl A, Schindl M, Pernerstorfer-Schön H, Schindl L. Low-intensity laser therapy: a review. *J Investig Med*. 2000 Sep;48(5):312-26.
- 
-