

Extra-Nasopharyngeal Angiofibroma of the Hard Palate: An Uncommon Case Reported in an Adult Female

Ishita Singhal¹, Mamidi Sankar², Sumit Majumdar³, Smyrna Ogirala⁴

How to cite this article:

Ishita Singhal, Mamidi Sankar, Sumit Majumdar, *et al.* Extra-Nasopharyngeal Angiofibroma of the Hard Palate: An Uncommon Case Reported in an Adult Female. Indian J Dent Educ. 2024;17(1):45-48.

Abstract

Angiofibromas, accounting for a mere 0.05-0.5% of all head and neck neoplasms, are uncommon benign tumors originating from connective tissue and characterized by a high vascularity and local aggressiveness. Juvenile Nasopharyngeal Angiofibroma, extensively discussed in medical literature, represents the most common subtype and is typically found in the nasopharynx. Extra-nasopharyngeal angiofibromas, which occur in locations outside the nasopharynx, are quite rare, with the maxillary sinus being the most typical site according to existing research. This paper presents a unique case of Extra-nasopharyngeal Angiofibroma affecting the hard palate in an adult female. This case is noteworthy due to the tumor's anterior hard palate location, its occurrence in a female patient, and its clinical resemblance to a fibroma, making it the first reported case of its kind.

Keywords: Angiofibroma; Benign Neoplasms; Hard Palate; Tumor.

INTRODUCTION

Juvenile Angiofibromas (JAs), also referred to as Juvenile Nasopharyngeal Angiofibromas

(JNA) or Pterygopalatine Angiofibromas, represent rare benign tumors originating from connective tissue, as indicated by histological findings.^{1,2} The nomenclature is assigned based on the tumor's clinical location. However, JAs occasionally manifest in regions beyond the nasopharynx, including the maxillary sinus area, nasal and paranasal cavities, palatal region, or the mandibular region, and are thus classified as Extra-Nasopharyngeal Angiofibromas (ENA). In the spectrum of head and neck neoplasms, Nasopharyngeal Angiofibromas account for a mere 0.05-0.5%.³

These tumors pose a significant clinical challenge due to their capacity to invade adjacent tissues, the skull's base, and the potential for extension into critical structures such as the cavernous sinus and optic chiasma, rendering them potentially life-threatening.² Therefore, a heightened level of suspicion is imperative to ensure timely diagnosis

Author's Affiliation: ¹Ph.D. Student, Department of Biomedical, Surgical & Dental Sciences, Università Degli Studi di Milano, Milan, Italy, ²MDS, Department of Oral Pathology & Microbiology and Forensic Odontology, Ex-Resident Department of Oral Pathology & Microbiology and Forensic Odontology, ³Professor, Department of Oral Pathology & Microbiology and Forensic Odontology, GITAM Dental College & Hospital, Vishakhapatnam 530045, Andhra Pradesh, India.

Corresponding Author: Ishita Singhal, Ph.D. Student, Department of Biomedical, Surgical & Dental Sciences, Università Degli Studi di Milano, Milan, Italy.

E-mail: drishita21@gmail.com

Received on: 20.10.2023

Accepted on: 29.11.2023

and effective management of such lesions.

This publication provides a detailed account of an unusual case of ENA that developed on the maxillary hard palatal surface in an adult female. The clinical presentation of this lesion bore a striking resemblance to a fibroma, making it a rare occurrence. In this article, we present a comprehensive analysis of the clinical, radiological, and histological features of this unique case, shedding light on the diagnostic challenges and potential treatment strategies associated with ENA.

CASE HISTORY

A 38-year-old female reported to the Dental Outpatient Department with a chief complaint of pain and swelling in the upper left front and back tooth region of the jaw for the past 6 months. The pain was intermittent, dull aching, and mild in intensity. Initially, the patient noticed a small swelling on the hard palate, which slowly progressed to its present size. Her past medical or dental history was non-contributory. The patient had no history of trauma. The patient did not complain of headache, nasal obstruction, or epistaxis, but had difficulty chewing.

Extraoral examination revealed no asymmetry or swelling. Lymph nodes were non-palpable. On intraoral examination, a large solitary mass measuring 4.0x2.5x1.0cm (approx.) in size was seen on the left anterior hard palate extending from tooth 21 mesially to 26 distally with normal overlying mucosa and blanching at a few areas over the lesion. The mass was sessile and presented palatally to the teeth with a smooth surface. On

palpation, the swelling was tender and soft to firm in consistency (Fig. 1a). The other head and neck findings were unremarkable. Based on the foregoing clinical signs, a preliminary diagnosis of a benign non-odontogenic tumor such as mucoepidermoid carcinoma, pleomorphic adenoma, lipoma, or fibroma was established, and a mucous retention cyst, a minor salivary gland tumor, or a palatal abscess or a schwannoma was also evaluated according to their areas of occurrence.

Hematological investigations were within normal limits. On radiographic examination, the Magnetic Resonance Imaging (MRI) scan revealed a well-defined 4x3cm isointense mass with T1-weighted images in the hard palate extending from the 21 to 26 regions. The mass obliterated the mid-palatine raphe (Fig. 1b). Postcontrast, the lesion showed intense heterogeneous enhancements. The lesion did not extend into the nasal cavity or maxillary sinus.

The patient underwent an excisional biopsy under local anesthesia. The surgical specimens were fixed in a 10% neutral buffered formalin solution. On gross examination, two tissues measuring 2 cm x 0.7 cm in size, soft to firm in consistency, and reddish-pink to tan-grey in color were received (Fig. 1c). On histopathological examination, hematoxylin and eosin stained soft tissue sections showed fibro-cellular connective tissue stroma. At a higher magnification, the connective tissue stroma exhibited numerous vascular channels of varying shapes and sizes lined by a single layer of endothelium intricately mixed with fibrous stroma surrounded by spindle cells. The collagen fibers were haphazardly interspersed with plump

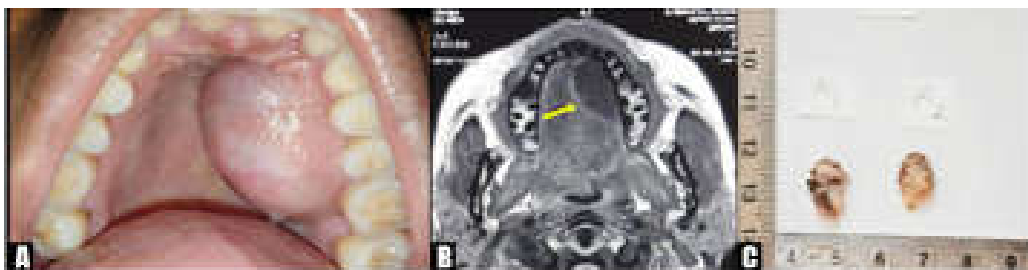


Fig. 1: (a) Intraorally, a large, sessile, solitary mass with a smooth surface was seen on the hard palate extending from tooth 21 to 26 with normal overlying mucosa. (b) MRI scan exhibited a well-defined isointense mass with T1-weighted images in the hard palate extending from the 21 to 26 region. The mass obliterated the mid-palatine raphe (yellow arrow). (c) On gross examination, two tissues measuring 2x0.7cm in size, soft to firm in consistency, and reddish-pink to tan-grey in color were received.

and stellate cells. Hyalinization can be observed in vascular channels in a few areas.

The neoplasm did not show a marginal demarcation (Fig. 2a-c). Based on clinical,

radiological, and histological characteristics, a final diagnosis of Extra-nasopharyngeal Angiofibroma (ENA) of the hard palate was made. The patient was followed up for 6 weeks and reported no

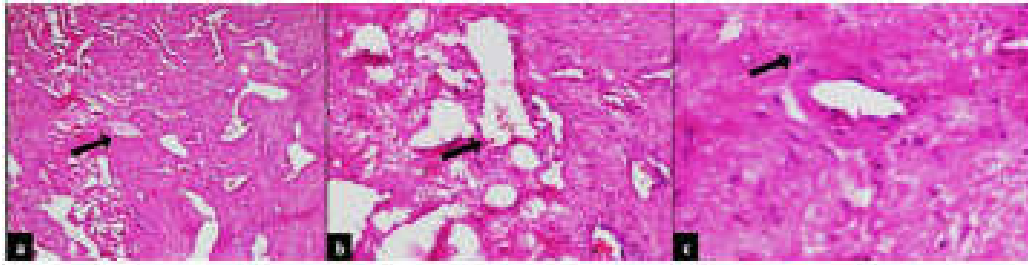


Fig. 2: (a) In a few areas, hyalinization could be observed in the vascular channels (black arrow, H & E, 4×). (b) The connective tissue stroma exhibited numerous vascular channels in varying shapes and sizes lined by a single layer of endothelium intricately admixed with fibrous stroma surrounded by spindle cells (black arrow, H & E, 10×). (c) The collagen fibers were interspersed with plump, stellate cells haphazardly (black arrow, H & E, 40×).

recurrence or untoward incidents.

DISCUSSION

In the 4th century BC, Hippocrates is credited with the earliest recorded writings on Juvenile Nasopharyngeal Angiofibroma (JNA). It was not until 1906, when Chaveau introduced the term, that renewed interest in JNA was sparked. The first documented case of JNA in a female patient was reported by Shaheen *et al.* in 1930.³ Extra-nasopharyngeal angiofibroma (ENA) represents a subtype of angiofibroma originating outside the Nasopharynx or Pterygopalatine region. Studies, such as De Vincentiis & Pinelli's research in 1980, reveal that out of 704 cases of angiofibroma studied, only 13 had origins beyond the nasopharynx, emphasizing ENA as a distinct but uncommon condition. In 2004, Windfuhr JP & Remmert S reported 65 cases of ENA. Celik B *et al* proposed reserving the term "Atypical Angiofibroma" for such neoplasms.⁴

Clinically, ENA is characterized as a large, benign, highly vascular, and locally aggressive tumor, with an average size of 5.9 cm in one study. This tumor is predominantly found in males in their third decade.^{3,4} The symptoms of ENA can vary depending on their location. In intra-oral presentations, they may appear sessile or pedunculated, reddish pink, or similar to the surrounding mucosa. These lesions are typically firm in consistency and may exhibit ulcerated surfaces. ENAs have been recorded in various areas, including the maxillary sinus, paranasal sinuses, nasal cavity, buccal and infratemporal space, mandible, and lips.³⁻⁶ Despite their rarity, comprising less than 0.05% of all head and neck tumors, ENAs are of great clinical interest due to their propensity to cause profuse bleeding. The etiology of these tumors is linked to the expression of

male sex hormones (androgens and progesterone), genetic factors, molecular alterations, or human papillomavirus infection.³ These lesions can mimic both benign and malignant soft tissue tumors in the oral cavity. The case presented here is unique in terms of the patient's age, sex, lesion location, and clinical appearance, which closely resembled a fibroma, setting it apart from conventional Angiofibromas.

The diagnosis of ENAs typically involves radiological examination and biopsy. These tumors are clearly visible in Computer Tomography scans, Magnetic Resonance Imaging scans, and angiographies. However, hypervascularity does not exclude ENA when arteriography is utilized.⁵ Microscopic examination employs Hematoxylin eosin staining and immunohistochemistry to confirm the histopathological characteristics of these lesions.⁴ Grossly, ENA typically presents as lobulated reddish-blue tumors with a firm to spongy consistency, occasionally exhibiting cystic areas and a hemorrhagic cut surface. They are characterized by fibroblast rich, highly vascularized tissue with a thick collagen matrix. Thin walled, irregular blood vessels are evenly dispersed within the loose fibro-collagenous matrix, often showing signs of thrombosis or hyalinization. The stromal fibroblasts are typically bland with stellate cytoplasmic extensions, fine chromatin, and plump oval nuclei. Immunohistochemistry reveals reactivity to androgen and estrogen receptors, as well as the expression of transforming growth factor beta-1, basic fibroblast growth factor, and vascular endothelial growth factor receptor 2.³ APC and beta-catenin alterations, along with the influence of testosterone, may accompany this lesion's development.¹⁰ Aneuploidy is notably absent in ENA, as chromosomal gains are proposed to activate oncogenes without concomitant loss of tumor suppressor genes. Inconspicuous endothelium, fragile thin walled blood vessels, and

a prominent fibrous stroma collectively contribute to the diagnosis and distinguish ENA from similarly appearing lesions.⁸⁻¹¹

ENA can be effectively managed through surgery and antiandrogen medication. Additional treatment modalities include embolization, cryotherapy, vascular ligation, or chemotherapy for select patients. Radiation therapy, once employed, is now avoided due to the risk of post-radiation sarcoma development.⁶⁻⁹ The recurrence rate has been reported by various authors to range from 21% to 44%.¹¹

CONCLUSION

Irrespective of age, gender, geographic origin, or tumor size, our findings support the assertion that ENA should be recognized as a distinct medical condition and retained within the list of potential diagnoses for benign soft tissue tumors. Given the limited number of documented cases in existing literature, it is imperative to gather more expertise on this rare tumor to establish a comprehensive profile and standardized diagnostic and treatment protocols.

Abbreviations:

JA: Juvenile Angiofibromas

JNA: Juvenile Nasopharyngeal Angiofibroma

ENA: Extra-Nasopharyngeal Angiofibroma

MRI: Magnetic Resonance Imaging scan

REFERENCES

1. Capodiferro S, Favia G, Lacaíta MG, Muzio LL, Maiorano E. Juvenile angiofibroma: report of a case with primary intra-oral presentation. *Oral Oncology Extra* 2005 Jan 1;41(1):1-6. DOI: <https://doi.org/10.1016/j.ooe.2004.09.001>
2. Abboud FZ, Youssoufi MA, Zoukal S, Bouhafa T, Hassouni K. Recurrent pterygo-palatal angiofibroma with intracranial extension: case report. *Pan Afr Med J* 2020 Jun 25;36(1): 128. DOI: 10.11604/pamj.2020.36.128.22435
3. Mahajan A, Gupta K. Juvenile Nasopharyngeal Angiofibroma [Internet]. *Pharynx - Diagnosis and Treatment*. Intech Open; 2021. DOI: 10.5772/intechopen.95923.
4. Ganguly S, Gawarle SH, Keche PN. Extra-Nasopharyngeal Angiofibroma in a Pre-Pubertal Child. *J Clin Diagn Res* 2017 Oct 1;11(10). DOI: 10.7860/JCDR/2017/27897.10771
5. Singh GB, Agarwal S, Arora R, Doloi P, Kumar D. A rare case of angiofibroma arising from inferior turbinate in a female. *J Clin Diagn Res* 2016 Apr; 10(4):MD07. DOI: 10.7860/JCDR/2016/18548.7621
6. Yan YY, Lai C, Wu L, Fu Y. Extranasopharyngeal angiofibroma in children: A case report. *World J Clin Cases* 2022 Jul 7;10(21):7429. DOI: 10.12998/wjcc.v10.i21.7429
7. Antoniadis K, Antoniadis DZ, Antoniadis V. Juvenile angiofibroma: report of a case with intraoral presentation. *Oral Surg Oral Med Oral Pathol Oral Radiol Endod* 2002 Aug 1;94(2):228-32. DOI: <https://doi.org/10.1067/moe.2002.125582>
8. Arora K, Muraleedharan M, Bansal S. Juvenile Nasopharyngeal Angiofibroma with Midline Palatal Ulceration: A Rare Presentation. *J Postgrad Med Edu Res* 2021;55(3):136-8. DOI:10.5005/jp-journals-10028-1436
9. Kabot TE, Goldman ME, Bergman S, Schwartz RD. Juvenile nasopharyngeal angiofibroma: an unusual presentation in the oral cavity. *Oral Surg Oral Med Oral Pathol* 1985 May 1;59(5):453-7. DOI: 10.1016/0030-4220(85)90080-5
10. Nandhini J, Ramasamy S, Kaul RN, Austin RD. Juvenile primary extranasopharyngeal angiofibroma, presenting as cheek swelling. *J Oral Maxillofac Pathol* 2018 Jan; 22 (Suppl 1):S73-S76. DOI: 10.4103/jomfp.JOMFP_43_17
11. Nabila A, Sumarta NP, Prasetyo O. A rare case of angiofibroma mimicking fibrous epulis in posterior gingival mucosa. *Acta Medica Philippina* 2021 Nov 24; 55(8). DOI: <https://doi.org/10.47895/amp.v55i8.2128>