

Keystone to Transposition Flap: Our Experience

Marenika¹, Neljo², Ravi Kumar Chittoria³

How to cite this article:

Marenika, Neljo, Ravi Kumar Chittoria/Keystone to Transposition Flap: Our Experience/Indian J Canc Educ Res 2022;10(2):81-84.

Abstract

Squamous cell carcinoma is one of the most prevalent skin cancers, and it can appear in any burn scar. Its incidence ranges from 2% to 6%. A local fasciocutaneous advancement perforator flap based on the underlying perforator is known as a Keystone flap.¹ A transposition flap is raised from a laxity area, lifted over neighbouring tissue, and transplanted into a surgical wound. To mobilise and move tissue from a region of laxity to an area of necessity, adjacent laxity is used.² Delaying the conversion of the keystone flap to a transposition flap in our study resulted in good survival and a positive outcome.

Keywords: Squamous cell cancer; Delay; Keystone flap; Transposition flap.

INTRODUCTION

Squamous cell carcinoma is a type of skin cancer that can appear in burn scars, traumatised, chronically inflammatory scarred skin, and post-radiotherapy scars. The likelihood of a persistent ulcer developing into a cancer ranges from 2% to 6%.² For any defect that may be closed principally, a keystone designed flap is often employed for loco-regional restoration. The keystone flap is a type of local flap that helps to close a defect without using tension. It's straightforward, with greater aesthetic outcomes and consistent coverage.² Other flaps for reconstruction have been described, including local, regional, distant, and microvascular flaps.

The delay phenomenon, also known as ischemia preconditioning, illustrates how a partially ischemic tissue will undergo neovascularization and improve its vascularity. A transposition flap is raised from a laxity area, lifted over neighbouring tissue, and transplanted into a surgical wound. Transposition flaps accomplish tension redirection and redistribution even better than rotation. To mobilise and transfer tissue from a region of laxity to an area of "need," adjacent laxity is used. Transposition flaps can divert tension vectors fully perpendicular to the desired primary motion of the repair, effectively pushing tissue into the wound to prevent tension on a critical structure or free margin. The rhombic design is the prototype for this flap group.¹⁻³

Author Affiliation: ^{1,2}Senior Resident, Department of Plastic Surgery, ³Professor, Department of Plastic Surgery & Head of IT Wing and Telemedicine, Jawaharlal Institute of Postgraduate Medical Education and Research, Pondicherry 605006, India.

Corresponding Author: Ravi Kumar Chittoria, Professor, Department of Plastic Surgery & Head of IT Wing and Telemedicine, Jawaharlal Institute of Postgraduate Medical Education and Research, Pondicherry 605006, India.

E-mail: drchittoria@gmail.com

Received on: 15.06.2022

Accepted on: 20.07.2022

METHODS AND MATERIALS

The study was carried out in a tertiary care hospital in South India after receiving approval from departmental ethical committee. The patient was a 32 year-old male with a 10-year history of electrical burns, during which he acquired a non-healing back ulcer. On examination, the ulcer was

located on the back, further to the right of the midline, and was oval in shape with everted edges. (Fig. 1) The patient got a CT Dorsolumbar scan to rule out osteomyelitis after the initial standard investigation. The back ulcer was excised and histology was performed to rule out any malignant aetiology.

The defect was 6 cm broad and 10 cm long after resection (Fig. 2). Squamous cell cancer was confirmed on histopathology. Due to the presence of squamous cell carcinoma, a staging evaluation

was performed, which ruled out regional and distant metastasis. After the defect was closed, radiotherapy was recommended to the spot. Because the surrounding tissue was unhealthy, the first stage operation was a delayed staged type 3 keystone flap. (Fig. 3, 4) Based on vascularity and clinical judgement, the remaining delayed staged keystone flap or transposition flap will be performed on the opposite side in the second stage (Fig. 5). After the keystone flap, we planned for a transposition flap to cover the defect (Fig. 6, 7).

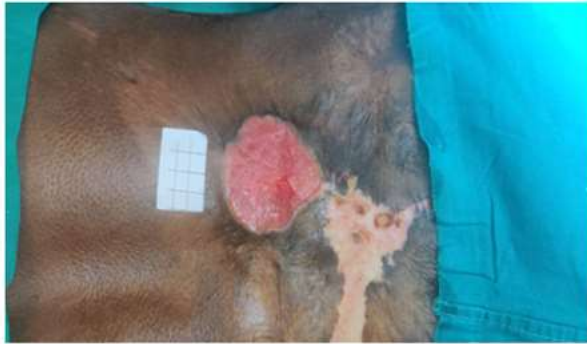

Fig. 1: Raw area of back

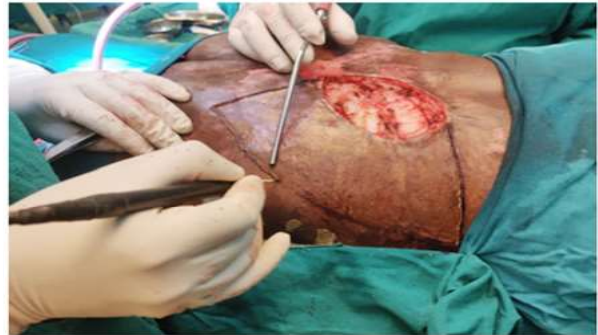

Fig. 2: Raising of the flap in delayed staged keystone flap

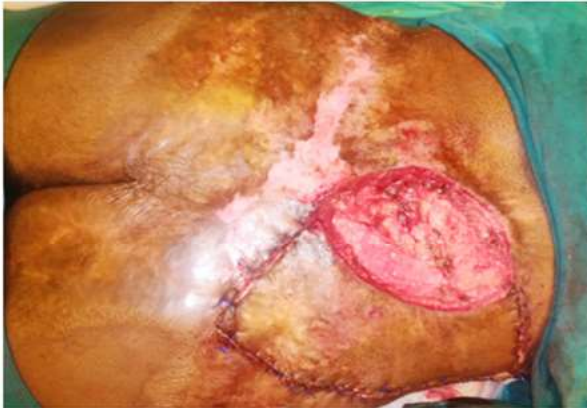

Fig. 3: Delaying of the keystone flap by re-suturing

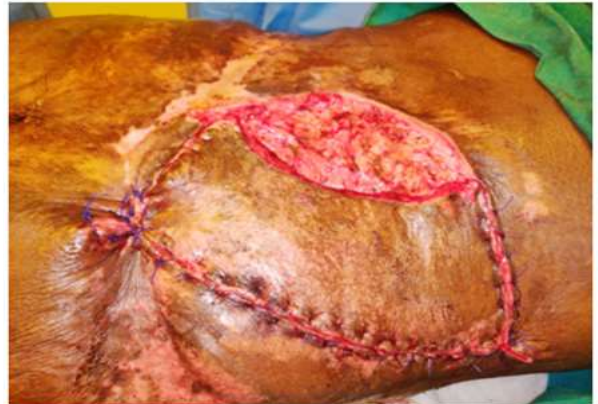

Fig. 4: Inset of the delayed staged keystone flap

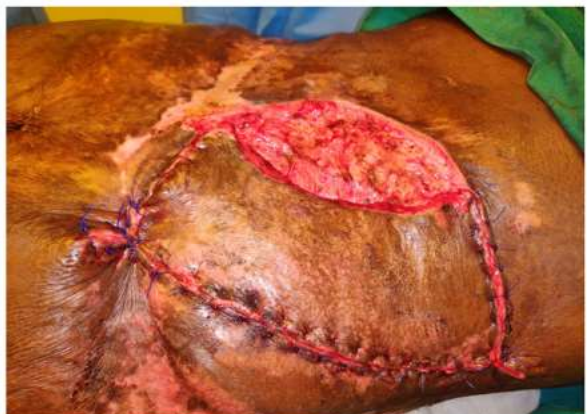

Fig. 5: Defect of opposite site

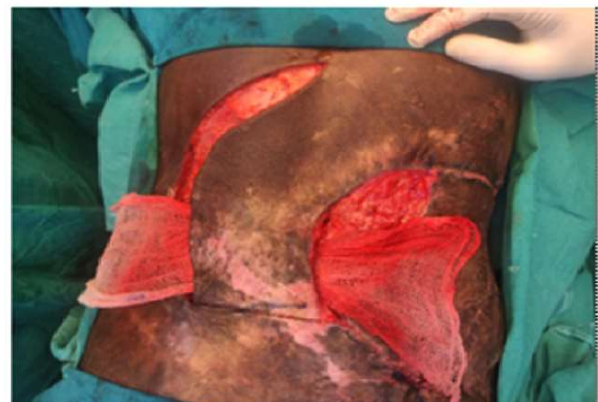


Fig. 6: Transposition flap

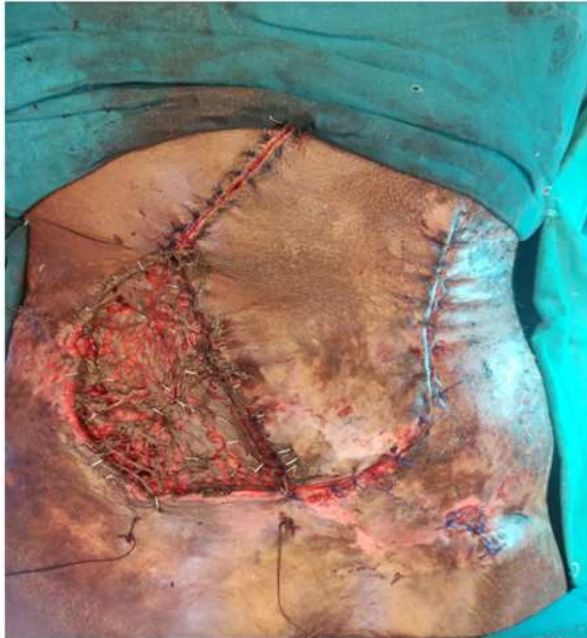

Fig. 7: Transposition flap with SSG

RESULTS

In our study, We were able to successfully minimize the size of the defect by 40% without necrosis of inset flap by doing a delayed staged type 3A keystone flap (Fig. 4). Based on the vascularity and clinical judgement we plan to treat the remaining defect with a transposition flap.

DISCUSSION

The keystone flap is a type of local flap that helps to close a defect without using tension. It's commonly a trapezoidal flap with a curvilinear shape. End to end, it's basically two V-Y flaps. Behan is the one who first described and classified it. Because the design of this flap is comparable to the keystone used to support the arch in Roman buildings, it is termed keystone flap. The excision should be parallel to the vasculature or the line of perforators in that region when creating a keystone flap. These fasciocutaneous perforators serve as the foundation for the flap. There are four different types of keystone flaps.⁵

- Type1 : Standard flap design without deep fascia cutting (suitable for defects up to 2 cm wide)
- Type 2A : Traditional flap with a deep fascia cut
- Type 2A : Flap inset closes the defect primarily
- Type 2B : Secondary defect created which is covered using split thickness skin graft

Type 3 : Double keystone flaps, designed on either side of the defect

Type 4 : Rotational keystone flap

In our study we decided to choose Type 3A delayed keystone flaps. Pelissier et al. have described it as universally applicable and extremely reliable flap for defects from head to toe.^{4,5} When simple primary closure, second intention, skin grafting, or sliding flaps are used to heal surgicalflaws, there is a risk of functional damage and/or aesthetically unfavorable results. When compared to large, sliding flaps, transposition flaps offer less undermining and a better ability to transfer tension away from the defect and any adjacent free margins, as well as reorient tension. Edema, discomfort, infection, flap necrosis, scarring, bleeding/hematoma, and hypertrophic scar orkeloid are all possible side effects of these treatments. The trapdoor effect, which has a pincushion appearance, is quite unique to transposition flaps (elevation of part of the flap above surrounding skin). Insufficient tissue undermining, a large flap, extra subcutaneous fat in the flap, or insufficient flap contact with the wound base can all exacerbate this condition. When the flap is superiorly based and the lymphatic drainage routes are blocked at the dependent aspect of the flap owing to an incision, trapdoor abnormalities are more prone to occur.²⁻⁵

CONCLUSION

Both the keystone and transposition flaps achieve off-midline closure and efficient procedures for closing wounds. Unlike rhombic flap procedures, the KPIF does not require considerable tissue mobilisation and retains a strong blood supply with minimum strain. We can use the updated KPIF when a greater excision is necessary. Although both approaches have proven to be effective, the keystone flap technique appears to be the safer option. With excision and KPIF reconstruction, we were able to successfully treat PSD with no recurrence and minor postoperative problems. Finally, we believe that KPIF is a good alternative for managing PSD because its elevation is simple, quick, and safe.

REFERENCES

1. Kopp J, Loos B, Spilker G, Horch RE: Correlation between serum creatinine kinase levels and extent of muscle damage in electrical burns. Burns. 2004.
2. Robert S. Bednarek and Miguel Sequeira Campos and Marc H. Hohman and Michael L. Ramsey,

- Roenigk's Dermatologic Surgery: Current Techniques in Procedural Dermatology.
3. Stekelenburg CM, Marck RE, Tuinebreijer WE, de Vet HC, Ogawa R, van Zuijlen PP. A systematic review on burn scar contracture treatment: Searching for evidence. *J Burn Care*.
 4. Behan FC. The keystone design perforator island flap in reconstructive surgery. *ANZ J Surg*.
 5. Mohan AT, Rammos CK, Akhavan AA, Martinez J, Wu PS, Moran SL, et al. Evolving concepts of keystone perforator island flaps (KPIF): Principles of perforator anatomy, design modifications, and extended clinical applications. *Plast Reconstr Surg*.

