

Intestinal Tuberculosis: A Case Report with Review of Literature

Nanda patil¹, Nidhi Goswami², Neha Desai³, Dhara Dodia⁴, Manasi Tamber⁵

How to cite this article:

Nanda patil, Nidhi Goswami, Neha Desai. Intestinal Tuberculosis: A Case Report with Review of Literature. *Ind Jr of Path: Res and Practice* 2024;13(1) 25-28.

Abstract

Tuberculous enteritis is seen in 1-3% of cases of tuberculosis worldwide. The bacterium enters gastrointestinal tract via hematogenous spread from active pulmonary tuberculosis by swallowing the infected sputum or ingestion of contaminated food products. The most common site is ileocecal region. Diagnosis is challenging as clinical presentation mimics neoplasm or inflammatory bowel disease. We present a case of intestinal tuberculosis in a 40 years old male patient to highlight the pathogenesis, clinical features and histopathology of this case.

Keywords: Tuberculosis, Gastrointestinal tract, Bowel obstruction, Perforation.

INTRODUCTION

Extrapulmonary tuberculosis is seen in 20% of cases of tuberculosis in immunocompetent patients, amongst these tuberculous enteritis accounts for 1-3% cases worldwide. The common site is ileocecal junction.^{1,2} However, any segment of gastrointestinal tract can be affected. Clinical presentation in these cases is vague and diagnosis requires a high index of suspicion.^{3,4} We report a case of intestinal tuberculosis in a 40 years old male

patient presenting as intestinal obstruction and perforation.

CASE REPORT

A 40 years male patient presented with pain in abdomen since five days and constipation since three days. There was no history of loose motions. His HIV status was non-reactive. Patient was not a known case of Diabetes, Hypertension.

Chest X-ray revealed pulmonary tuberculosis and X-ray abdomen showed multiple air fluid levels (Fig. 1). Complete blood count was Hb - 9.7 gm% (Normal range 13.5 - 18.0 gm%). Total and differential counts were within normal limit. Erythrocyte sedimentation rate was 80 mm at the end of one hour. USG abdomen and pelvis showed clumped ileal loops and ascending colon with wall thickening, there was mesenteric lymphadenopathy and inter bowel fluid in right iliac region. CT abdomen and pelvis revealed a diffuse circumscribed wall thickening of caecum, proximal ascending colon and terminal ileum with reactive mesenteric lymph nodes. Emergency

Author Affiliation: ¹Professor, Department of Pathology, ²⁻³Tutor, Krishna Vishwa Vidyapeeth, Karad, Maharashtra 415539, India.

Corresponding Author: Nidhi Goswami, Tutor, Department of Pathology, Krishna Vishwa Vidyapeeth, Karad, Maharashtra 415539, India.

E-mail: nidhigoswami@gmail.com

Received on: 04.04.2024

Accepted on: 10.05.2024

laparotomy was done and entire ascending colon, caecum and 10 cm ileum was resected and was sent for histopathological examination. The clinical diagnosis was ascending colon mass with intestinal obstruction.

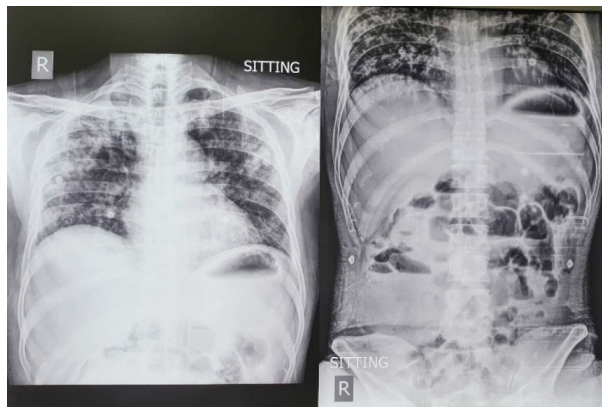


Fig. 1: Chest Xray- multiple air fluid levels.

Gross examination

Gross examination showed a resected specimen of ileocecal mass with ascending colon. External surface was covered with a grey brown serosal exudate with adhesions. Appendix was adhered to caecum. Total 68 mesenteric lymph nodes were dissected. On cut section there was horizontal ulcer with stricture formation four cm away from distal surgical margin. The rest of intestine revealed thickening of the wall (Fig. 2,3).

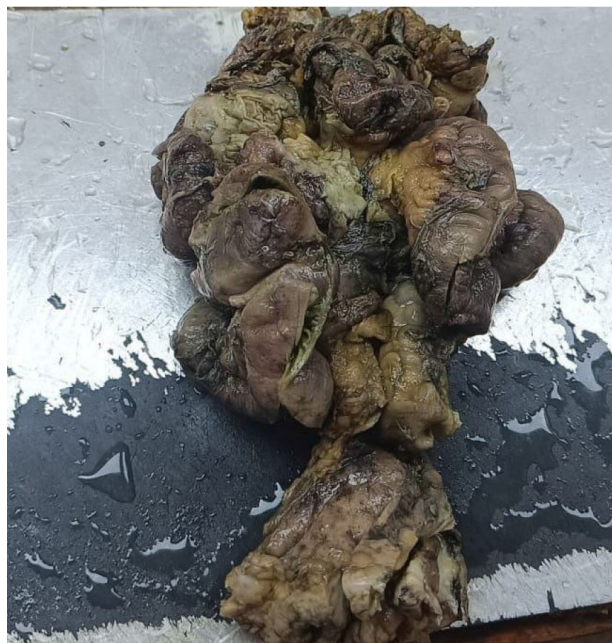

Fig. 2: Intestinal adhesions and wall thickening forming a mass.

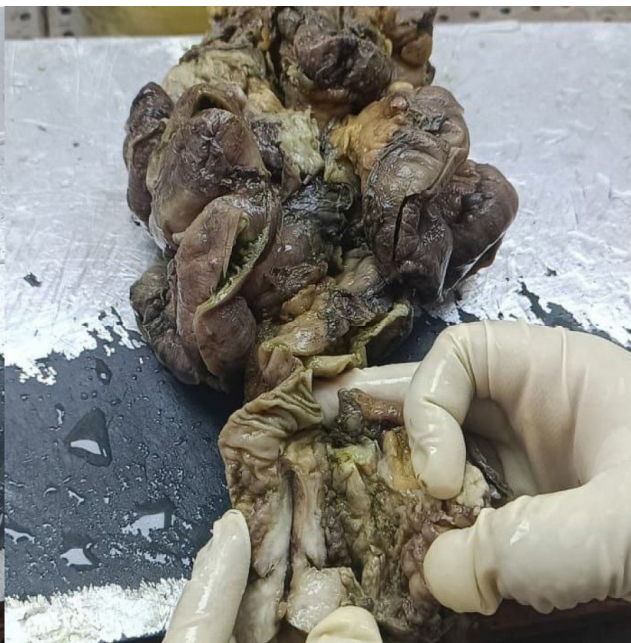

Fig. 3: Oval mucosal ulcer with stricture.

Microscopic examination:

Microscopic examination of the ileum, cecum, colon with stricture area as well as appendix revealed numerous granulomas composed of epithelioid cells, Langhans giant cells and lymphocytes with caseous necrosis and fibrosis. 20% ZN staining was negative for acid fast bacilli. Considering these features diagnosis offered was necrotizing granulomatous inflammation suggestive of tuberculosis Hyperplastic ileo-cecal tuberculosis with tuberculous ulcer with stricture formation and tuberculous mesenteric lymphadenitis, as well as tuberculous appendicitis. (Fig. 4-6)

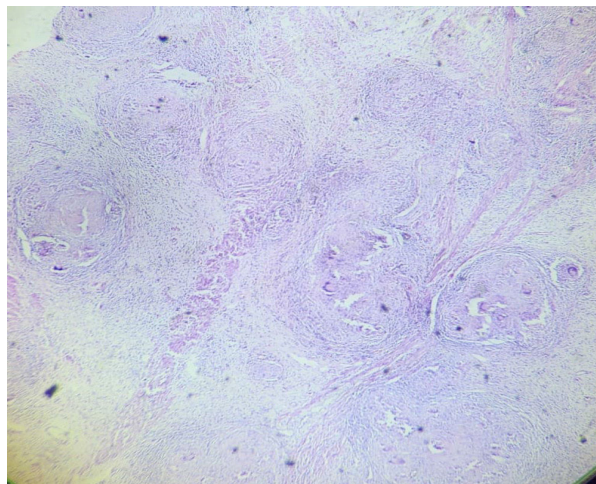


Fig. 4: Necrotizing granulomatous inflammation in resected ileocecal segment (40 x H&E)

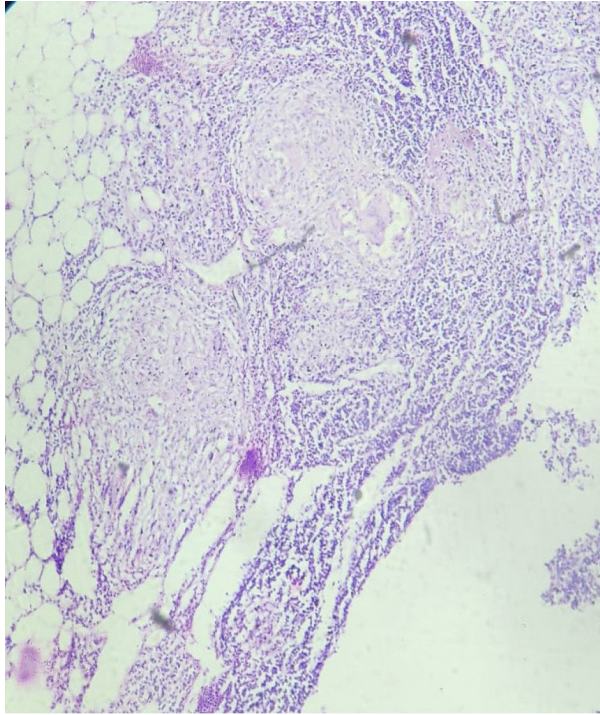


Fig. 5: Granulomatous inflammation in lymph node (100 x H&E)

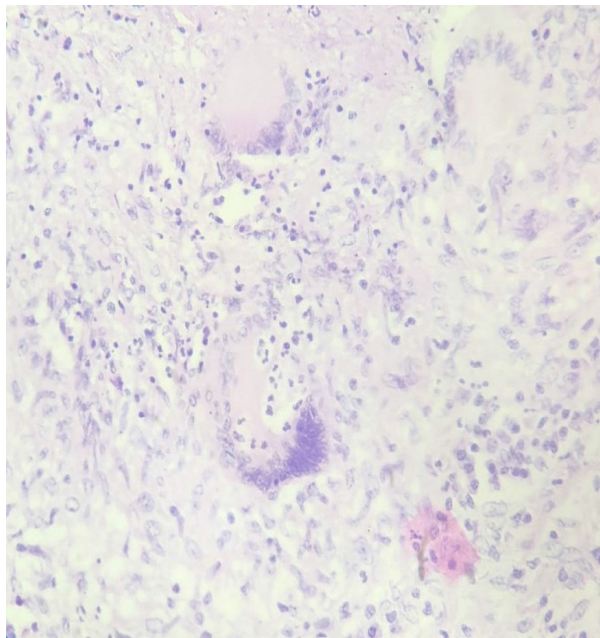


Fig. 6: Granuloma composed of epithelioid cells, Langhans giant cells and lymphocytes. (400 x H&E)

DISCUSSION

Peritoneal tuberculosis is commonest presentation in patients with abdominal tuberculosis.⁵ The commonest age group involved

as suggested by epidemiological data is 35 years to 45 years, affecting both sexes equally. Risk factor for the disease include immunosuppression- HIV infection, renal failure, cirrhosis and malnutrition.⁶ However, in our case there was no risk factor. The spread of mycobacteria to the gastrointestinal tract occurs via four main routes. This can be swallowing of contaminated sputum from active case of tuberculosis, hematogenous spread from active pulmonary infection, continuous spread from adjacent lymph nodes or visceral organs and rarely from consumption of contaminated unpasteurized dairy food.^{7,8} 66% of cases of abdominal tuberculosis involve ileocecal region. The affinity for this site may be due to relative stasis and abundant lymphoid tissue in this area. Pathogenic bacteria invade through the intestinal mucosa into the submucosa. Penetration of gastrointestinal mucosa leads to dense chronic granulomatous inflammation, mucosal ulceration and necrosis. However, tuberculosis can affect any location throughout the gastrointestinal tract from oral cavity to the rectum. Three patterns of gastrointestinal tuberculosis are described. The first is thickened peritoneum with ascites and scattered tubercular nodules. The second pattern is thickened peritoneum with ascites without tubercular nodules. The third one is extensive thickened peritoneum with fibrous adhesions with relative absence of ascites. The third pattern is also known as fibro adhesive type, which is least common and occurs in 5 to 13% of abdominal tuberculosis cases.⁹ Our case also presented with similar pattern. Chronic abdominal pain is the commonest clinical feature associated with anorexia, fever, fatigue, diarrhea or constipation and blood in stool. The enteritis present with clinical, radiographic and histopathological findings which mimics malignancy, inflammatory bowel disease and infectious etiology (Amebiasis, Histoplasmosis, Actinomycosis).

Complications of tuberculous enteritis include perforation, bleeding, fistula formation and obstruction due to fibrous adhesion. In our case complication was obstruction as well as stricture.

The commonest radiographic observation is concentric mucosal thickening of ileocecal junction with or without proximal intestinal dilatation. Other laboratory findings are anemia, elevated ESR which was also observed in our case. Barium studies can help in demonstrating mucosal ulceration, stricture and deformed cecum. CT abdomen helps in identification of intra and extra luminal pathology as well as abdominal pathology. Endoscopy can identify ulcers, stricture, deformed cecum and fistula. It also helps to obtain diagnostic tissue

sampling. Ascitic fluid analysis for mycobacterium culture and PCR can be tried. While clinical presentation, ascitic fluid analysis, laboratory and radiological investigation may give strong suspicion of intestinal tuberculosis, diagnostic laparoscopy is often required for confirmation of diagnosis. Laparoscopic observation with sampling of tissue for histopathology gives high diagnostic yield.

Histopathological examination reveals necrotizing granulomatous inflammation and may show mycobacteria with acid fast staining. One large study have stated that acid fast bacilli & mycobacteria tuberculosis culture positivity in gastro intestinal biopsy is found in only 17% and 29% of cases respectively. Acid fast bacilli are found in < 33% of cases.¹⁰

TREATMENT

Antimicrobial therapy including Rifampicin, Isoniazid, Pyrazinamide and Ethambutol for two months, followed by Rifampicin and Isoniazid for additional six months is the mainstay of the treatment. Surgical or endoscopic intervention is needed in cases complicated by perforation or intestinal obstruction as seen in our case.

A high index of suspicion is necessary to diagnose intestinal tuberculosis. A presumptive diagnosis of tuberculous enteritis can be made in presence of active pulmonary tuberculosis as seen in our case. One year mortality rate of these cases is high as 20%.³ In our case also death was due to intestinal obstruction and perforation with peritonitis.

CONCLUSION

The clinical presentation of tuberculous enteritis is vague and the diagnosis is often difficult to make. The diagnosis is challenging as clinical features mimics neoplasm and inflammatory bowel disease. Definite diagnosis is done with histopathological examination.

REFERENCES

1. P. B. Tripathi and A. D. Amarapurkar, "Morphological spectrum of gastrointestinal tuberculosis," *Trop Gastroenterol*, 2009, 30(1) 35-39.
2. J. B. Marshall, "Tuberculosis of the gastrointestinal tract and peritoneum," *Am. J. Gastroenterol. Suppl.* 1993, 88(7) 989-999.
3. K. D. Horvath and R. L. Whelan, "Intestinal tuberculosis: return of an old disease" *Am. J. Gastroenterol. Suppl.* 1998, 93(5) 692-696.
4. U. Debi, V. Ravisankar, K. K. Prasad, S. K. Sinha, and A. K. Sharma, "Abdominal tuberculosis of the gastrointestinal tract: revisited," *World J Gastroenterol* 2014, 20(40), 14831-14840.
5. Dasgupta A, Singh N, Bhatia A. Abdominal tuberculosis: a histopathological study with special reference to intestinal perforation and mesenteric vasculopathy. *J Lab Phys* 2009; 1:56-61.
6. Aguado JM, Pons F, Casafont F, San Miguel G, Valle R. Tuberculous peritonitis: a study comparing cirrhotic and noncirrhotic patients. *J Clin Gastroenterol* 1990; 12:550-4.
7. Horvath KD, Whelan RL. Intestinal tuberculosis: return of an old disease. *Am J Gastroenterol* 1998; 93:692-6.
8. Kapoor VK. Abdominal tuberculosis. *Postgrad Med J* 1998 74:459-67.
9. Bhargava DK, ShrinivasChopraP, Nijhawan S et.al. Peritoneal tuberculosis: laparoscopic patterns and its diagnostic accuracy. *Am J Gastroenterol* 1992; 87:109-12.
10. Almadi MA, Ghosh S, Aljebreen AM. Differentiating intestinal tuberculosis from Crohn's disease: a diagnostic challenge. *Am J Gastroenterol* 2009;104:1003-12.
11. Dilauro S, Crum-Cianflone NF. Ileitis: when it is not Crohn's disease. *Curr Gastroenterol Rep* 2010;12:249-58
12. Y. J. Lee, S.-K. Yang, S. J. Myung et al., "The usefulness of colonoscopic biopsy in the diagnosis of intestinal tuberculosis and pattern of concomitant extra-intestinal tuberculosis," *Korean J gastroenterol*, 2004, 44(3)153-159.

