

# Anaesthesia Considerations for Patients Undergoing Cytoreductive Surgeries with Hyperthermic Intraperitoneal Chemotherapy

Tarun Kumar Reddy<sup>1</sup>, Ravi Madhusudhana<sup>2</sup>, Kiran Nelamangala<sup>3</sup>

## How to cite this article:

Tarun Kumar Reddy, Ravi Madhusudhana, Kiran Nelamangala. Anaesthesia Considerations for Patients Undergoing Cytoreductive Surgeries with Hyperthermic Intraperitoneal Chemotherapy. *Ind J Anesth Analg.* 2024; 11(2) 77-81.

## Abstract

Cytoreductive surgeries (CRS) combined with hyperthermic intraperitoneal chemotherapy (HIPEC) has become a multimodal treatment option for patients with peritoneal carcinomatosis.

A 56-year-old female diagnosed with ovarian mucinous cystadenoma+appendicular neoplasm was posted for CRS and HIPEC. The patient a diabetic; a central venous catheter was cited to the right internal jugular vein; an epidural catheter was cited. Anaesthesia was performed according to institutional guidelines; the arterial line was secured, and an oesophageal thermometer was placed intra-operatively.

Successive blood gas analysis was done in the intraoperative period for correction of metabolic and electrolyte disturbances; blood sugars were monitored regularly; and adequate volume replacement was done with crystalloids and blood products.

HIPEC involves the administration of chemoactive drugs; personal protective equipment was worn by all those in the operation theater as a safety measure.

Temperature management is of utmost importance; warmed fluid infusion, warming blankets, and warmers were used.

The total duration of the procedure was 8 hours. Post-operatively, the patient was shifted to the ICU with an endotracheal tube for elective ventilation, closely monitored in the acute care unit, and extubated the next day.

**Keywords:** General anaesthesia; Cytoreductive surgery; Hyperthermic intra-peritoneal chemotherapy.

**Key Messages:** HIPEC is an advanced delivery system for chemotherapy which involves a massive dose of chemo-active agents during the intra-operative period for effective treatment of the malignancy. It involves hyperthermic reaction and timing for a proper effective treatment. It may induce hyperthermia in the patient and haemodynamic collapse during this process. We are presenting this case report after managing successfully.

**Author's Affiliation:** <sup>1</sup>Junior Resident, <sup>2,3</sup>Professor, Department of Anaesthesiology, Sri Devaraj Urs Medical College, Kolar 563101, Karnataka, India.

**Corresponding Author:** Ravi Madhusudhana, Professor, Department of Anaesthesiology, Sri Devaraj Urs Medical College, Kolar 563101, Karnataka, India..

**E-mail:** ravijaggu@gmail.com

**Received on:** 07.03.2024

**Accepted on:** 22.06.2024

## INTRODUCTION

Peritoneal surface malignancies (PSMs) are generally considered the terminal stage of a tumor disease with very poor prognosis.<sup>4</sup> Patients who develop peritoneal carcinomatosis as a result of gynecological and gastrointestinal (GI) tract cancers have a marked decline in quality of life, a high rate of morbidity, and a brief lifespan.



For patients with peritoneal metastases from these tumors, systemic chemotherapy is currently the standard of care (SoC), either in isolation or in conjunction with palliative or cytoreductive surgery (CRS). An alternate course of treatment is CRS with hyperthermic intraoperative peritoneal chemotherapy (HIPEC). The basic idea behind CRS + HIPEC is to treat any microscopic peritoneal metastases that are still present after eliminating all visible (macroscopic) metastases.<sup>3</sup>

Heat-induced peritoneal circulation of chemotherapeutic medicines (often 5-fluorouracil, oxaliplatin, mitomycin or cisplatin) is known as HIPEC.<sup>2</sup> Low-grade appendiceal neoplasms (LAMNs) are characterized by adenomatous alterations in the appendiceal mucosa with uncertain malignant potential, primarily described as "mucinous cystadenomas" A common pattern for LAMNs is "pushing invasion" via the appendiceal wall, with a higher risk of ovarian involvement.<sup>1</sup> It is generally known that ovarian infiltration occurs in appendiceal mucinous neoplasms, and that 50% of individuals with appendiceal tumors have ovarian metastases.<sup>5</sup> (Figure 3)

## CASE REPORT

Here, we present a case of a 56 year old female P2L2 who comes with complaints of abdominal pain, continuous type, on and off, non-radiating, no aggravating or relieves on medication since 1 year, history of loss of weight of about 10 kgs in the last 3 months diagnosed with ovarian mucinous cystadenoma + ? appendicular neoplasm was posted for CRS and HIPEC. (Figure 1)

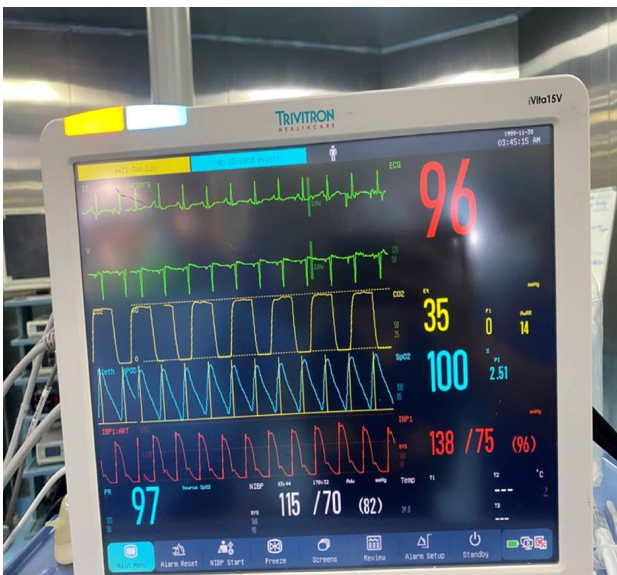


Fig.1: Shows the intra-operative multimodal monitoring

She had undergone Total abdominal hysterectomy + bilateral saphingo-oophorectomy with appendectomy under spinal anaesthesia 15 years ago which was uneventful.

She was a known case of type 2 diabetes mellitus on tab. metformin 500 mg 1-0-1 and Inj. Lantus 0-0-10 sugars were monitored regularly and were under control, patient did not have any other co-morbidities.

On examination vitals were stable with PR: 70bpm, BP: 100/60 mm of Hg, RR 19 cpm, and Spo2 98% on room air. Systemic Examination was normal. Airway examination: teeth intact, no dentures, mouth opening three fingers, unrestricted neck movement with MP4. Histopathology reports showed Low grade appendiceal mucinous neoplasm stage pT4N0M1 b-stage IV B, mucinous with borderline tumour with microinvasion-left ovary.

After a thorough pre-operative evaluation was done bedside and formal pulmonary function tests, formal 2D-ECHO, routine investigations were done and were within normal limits, a written and informed consent was taken and the patient was posted for CRS+HIPEC. (Figure 2)



Fig. 2: Shows the HIPEC machine

Patient was shifted to operating room and multipara monitors attached vitals checked, a triple lumen central venous catheter was secured at the right internal jugular vein, fluids were initiated. An epidural catheter was secured at T9-T10 inter-vertebral space for intraoperative and postoperative management of analgesia.

Patient was premeditated according to institutional guidelines with Inj. Glycopyrrolate

0.2mg, Inj. Fentanyl 100 mcg, preoxygenation with 10 litres O<sub>2</sub> 100% FiO<sub>2</sub> was done for 3 minutes, patient was induced with Inj. Propofol 100 mg, muscle relaxant with Inj. Succinylcholine 100 mg was administered following which direct laryngoscopy was done and the airway was secured using a Portex 7.5mm ID endotracheal tube.

After confirming the Endotracheal tube position by five-point auscultation and ETCO<sub>2</sub>. An oesophageal temperature probe was secured to monitor temperature, an invasive arterial blood pressure monitoring was done, antibiotic prophylaxis was given prior to surgical incision. Intraoperatively patient was maintained with

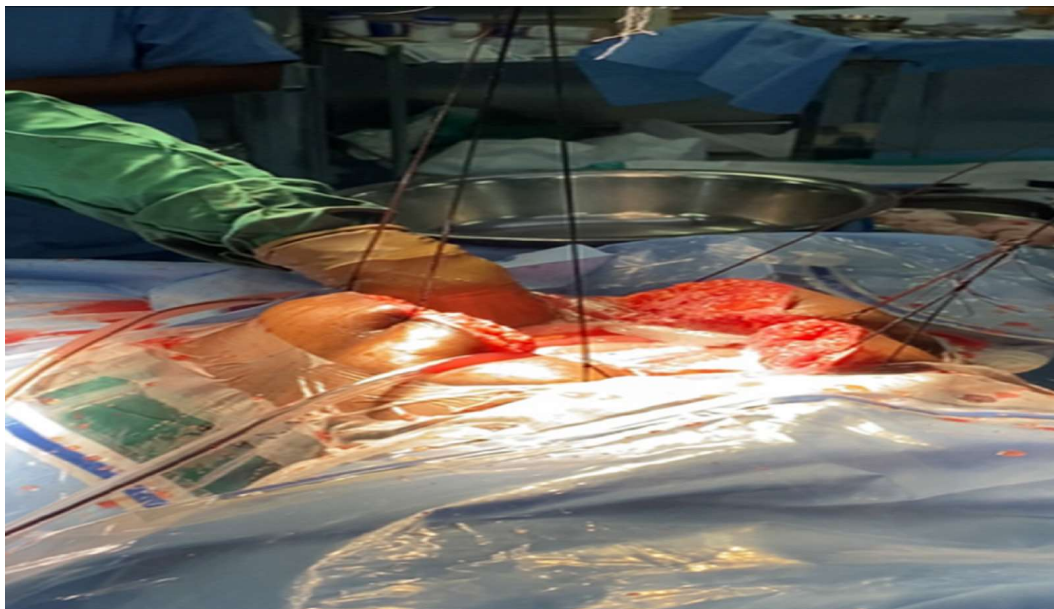


Fig. 3: Shows the administration of chemotherapeutic agent with carrier solution during HIPEC phase

inhalation agents of Oxygen and Nitrogen (50:50), Isoflurane and muscle relaxation with Inj. Vecuronium was given. Intraoperative monitoring consisted of electrocardiography, pulse oximetry, capnography, temperature, invasive blood pressure, central venous pressure, hourly urine output.<sup>3</sup> Successive blood gas analyses were also performed during the intraoperative period to correct metabolic and electrolyte imbalances.<sup>2</sup>

## DISCUSSION

The use of CRS+HIPEC is on the rise worldwide. However, it poses a significant challenge for anaesthesiologists because patients are subjected to a lengthy surgical procedure with a large surgical incision, and significant fluid loss.<sup>2</sup>

In addition to standard laparoscopic or open surgical techniques, CRS with HIPEC is an invasive

abdominal surgical treatment that involves intraoperative temperature and fluid adjustments. In certain cases, the pathophysiological implications of this surgery might lead to the premature failure of an organ. For patients having this surgery, a thorough preoperative evaluation is essential.<sup>(1)</sup> To determine the patient's capacity to adapt to the physiological obstacles encountered during surgery, a complete evaluation of their cardiac and pulmonary systems is necessary. Echocardiography and dynamic cardiac assessments may be required. It is necessary to have a complete blood count, coagulation tests, and levels of electrolytes, urea, and creatinine. Examining the patient's nutritional health and measuring their albumin level before surgery are also crucial. Glomerular filtration rate estimation may be useful in identifying individuals who are susceptible to acute renal damage linked to HIPEC.<sup>1</sup>

Fluid management is important during CRS and hyperthermic chemotherapy infiltration. Major

---

### Selection criteria for HIPEC and CRS

Medical optimization with no active cardiac conditions as per the American Heart Association guidelines on perioperative cardiovascular evaluation and care for noncardiac surgery.

The absence of extra abdominal disease, extensive hepatic metastases, and significant retroperitoneal disease.

Age <70years Peritoneal disease that is amenable to complete or near complete removal.

---

draining surgery can be associated with significant blood loss as well as evaporative losses associated with an open abdomen. HIPEC causes peritoneal inflammation which can lead to perioperative third space loss. Volume replacement was done with 4500mL of crystalloids and one unit of red blood cell (vol. 350mL).

Blood sugar monitoring was done at regular intervals for proper glycaemic control.

A carrier solution with chemotherapeutic agent mitomycin-C was administered and the total duration of HIPEC was 110 minutes CRS with HIPEC can be associated with both hypothermia and hyperthermia. During the cytoreductive phase of the procedure, there is a risk of hypothermia due to the extensive removal procedure and extensive surgical exposure.

Hypothermia increases the risk of blood loss and surgical wound infections and alters the pharmacokinetics of commonly used anaesthetic drugs.<sup>1</sup> Efforts to prevent hypothermia was done by using warmed fluids, fluid warmer, air warmers, prior to commencement of the intraperitoneal chemotherapy, controlled hypothermia can commence by changing to cool intravenous fluids and decreasing room temperature in anticipation of the chemotherapy, which can lead to hyperthermia<sup>1</sup> this hyperthermia was prevented by use of cooling blankets, cold-headed wraps, cooling blocks, administration of cold fluids.

**Safety in the theatre:** The increased use of chemotherapeutic agents in the operating theatre has the potential to pose a risk to theatre staff the complications due to exposure were averted by proper education and training of the personnel, use of personnel protective equipment such as gloves, masks, goggles, protective gown, overshoes, high efficiency particulate air filter type air conditioners, doors were tightly closed till the procedure was completed.

During intra-operative phase epidural analgesia utilizing local anaesthetic was administered regularly to diminish systemic opioid demand and minimizing need for prolonged ventilation.

Total duration of the procedure was 8 hours, post-operatively patient was shifted to ICU with endotracheal tube for elective ventilation, close monitoring in acute care unit and extubated the next day.

An epidural top-up with local anaesthetic was administered as and when the patient complained of pain and the epidural catheter was removed on post-operative day 3.

Patient was started on oral fluids and on solids on day 2 and day 3 of post-operative period respectively.

Patient was discharged on post-operative day 10 with a follow-up advice after 14 days.

Patients undergoing HIPEC expose the anaesthetist to fluid changes, temperature changes, increased intra-abdominal pressure, and increased metabolism. Vigilance with fluid management and hemodynamic monitoring during surgery is extremely important. The use of regional anaesthesia such as an epidural is a useful adjunct to pain relief because of the risk of coagulopathy.<sup>1</sup>

Although CRS + HIPEC is a promising option for primary peritoneal malignancies and gastrointestinal and gynaecologic malignancies with peritoneal metastases, it is a complex operation and perioperative management depends on many factors, including the patient's preoperative health and disease, surgical factors, intraoperative factors, and chemotherapy drugs used for this present several challenges to anaesthesiologists.

## CONCLUSION

CRS and HIPEC is a long, complicated procedure with significant blood and fluid loss. Hemodynamic, hematologic, and metabolic changes before, during HIPEC, and even in the early postoperative phase, can result in significant mortality and morbidity. Therefore, the main goals of CRS with HIPEC are normovolemia, normothermia, coagulation status, and pain control: In our case, the result was promising, as patient was discharged cancer-free on the 15<sup>th</sup> postoperative day due to the combined efforts of an experienced surgical and anaesthesia team.

*Conflict of Interest: Nil*

## REFERENCES

1. Kearsley, Rosemarie & Egan, Sinead & McCaul, Conan. (2018). Anaesthesia for Cytoreductive Surgery with Hyperthermic Intraperitoneal Chemotherapy. Anaesthesia Tutorial of The Week # 379 wfsahq.org.
2. Howbora N, Sonowal SJ, Borah TJ, Kakati SD, Das A, Ninu M, Chintey D. Anesthetic management of cytoreductive surgery and hyperthermic intraperitoneal chemotherapy: A case report. Saudi J Anaesth. 2023;17(2):272-274.

3. Saraswat, Namita; Gupta, Akhilesh; Kaur, Mohandeep; Mahajan, Sakshi. Anaesthesia concerns for Peritonectomy with Hyperthermic Intraoperative Peritoneal Chemotherapy. *Saudi Journal of Anaesthesia* 2019; 13(2) 169-171.
4. Schmidt C, Moritz S, Rath S, Grossmann E, Wiesenack C, Piso P, Graf BM, Bucher M. Perioperative management of patients with cytoreductive surgery for peritoneal carcinomatosis. *J Surg Oncol.* 2009 Sep 15;100(4):297-301. doi: 10.1002/jso.21322. PMID: 19697426.
5. Kajdi ME, Beck-Schimmer B, Held U, Kofmehl R, Lehmann K, Ganter MT. Anaesthesia in patients undergoing cytoreductive surgery with hyperthermic intraperitoneal chemotherapy: retrospective analysis of a single centre three-year experience. *World J Surg Oncol.* 2014 May 1;12:136. doi: 10.1186/1477-7819-12-136. PMID: 24886171; PMCID: PMC4113247.

