

# Management of Tetralogy of Fallot with Major Aortopulmonary Collateral Arteries: Presurgical Endovascular Coil Embolization Experience

Dharmendra Kumar Srivastava<sup>1</sup>, Navneet Srivastava<sup>2</sup>, Abhishek Chauhan<sup>3</sup>, A P Jain<sup>4</sup>

## How to cite this article:

Dharmendra Kumar Srivastava<sup>1</sup>, Navneet Srivastava, Abhishek Chauhan *et al.* Management of Tetralogy of Fallot with Major Aortopulmonary Collateral Arteries: Presurgical Endovascular Coil Embolization Experience. *J Cardiovasc Med Surg.* 2024;10(1-2):15-19.

## Abstract

Tetralogy of Fallot with major aortopulmonary collateral arteries is a complex and heterogeneous condition varying degrees of severity, while MAPCA present in 20-25% with TOF and pulmonary atresia. Our institutional approach to this lesion emphasizes presurgical endovascular multiple coil embolization of significant bilateral MAPCAs along with complete intracardiac repair in the same sitting. The presurgical endovascular coil embolization of all MAPCAs of more than 3mm and complete intracardiac repair were done in the same sitting. The multiple Boston scientific pushable coils of diameters ranging. The presence of MAPCAs is a major determining factor in the prognosis and management of TOF. The role of the cardiac radiologist is not only in reporting critical components regarding collateral arteries and underlying cardiac structural disease but also in the management of TOF with MAPCAs along with cardiac surgeries.

**Keywords:** Aortopulmonary collateral; Coil; Endovascular; Tetralogy of fallot.

## INTRODUCTION

Tetralogy of Fallot (TOF) with major aortopulmonary collateral arteries (MAPCAs) is a complex and heterogeneous condition varying

degrees of severity, while MAPCA present in 20-25% with TOF and pulmonary atresia. Our institutional approach to this lesion emphasizes presurgical endovascular multiple coil embolization of significant bilateral MAPCAs along with complete intracardiac repair in the same sitting.

Embryologic formation: Flowchart depicts the normal pulmonary vasculature development with regression of the segmental arteries as the pulmonary artery develops from the sixth branchial arch. PA pulmonary artery, PDA patent ductus arteriosus, RV right ventricle.<sup>1,2</sup> (Fig. 1 & 2)

**Author's Affiliation:** <sup>1,4,5</sup>Professor, Department of Cardiovascular and Thoracic Surgery, <sup>2</sup>Associate Professor, Department of Cardiovascular and Thoracic Surgery, <sup>4</sup>Additional Professor, Department of Radio diagnosis, Dr. Ram Manohar Lohia Institute of Medical Sciences, Lucknow 226010, Uttar Pradesh, India.

**Corresponding Author:** Dharmendra Kumar Srivastava, Professor, Department of Cardiovascular Thoracic Surgery, Dr. Ram Manohar Lohia Institute of Medical Sciences, Lucknow. Uttar Pradesh-226010, India.

**E-mail:** drdks01@gmail.com

**Received on:** 24.02.2024

**Accepted on:** 25.06.2024

## MATERIAL & METHODS

A 14-years-old boy presented with symptoms of Dyspnoea on exertion, bluish discoloration, signs

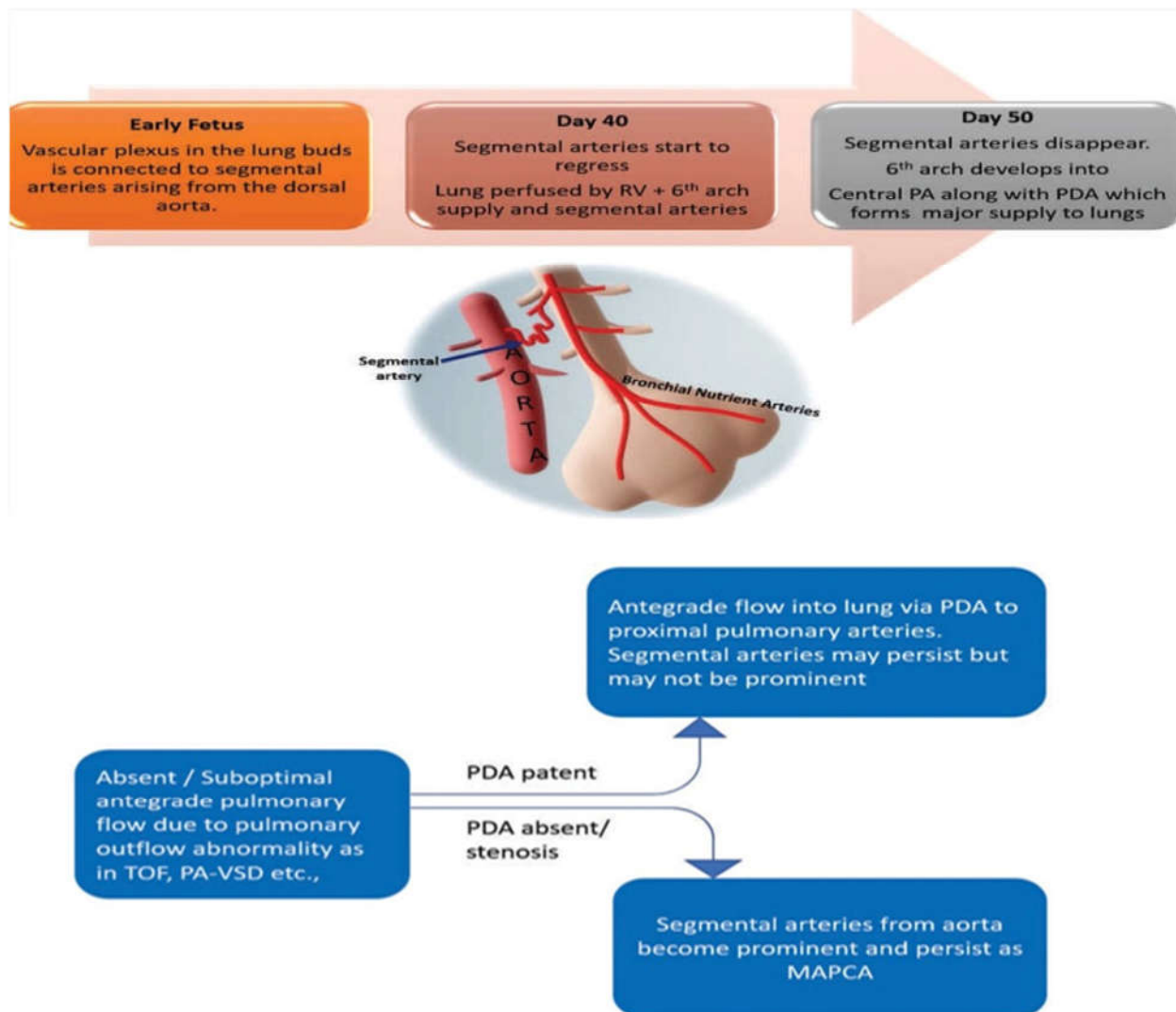


of cyanosis, and clubbing with oxygen saturation on room air 85-89%. Echocardiography and cardiac computerized tomography revealed ventricular septal defect (VSD) of 18mm in size, overriding of the aorta, severe right ventricular outlet obstruction, multiple MAPCAs of 4-6 mm in size, diameters of main, right and left pulmonary arteries 11mm, 8mm and 7.6 mm respectively, right and left coronaries to appear normal. (Fig. 3 & 4) The presurgical endovascular coil embolization of all MAPCAs of more than 3mm and complete intracardiac repair were done in the same sitting. The multiple Boston scientific pushable coils of diameters ranging from 2-6 mm were used through a trans femoral route under digital subtraction angiography. (Fig. 5 & 6) The complete intracardiac

repair includes Dacron patch under moderate hypothermic cardiopulmonary bypass with cold blood cardioplegic arrest with topical cooling.

## RESULTS

The cross-clamp and cardiopulmonary bypass times were 126 minutes and 178 minutes respectively, without any intracardiac blood flooding and complication. The patient was extubated within 6 hours of surgery and ICU stays were 6 days. At follow-up RVOT was found to be of good caliber with mild pulmonary valvular stenosis, no residual VSD, good LV systolic function and patient is on diuretics and beta blockers.



**Fig. 1:** Flowchart shows the development of collateral vessels with regard to the formation of ductus arteriosus. MAPCAs = Major Aortopulmonary Collateral Arteries, PA-VSD = Pulmonary Atresia with Ventricular Septal Defect, PDA = Patent Ductus arteriosus, TOF = Tetralogy of Fallot.

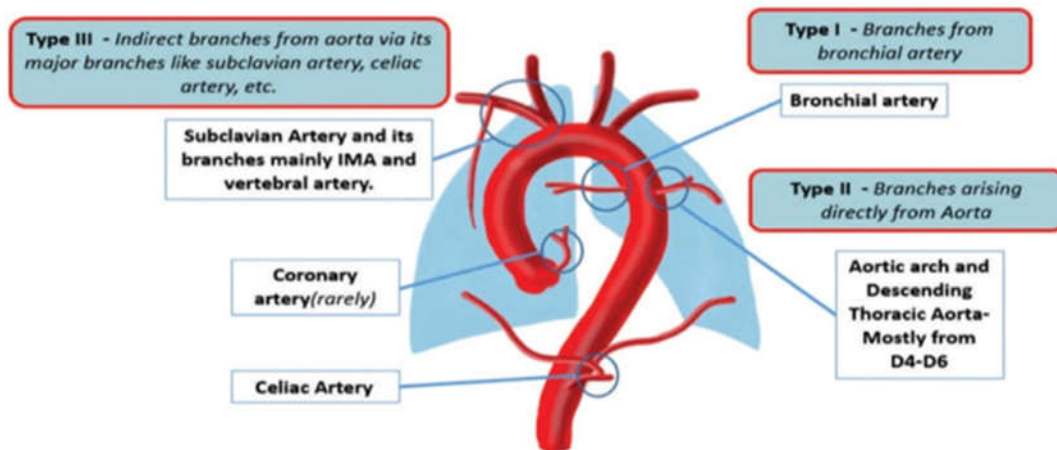


Fig. 2: Diagram representing the common sites of major aortopulmonary collateral arteries origin and classification. D4-D6 = Dorsal Vertebrae 4 to 6, IMA = Internal Mammary Artery.



Fig. 3: CT image shows dilated MAPCAs

## DISCUSSION

With the development of medical technology and computed tomography imaging technology, cardiac surgeon gradually has advanced understanding about the MAPCAs, and their treatment has become an important part of intracardiac correction of TOF.<sup>3,4</sup> The disadvantages of ligation of MAPCAs are surgical field s relatively fixed, creates big wounds, easily damages surrounding tissue, and

consumes time. Transcatheter occlusion, which preferably solves the disadvantages of ligating, is becoming a common method for treating collaterals in recent years.<sup>5</sup> The occlusion can be performed before, during, or after operation. Most research on the management of MAPCAs before surgical correction of TOF; however, occlusion of MAPCAs before surgical correction could lead to a further decrease in arterial oxygen saturation, and the patient needed surgical correction immediately after transcatheter closure of MAPCAs.

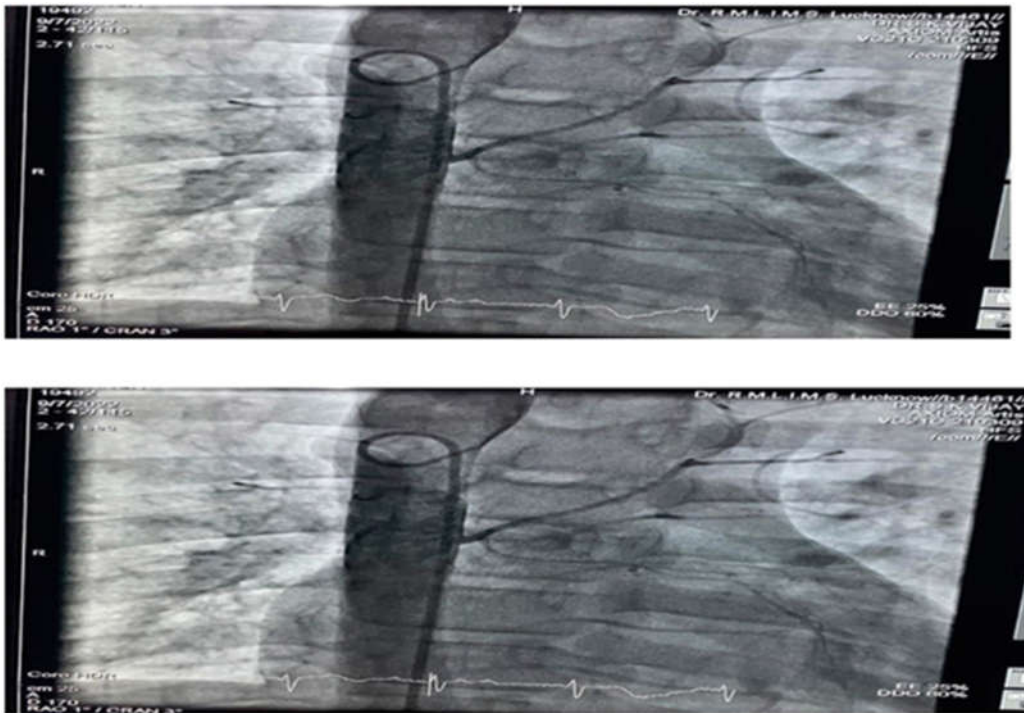


Fig. 4: Descending thoracic aortic angiography image shows the MAPCAs.

**Boston Scientific Pushable Coil Portfolio**  
Versatile and Cost-Effective

**Six Shapes (L to R):** Complex Helical, VortX™, VortX Diamond, Straight, Figure 8, Multi-Loop (2D Helical)

Coil Length	Coil Diameter									
	2 mm	3 mm	4 mm	5 mm	6 mm	7 mm	8 mm	9 mm	10 mm	11 mm
0-3cm										
4-6cm										
7-9cm										

Legend: 0.018" Pushable Coils (Blue), 0.035" Pushable Coils (Yellow)

- Include highly thrombogenic, dense Dacron™ fibers designed for fast and complete occlusion
- Have MRI conditional compatibility (up to 3.0 Tesla)
- Are recommended for use with continuous flush setup

---

**Boston Scientific Pushable Coil Portfolio**  
Shape Comparisons & Benefits

Shape	Complex Helical	Straight	Figure 8	Multi-Loop (2D Helical)	VortX	VortX Diamond
<b>Coil Type</b>	Framing	Straight	Fitting	Framing	Fitting	Fitting
<b>Benefit</b>	Provide structure around the vessel wall	Fill small accessory vessels prone to spasm	Short length fits small vessel area	Provide structure around the vessel wall	Fillable shape helps to fill vessels tightly	Center coil adheres to vessel wall while sides taper down and fill area
<b>Best for</b>	The first and last coil placed in a vessel	Tiny filaments where vessel diameter < 2mm	Small vessels (20mm), such as the right gastric	The first and last coil placed in a vessel	Filling a segment of a vessel proximal to a framing coil	Filling a segment of a vessel proximal to a framing coil

Fig. 5: Boston coils of different shapes and sizes (Source: <https://www.bostonscientific.com/content/dam/bostonscientific/pi/product-catalog/2023-EMEA-PI-Product-Catalogue-Eluvia-Ranger-Update%282%29.pdf>)

## CONCLUSION

The presence of MAPCAs is a major determining factor in the prognosis and management of TOF

The role of the cardiac radiologist is not only in reporting critical components regarding collateral arteries and underlying cardiac structural disease but also in the management of TOF with MAPCAs along with cardiac surgeons.

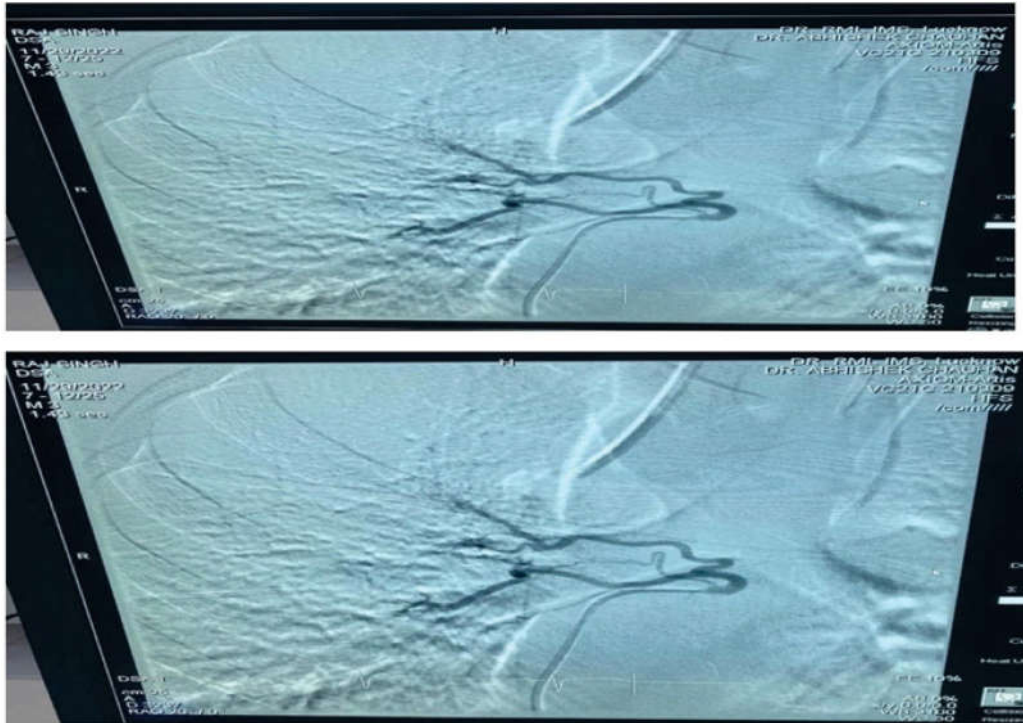


Fig. 6: Coils in aortopulmonary Collaterals

## REFERENCES

1. Rabinovitch M, Herrera de Leon V, Castaneda AR, Reid L. Growth and development of the pulmonary vascular bed in patients with tetralogy of Fallot with or without pulmonary atresia. *Circulation*. 1981; 64:1234-1249.
2. Jefferson K, Rees S, Somerville J. Systemic arterial supply to the lungs in pulmonary atresia and its relation to pulmonary artery development. *Br Heart J*. 1972; 34:418-427.
3. Lapierre C., Dubois J., Rypens F., Raboisson M.-J., Déry J. Tetralogy of fallot: preoperative assessment with MR and CT imaging. *Diagnostic and Interventional Imaging*. 2016;97(5):531-541.
4. Perry S. B., Radtke W., Fellows K, Ekeane J. F., Lock J. E. Coil embolization to occlude aortopulmonary collateral vessels and shunts in patients with congenital heart disease. *Journal of the American College of Cardiology*. 1989; 13(1):100-108.
5. Alex A, Ayyappam A, et al major aortopulmonary collateral arteries. *Radiology Cardiothoracic Imaging* 2022;4(1) 1-12.

