

The Bilobed Sandwich Abdomen Flap: Applications for Combined Volar and Dorsal Hand Defects in the Microsurgical Era

Raghuram Menon¹, Krishna Kumar KS², Ajit Kumar Pati³, Sunos KS⁴,
Srigireesh AR⁵, Sinnet P Roy⁶

How to cite this article:

Raghuram Menon, Krishna Kumar KS, Ajit Kumar Pati *et al.*/The Bilobed Sandwich Abdomen Flap: Applications for Combined Volar and Dorsal Hand Defects in the Microsurgical Era/Journal of Plastic Surgery and Transplantation. 2023;4(2):93-97.

Abstract

Complete cover of both palmar and dorsal aspects of hand and wrist in severe hand injuries is a difficult task with a single flap. Several surgical techniques using local/distant/micro vascular flaps have been developed to resurface such defects. Even though free tissue transfer has become the norm nowadays this is often not possible in a resource constrained set up. Combined bilobed abdominal flaps can be safely raised to resurface large defects of the hand as they are simple, easy, and versatile, with the added advantage of decreased donor site morbidity. Here in our series, we discuss the different types of hand defects which we could resurface with the Bilobed sandwich flap and a few tips in planning this flap.

Keywords: Bilobed Flap; Pedicled Flap; Dorsal Aspects.

INTRODUCTION

The groin flap was quite popular for resurfacing hand defects in the 70s and 80s^{1,2}, but because of the staging, prolonged positioning needed and stiffness associated many units have moved on to free tissue transfer.^{3,4} But in a resource limited set up like ours the abdomen is still our go to area to provide vascularised tissue. The case load which our Plastic surgical units deal with is quite high and we need simpler and less time consuming options furthermore most of our general public does

not have health insurance and even units which perform micro surgery regularly are unable to do so because of the cost factors involved. Groin and abdomen flaps are beginner friendly, fast, and easy to execute and have shown to provide acceptable results provided they are planned well. Here we share our experience with the Bilobed sandwich flap to resurface combined volar and dorsal defects.

Anatomy and Planning

Patients

All patients who underwent wound coverage with the bilobed flap from January 2021 to August 2022 have been included. Almost all patients were debrided in the emergency setting and were planned for flap cover within 24-48 hours except patients who sustained injury due to a sugarcane crusher in whom we waited until 7-10 days before planning for a definitive cover. Patients were deemed fit for discharge once they were ambulant. All flaps were divided at three weeks. Patient details like etiology of injury, defect details, complications and outcome were noted.

Author Affiliation: ^{1,6}Senior Specialist, ²Head of Department, ^{3,4}Senior Consultant, ⁵Consultant, Plastic Surgery, Aster MIMS Hospital, Govindapuram 673016, Calicut, India.

Corresponding Author: Raghuram Menon, Senior Specialist, Plastic and Reconstructive Surgery, Aster MIMS Hospital, Govindapuram 673016, Calicut, India.

E-mail: rgplasticdoc@gmail.com

Received on: 15-04-2023

Accepted on: 01-05-2023

RESULTS

10 patients underwent hand wound resurfacing with the bilobed flap in between January 2021 to

August 2022, age ranged from 19 to 58 years with a mean age of 34.5 years. 9 were males and 1 was a female. The patient data is given below (Table 1) 4 cases were due to a sugarcane crusher machine,

Table 1: Demographic data, defect details, complications and outcome

Age	Sex	Etiology	Region Involved	Complication	Outcome
41	M	Sugar cane machine	Volar / Dorsal palm and digits	None	Satisfactory
26	M	Roller Machine	Volar / Dorsal palm and digits and thumb	Marginal flap necrosis which needed reinserting / SSG of necrotic area after debridement	Satisfactory
19	M	Roller Machine	Volar / Dorsal digits	None	Satisfactory
55	M	Sugar cane machine	Volar / Dorsal palm and digits	None	Satisfactory
28	M	Cracker burst injury	Volar / Dorsal digits	None	Satisfactory
22	M	Punching machine	Volar / Dorsal Palm	None	Satisfactory
58	F	Sugar cane machine	Volar / Dorsal palm and digits	Marginal necrosis which healed with secondary intention	Satisfactory
31	M	Power Press machine	Volar / dorsal wrist and palm	None	Satisfactory
26	M	Sugar cane machine	Volar / Dorsal palm and digits	Marginal necrosis which healed with secondary intention	Satisfactory
39	M	Power Press machine	Volar / Dorsal palm and digits	None	Satisfactory

all were debrided and subsequently dressed daily for till demarcation for 7-10 days followed by debridement and flap cover. 2 cases were due to a power press machine, 2 due to a roller machine and 1 defect was due to a cracker burst injury and 1 due to a punching machine.

All the defects involved both the volar and dorsal regions to varying extent. 3 out of 10 patients had some flap necrosis 2 patients needed debridement and re-insetting, and one patient had marginal necrosis which was debrided and the wound was left to heal secondarily. All patients had satisfactory outcomes.

DISCUSSION

Defects involving both the volar and dorsal regions of the hand can be challenging to reconstruct and single flaps either pedicled or free can be difficult to plan as the defects may sometimes be discontinuous with an intervening skin bridge (Fig. 1) also for large defects it may be difficult to get sufficient coverage with a single flap as it may be difficult to fold and conform the flap according to the defect. The bilobed sandwich flap is very useful in such conditions as the flap may be custom made based on the SCIA/SIEA axis for the dorsal/volar

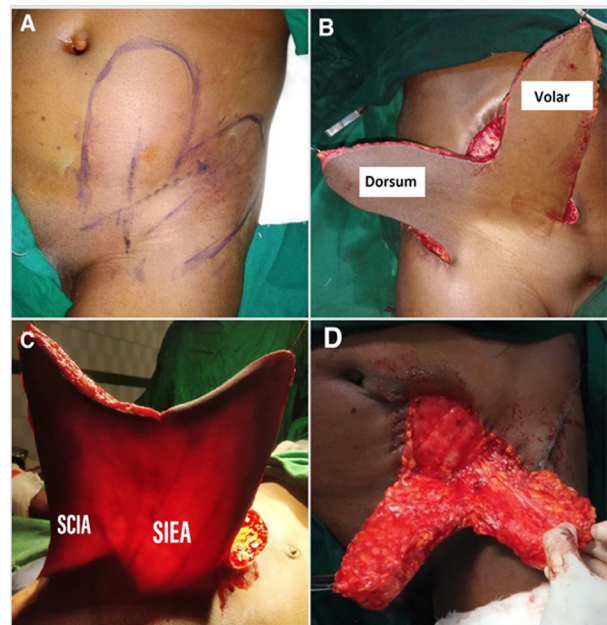


Fig. 1: A,B - Markings, planning and extent of the bilobed flap C,D - Vascular basis, Donor area especially the groin region can be closed primarily

defects respectively.

We had 10 patients and the commonest a etiology was injury due to a sugarcane crusher - 4 patients, followed by power press machine - 3 patients, then

the roller machine - 2 patients, 1 patient following a cracker burst injury (Fig. 7) and 1 due to a Punching machine (Fig. 2)

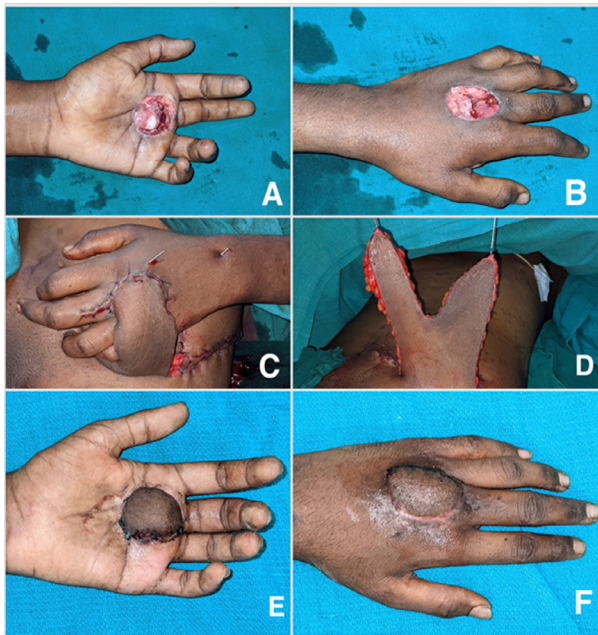


Fig. 2: A,B - Punching machine injury/ C,D - Flap raised and insetted/ E,F - After division

Sugarcane injuries invariably involve both the Palmar and dorsal skin (Fig. 3) and based on the severity of injury there can be soft tissue loss over both the volar and dorsal regions which can be resurfaced with this flap.

Injuries caused due to the roller machine

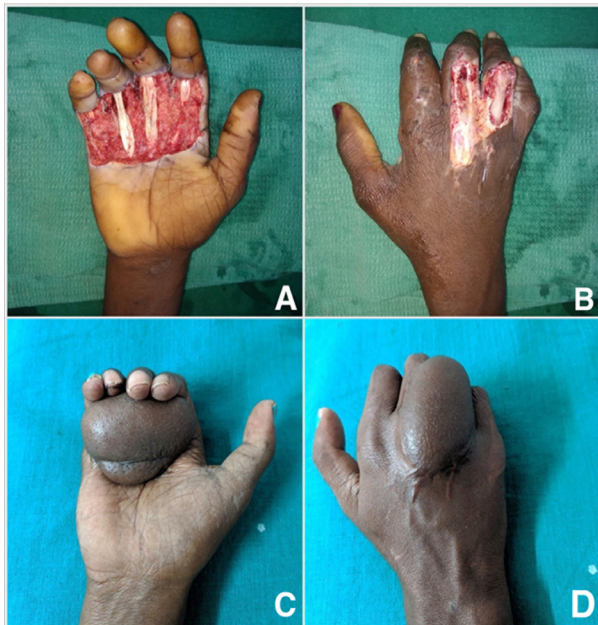

Fig. 3: A,B - Sugarcane crusher injury, 10 days after trauma / C,D - 2 months after flap division, now patient has been planned for syndactyly release

were most devastating as these were degloving injuries and the degloving component ranged from degloving of the digits to involvement of the almost the complete hand (Fig. 4,5). These cases were associated with large soft tissue defects with intact skeletal framework. Various techniques have

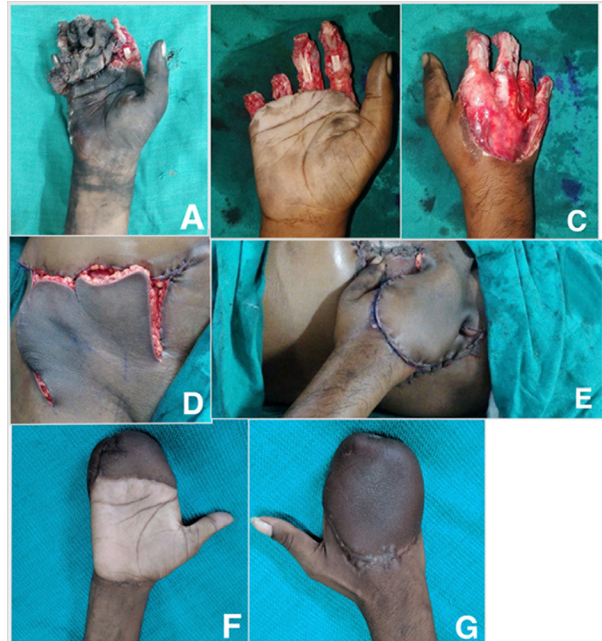

Fig. 4: A,B,C - Roller machine injury / D,E - Flap raised and inset done, donor site skin grafted / F,G - 1 month after division, planned for syndactyly release

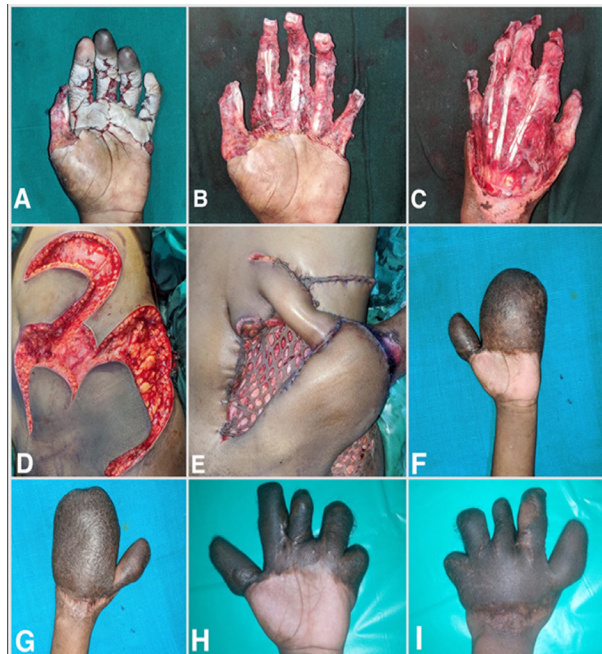

Fig. 5: A,B,C - Roller machine injury / D,E - as thumb was also involved, paraumbilical perforator flap based on the deep inferior epigastric artery perforators was also included with the bilobed flap / F,G - 3 months after flap division / H,I - 14 months after trauma after syndactyly release

been described like the quadrant flap, abdominal pocketing for management of such defects.⁸ With proper planning with the bilobed flap most such defects can be addressed, and avoids need for additional delay or grafting over the palmar region as is needed with abdominal pocketing.⁸

Injuries due to a power press are localised (Fig. 6,7) and in many cases are associated with crush injury to the digits, palmar region with both volar and dorsal soft tissue and skeletal injuries, in such

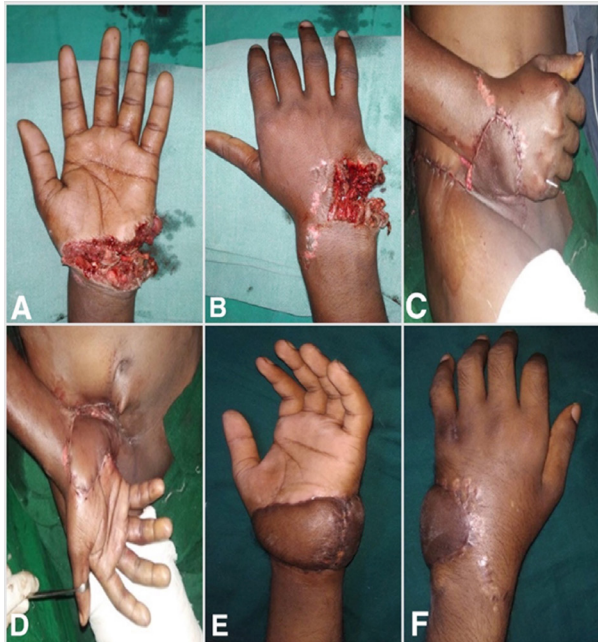

Fig. 6: A,B - Power press machine injury / C,D - After inset, donor sites closed primarily / E,F - 1 months after flap division

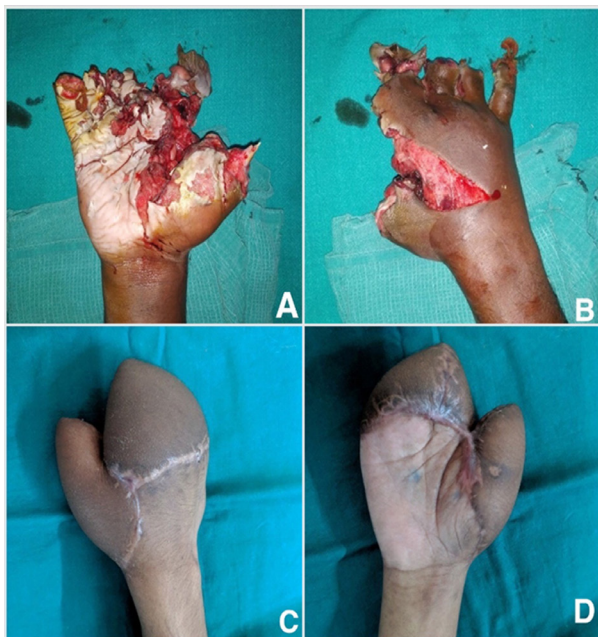


Fig. 7: A,B - Cracker burst injury / C,D - 3 months after flap division

cases especially if there is an associated intervening skin bridge, these flaps are more convenient than free flaps as the intervening skin bridge need not be divided for inset of the free flap.

It is a fact that free flaps can provide large and reliable soft tissue and there is the option to add muscle/bone/nerve as per the reconstructive need. These features make free flaps the primary choice if conditions permit. But even the era of microsurgery, pedicled flaps have a role and are useful if planned well and over the long term can give outcomes like if not better than free flaps. This same experience has been shared by various authors.^{9,10,11} The bilobed flap is an easy, reliable, and reproducible flap which can be tailor made to cover most of the hand defects with minimal post-operative complications. And even in the microsurgical they should form part of every plastic surgeon's armamentarium.

REFERENCES

1. Mc Gregor IA, Jackson IT. The groin flap. *Br J Plast Surg.* 1972; 25:3-16.
2. Al-Qattan MM, Al-Qattan AM. Defining the indications of pedicled groin and abdominal flaps in hand reconstruction in the current microsurgery era. *J Hand Surg Am.* 2016;41(9):917-927.
3. Goertz O, Kapalschinski N, Daigeler A, *et al.* The effectiveness of pedicled groin flaps in the treatment of hand defects: results of 49 patients. *J Hand Surg Am.* 2012;37(10):2088-2094.
4. Sabapathy SR, Bajantri B. Indications, selection, and use of distant pedicled flap for upper limb reconstruction. *Hand Clin.* 2014;30(2):185-199.
5. Boyd JB, Taylor GI, Corlett R. The vascular territories of the superior epigastric and the deep inferior epigastric systems. *Plast Reconstr Surg.* 1984;73(1):1e16.
6. Smith PJ. The Y-shaped hypogastric-groin flap. *Hand* 1982;14:263-70.
7. Choi JY, Chung KC. Combined use of a pedicled superficial inferior epigastric artery flap and a groin flap for reconstruction of a dorsal and volar handblast injury. *Hand* 2008;3:375-80.
8. Krishnamoorthy, R., & Karthikeyan, G. (2011). Degloving injuries of the hand. *Indian journal of plastic surgery: official publication of the Association of Plastic Surgeons of India*, 44(2), 227.
9. Al-Qattan MM, Al-Qattan AM. Defining the indications of pedicled groin and abdominal flaps in hand reconstruction in the current microsurgery era. *J Hand Surg Am* 2016;41(9):917-927.
10. Segu SS, Athavale SN, Manjunath P. Osteoplastic

reconstruction for post traumatic thumb amputations around metacarpophalangeal joint. *J Clin Diagn Res* 2015;9(8):PC11-PC13.

11. Boyd JB, Mackinnon SE. An evaluation of the pedicled thoracolumbar flap in upper extremity reconstruction. *Ann Plast Surg* 1989;22(3):236-242.

