

A Study on Clinico Pathological Features of Chronic Cholecystitis

Rashmi HK¹, Shivamurthy YL², Suresh KK³

¹Pathologist, Shri Mallikarjuna Diagnostic Laboratory, ²Paediatrician, Vatsalya Hospital, Chikkamagaluru, Karnataka 577101, India. ³Professor, Department of Pathology, JJM Medical College, Davangere, Karnataka 577004, India.

Corresponding Author:

Rashmi HK, Pathologist, Shri Mallikarjuna Diagnostic Laboratory, Chikkamagaluru, Karnataka 577101, India.

E-mail: hkrashmi30@gmail.com

Abstract

Introduction: In general, chronic cholecystitis associated with cholelithiasis features dense mural muscular hypertrophy and fibrosis, and usually only minimal chronic inflammation. Rokitansky-Aschoff sinuses are frequently identified; these represent diverticuli of gallbladder mucosa into the muscular layer, which are associated with focal mild muscular hypertrophy. **Methodology:** The study mainly included all cholecystectomy specimens received at the Department of Pathology. The patient's name, age, sex, parity, diet and clinical features were noted. Some of the cases had been diagnosed clinically and all cases had been subjected to ultrasound examination preoperatively. **Results:** Microscopically, 104 (57.1%) cases had normal mucosal lining, 38 (20.9%) had atrophied lining, 24 (13.2%) had ulcerated mucosa, 12 (6.6%) had hyperplastic lining and two each had necrosed mucosal lining (1.1%) and pyloric gland metaplasia (1.1%). **Conclusion:** Wall was infiltrated with lymphocytes, plasma cells, eosinophils and macrophages and showed fibrosis and congested blood vessel. Mild degree of inflammation was seen in 97 (53.3%), 59 (32.4%) had moderate and 26 (14.3%) had severe inflammation. Rokitansky Aschoff Sinuses was seen in all cases.

Key words: Chronic Cholecystitis; Rokitansky Aschoff Sinuses; Cholelithiasis.

How to cite this article:

Rashmi HK, Shivamurthy YL, Suresh KK/A Study on Clinico Pathological Features of Chronic Cholecystitis/Indian J Pathol Res Pract. 2021;10(1): 9-13.

Introduction

Chronic cholecystitis is rarely seen in the absence of lithiasis, although pure stones of the cholesterol and calcium bilirubinate types may be present without inflammation. Thickening of the wall is always present, sometimes to a striking degree. Occasionally this is associated with diffuse calcification, a condition known as 'porcelain

gallbladder'. In most instances, stones are of the mixed or combined type. Ulceration of the mucosa may result from pressure by the stones.¹

In general, chronic cholecystitis associated with cholelithiasis features dense mural muscular hypertrophy and fibrosis, and usually only minimal chronic inflammation. Rokitansky-Aschoff sinuses are frequently identified; these represent diverticuli



of gallbladder mucosa into the muscular layer, which are associated with focal mild muscular hypertrophy.²

Grossly, the gallbladder itself may appear nearly normal or show thickening of the wall. In more severe cases, the gallbladder may be shrunken, with marked fibrous thickening of the wall and serosal scarring associated with adhesions to adjacent organs. In addition, the mucosa may appear granular, ulcerated, or exhibit regenerative polypoid areas.

Microscopically, the epithelium may be atrophic, normal, focally ulcerated, metaplastic, or regenerative. Metaplastic changes are common; these are sometimes the main evidence that there is chronic cholecystitis. Diverticular changes, known as Aschoff-Rokitansky sinuses, are very common in chronic cholecystitis and are more prominent in more severe cases. Strictly speaking, these are pseudodiverticula, composed of deeply invaginating mucosa without a complete muscular coat. They form irregularly shaped, tubular structures in the wall of the gallbladder and may contain bile or calculi. In chronic cholecystitis these may display reactive epithelial atypia, which may be quite severe and may be mistaken for invasive carcinoma.

The degree of chronic inflammation varies and is composed predominantly of T lymphocytes along with some plasma cells, histiocytes, and occasional eosinophils. There is often thickening of gallbladder wall.³

Chronic inflammation was diagnosed in the presence of a predominantly mononuclear inflammatory infiltrate. Degree of inflammatory mononuclear infiltrate: mild (diffuse, not more than 10 inflammatory cells per high power field (HPF) in any layer), moderate (diffuse, between 11 to 30 cells per HPF) and severe (diffuse, more than 31 cells per HPF or follicular).⁴

Methodology

The study mainly included all cholecystectomy specimens received at the Department of Pathology. The patient's name, age, sex, parity, diet and clinical features were noted. Some of the cases had been diagnosed clinically and all cases had been subjected to ultrasound examination preoperatively.

Resected gallbladder specimens were sent either cut opened or intact in 10% formalin. Intact specimens were opened by longitudinal incision.

All specimens were examined grossly for the presence of stones, growths, polyps, ulceration, and other gross abnormalities. The size of the gallbladder, shape, external surface, wall thickness, and the nature of mucosa were noted. Chemical analysis of the gallstones was not done.

After studying the gross features, representative areas were sampled for histopathological examination. At least three tissue samples were taken from each specimen, so as to include tissue from fundus, body and neck of the gallbladder. Extra bits were taken from other representative areas like polyps, growth and other abnormal sites whenever necessary.

The tissue was processed routinely to obtain paraffin sections of 5 micron thickness. They were stained with haematoxylin and eosin for microscopy. Special stains like PAS and Alcian blue (Ph 2.5) were done wherever necessary.

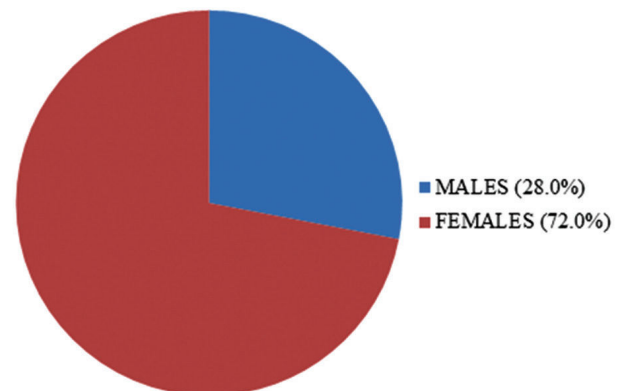
Sample Size: 220

Inclusion Criteria: All non-neoplastic and neoplastic epithelial lesions of the gallbladder.

Exclusion Criteria: Mesenchymal and Lymphoid neoplasms.

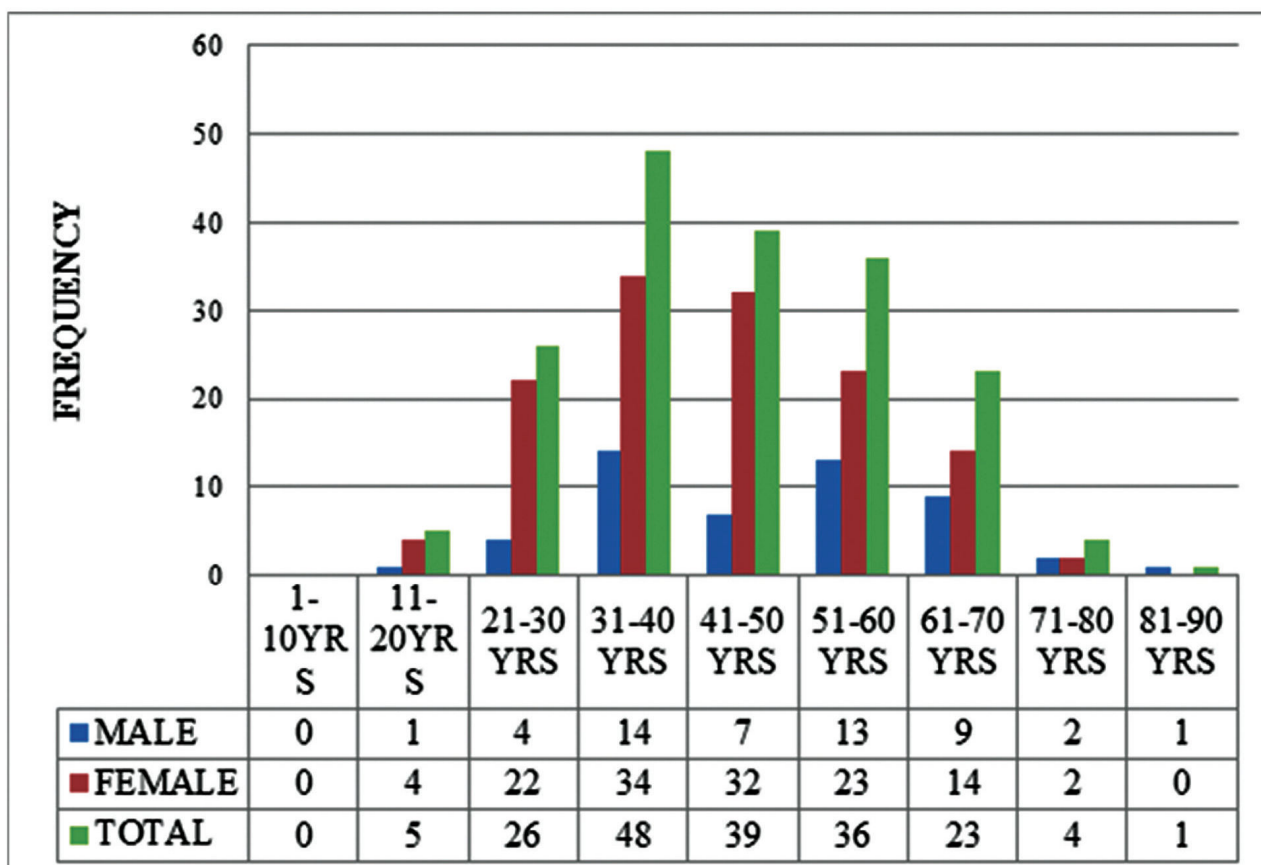
Results

In the present study, there were 182 cases of chronic cholecystitis of which 131 (72.0%) were females and 51 (28.0%) were males with Male to Female ratio being 1:2.56. (Graph 1).



Graph 1: Sex distribution in chronic cholecystitis.

Of the 183 cases, 48 patients were in the age group of 31-40 years followed by 39 patients in the age group of 41-50 years, 36 patients in the age group of 51-60 years, 26 patients in the age group of 21-30 years and 23 patients in the age group of 61-70 years. Median age of the patient was 44.06 years. (Graph 2)



Graph 2: Age Distribution of Males and Females in Chronic Cholecystitis.

All the 182 patients had pain abdomen as the presenting symptom, 57 had vomiting and seven had fever. All the patients underwent USG examination. USG examination revealed thickened gallbladder wall and hyperechoic foci in the gallbladder in calculus cholecystitis cases.

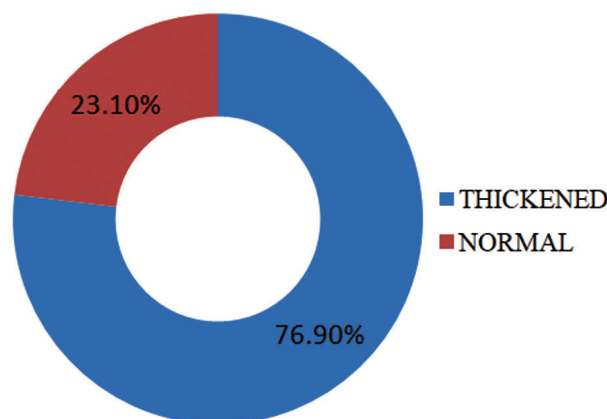
Grossly, thickened gallbladder wall was seen in 140 (76.9%) cases and the remaining 42 (23.1%) cases had normal wall thickness. (Graph 3) Gallstones were seen in 140 cases (76.9%) and the remaining 42 cases (23.1%) were acalculus. (Graph 4) Multiple stones were seen in 113 cases (80.7%) remaining 27 cases (19.3%) had single stone. (Graph 5)

Black pigment stones were seen in 57 (40.71%) cases, mixed stones in 55 (39.29%), combined stones in 24 (17.15%), brown pigment stones in 3(2.14%) and cholesterol stone in one case (0.71%).

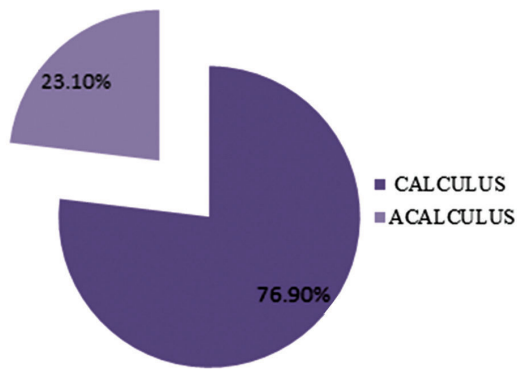
Microscopically, 104 (57.1%) cases had normal mucosal lining, 38 (20.9%) had atrophied lining, 24 (13.2%) had ulcerated mucosa, 12 (6.6%) had hyperplastic lining and two each had necrosed mucosal lining (1.1%) and pyloric gland metaplasia

(1.1%).(Graph 6)

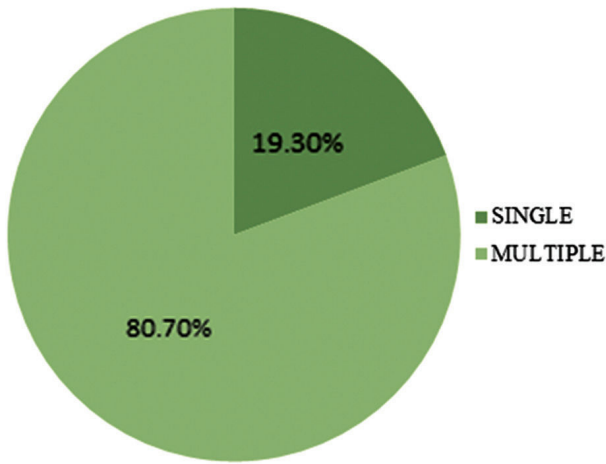
Wall was infiltrated with lymphocytes, plasma cells, eosinophils and macrophages and showed fibrosis and congested blood vessel. Mild degree of inflammation was seen in 97 (53.3%), 59 (32.4%) had moderate and 26 (14.3%) had severe inflammation. RokitanskyAschoff Sinuses was seen in all cases(Graph 7)



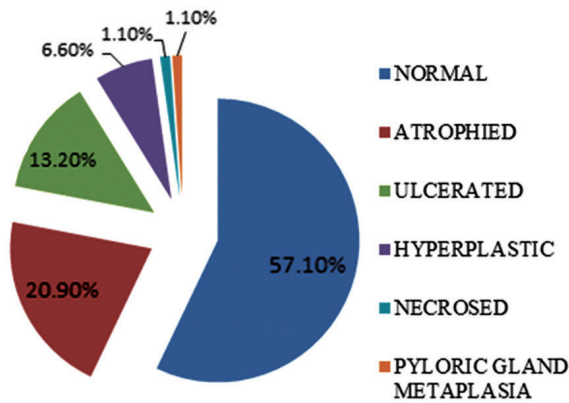
Graph 3: Wall thickness in chronic cholecystitis.



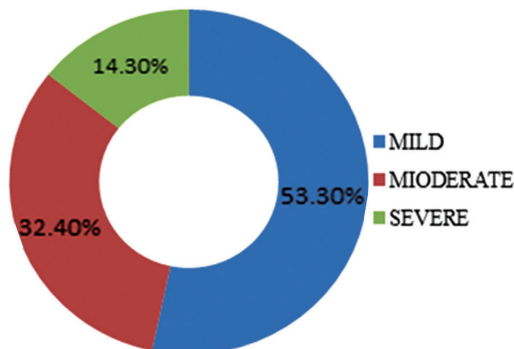
Graph 4: Frequency of gallstones in chronic cholecystitis.



Graph 5: Number of gallstones in chronic cholecystitis.



Graph 6: Mucosal changes in chronic cholecystitis.



Graph 7: Degree of inflammation in chronic cholecystitis.

Among 182 chronic cholecystitis cases, 130 cases were chronic calculus cholecystitis, 34 were chronic acalculuscholecystitis, ten were follicular cholecystitis, four were gangrenous cholecystitis, three were xanthogranulomatouscholecystitis and one was eosinophiliccholecystitis. (table 1)

Table 1: Variants of chronic cholecystitis.

Chronic Cholecystitis	Number	Percentage
Chronic calculus cholecystitis	130	71.4
Chronic acalculuscholecystitis	34	18.7
Follicular cholecystitis	10	5.5
Gangrenous cholecystitis	4	2.2
Xanthogranulomatouscholecystitis	3	1.65
Eosinophiliccholecystitis	1	0.55
Total	182	100.00

Discussion

In the present study, chronic cholecystitis was the commonest type of inflammation observed in 182(91.92%) cases. This finding was consistent with the study done by Stancu M et al who observed 92.8%, Hayes BD et al (91.12%) and Mohan N (87.5%) of the cases but was higher than those observed by Tyagi SP et al (50.8%) Gangoli AS (79.98%) and Zahrani IH et al (83.0%). (table 2)

Table 2: Comparison of chronic cholecystitis in various studies.

Authors and year	Observations
Tyagi SP et al (1992) ⁵	50.8%
Gangoli AS (1999) ⁶	79.98%
Zahrani IH et al (2001) ⁷	83.0%
Mohan N (2007) ⁸	87.5%
Stancu M et al(2007) ⁹	92.8%
Hayes BD et al (2014) ¹⁰	91.12%
Present study (2015)	91.92%

In the present study, 182 cases of chronic cholecystitis were diagnosed, of which 131 were females and 51 were males, giving a male to female ratio of 1:2.56. There was female preponderance. Similar female preponderance was observed by the following workers. (table 3)

Table 3: Comparison of sex distribution in chronic cholecystitis.

Authors and year	Male: Female
Tyagi SP et al (1992) ⁵	1:5.4
Gangoli AS (1999) ⁶	1:1.8
Mohan N (2007) ⁸	1:1.3
Present study (2015)	1:2.56

The findings in our study was higher than those observed by Gangoli AS (1999) and Mohan N (2007) but less than the findings observed by Tyagi SP et al (1992).

In the present study, of the 182 cases of chronic cholecystitis, majority of cases (48) belonged to the age group of 31-40 years, of which 14 were males and 34 were females. (table 4)

Table 4: Comparison of age distribution in chronic cholecystitis.

Authors and year	Most common age group in years
Gangoli AS (1999) ⁶	31-50
Mohan N (2007) ⁸	31-50
Present study(2015)	31-40

Chronic cholecystitis (182 cases) was graded as mild, moderate and severe based on number of inflammatory cells. The inflammatory response was mild in 97(53.3%), moderate in 59(32.4%) and severe in 26(14.3%) cases. The mild and severe inflammation was consistent with the study done by Hayes BD et al who observed mild in 407 (57.73%), moderate in 119 (16.88%), and severe in 79(11.21%) cases but varies from those observed by Tyagi SP et al, Gangoli AS and Mohan N.(table 5)

Table 5: Comparison of degree of inflammation in chronic cholecystitis.

Authors and Year	Mild	Moderate	Severe
Tyagi SP et al (1992) ⁵	19.4%	52.1%	28.5%
Gangoli AS (1999) ⁶	16.92%	59.98%	23.1%
Mohan N (2007) ⁸	7.9%	64.3%	27.8%
Hayes BD et al (2014) ¹⁰	57.73%	16.88%	11.21%
Present study (2015)	53.3%	32.4%	14.3%

Conclusion

- Chronic cholecystitis showed mild degree of inflammation in 97(53.3%), followed by moderate degree in 59(32.4%) and severe degree of inflammation in 26(14.3%)

- All cases of chronic cholecystitis had Rokitansky Aschoff Sinuses

References

- Meirelles-Costa AL, Bresciani CJ, Perez RO, Bresciani BH, Siqueira SA, Cecconello I. Are histological alterations observed in the gallbladder precancerous lesions? Clinics(Sao Paulo) 2010;65:143-50.
- Wernberg JA, Lucarelli DD. Gallbladder Cancer. SurgClin North Am 2014;94: 343-60.
- Flood TA, Jain D, Marginean EC. Malignant tumours of gallbladder and extrahepatic bile ducts. DiagnHistopathol 2010;16:360-70.
- Dursun N, Escalona OT, Roa JC, Basturk O, Bagci P, Cakir A et al. Mucinous carcinomas of the gallbladder: clinicopathologic analysis of 15 cases identified in 606 carcinomas. Arch Pathol Lab Med 2012;136:1347-58.
- Tyagi SP, Tyagi N, Maheshwari V, Ashraf SM, Sahoo P. Morphological changes in diseased Gallbladder: a study of 415 cholecystectomies at Aligarh. J Indian Med Assoc 1992;90:178-81.
- GangoliAS. Surgical Pathology of Gallbladder [Dissertation]. Shankaragatta: KuvempuUniversity; 1999.
- Zahrani IH, Mansoor I. Gallbladder pathologies and cholelithiasis. Saudi Med J 2001;22:885-9.
- Mohan N. A Histomorphological Study of Gallbladder [Dissertation]. Bengaluru: RajivGandhiUniversity of Health Sciences; 2007.
- Stancu M, Căruntu ID, Giuşcă S, Dobrescu G. Hyperplasia, metaplasia, dysplasia and neoplasia lesions in chronic cholecystitis- a morphologic study. Rom J MorpholEmbryol2007;48:335-42.
- Hayes BD, Muldoon C. Seek and ye shall find: the importance of careful macroscopic examination and thorough sampling in 2522 cholecystectomy specimens. Ann DiagnPathol 2014;18:181-6.

