

## Morphometric Study of Accessory Leaflet of Tricuspid Valve

Shruthi BN<sup>1</sup>, Dini Mathew<sup>2</sup>, Mangala S<sup>3</sup>

### How to cite this article:

Shruthi BN, Dini Mathew, Mangala S/Morphometric Study of Accessory Leaflet of Tricuspid Valve/Indian J Anat. 2021;10(3-4):87-90.

**Author's Affiliation:** <sup>1</sup>Professor & H O D, Department of Anatomy, Raja Rajeswari Medical College Kambipura, Bengaluru 560074, Karnataka, India, <sup>2</sup>Assistant Professor, Department of Anatomy, DM Wayanad Institute of Medical Sciences, Meppadi, Kerala 673577, India, <sup>3</sup>Professor, Department of Anatomy, Rajarajeswari Medical College, Bengaluru, 560074, Karnataka, India.

**Corresponding Author:** Dini Mathew, Assistant Professor, Department of Anatomy, DM Wayanad Institute of Medical Sciences, Meppadi, Kerala 673577, India.

**E-mail:** [dinimathew123@gmail.com](mailto:dinimathew123@gmail.com)

### Abstract

**Introduction:** The right atrioventricular orifice is guarded by the tricuspid valve comprising three leaflets, from which the name 'tricuspid' is derived. The variations in the structural orientation of the tricuspid leaflets as the occurrence of accessory leaflets poses a major problem during surgeries related to the tricuspid valve.

**Methods:** The study sample consists of 100 formalin fixed adult human heart available in the Department of Anatomy & department of Forensic Medicine of Rajarajeswari Medical College and Hospital, Bengaluru. The parameters were noted meticulously and the data processed.

**Results:** In this study, typical 3 leaflets were present in 42%, four leaflets in 42%, five leaflets in 13%, six leaflets in 2 % and seven leaflets in 1 % of heart specimens. 64.1 % accessory leaflets were present between posterior and septal leaflet, 24.3 % of accessory leaflet between anterior and posterior leaflet and in 11.53 % of accessory leaflets were present between septal and anterior leaflet. The length of accessory leaflet were found to be  $9.09 \pm 0.19$  mm.

**Conclusion:** On the basis of the result of the present study it is suggested that the typical three cuspidal leaflets of right atrioventricular valve is relatively uncommon with frequent occurrences of accessory leaflets. The multicuspidal form of the tricuspid

the valve raises the concern about understanding the functional and physiological significance of accessory leaflets

**Keywords:** Accessory leaflets; Tricuspid valve; Atrioventricular valve leaflets.

### Introduction

The right atrioventricular orifice is guarded by the tricuspid valve comprising three leaflets, from which the name 'tricuspid' is derived. The leaflets were considered to be the primary units of the tricuspid valve, separated from each other by a commissure. These leaflets are located septally, anterosuperiorly and inferiorly, corresponding to the marginal sector of the atrioventricular orifice.<sup>1</sup>

The leaflets of the tricuspid valve have been reported to show variability in their structural attachment, number and the occurrence of accessory leaflets. It has also been suggested that the number of leaflets in the tricuspid valve increases in an evolutionary line, but the rules of division for the main leaflet remain unknown.<sup>2</sup>

The complex three-dimensional structure of the tricuspid valve with the presence of accessory leaflets can pose a major problem during associated



surgeries and complications arising because of a discrepant morphological estimation of the tricuspid valve between the preoperative two-dimensional transthoracic echocardiography and direct surgical visualization have been reported.<sup>3</sup> The presence of accessory valve leaflets not only complicates surgeries as accessory valves are prone to prolapse.<sup>4</sup>

The variations in the structure and position of the main as well as accessory leaflets are relatively unexplored, especially in terms of the anatomical morphology and subsequent physiological functions.<sup>2</sup> Morphological studies, estimating the number of leaflets with their measurements can therefore be beneficial for the development of future methodological techniques. The aim of this study was to determine the number and localization of the accessory leaflets and to analyze their size by measuring the height of accessory leaflets.

### Materials and Methods

The study was carried out on 100 formalin fixed adult human hearts who had died of non-vascular causes & without any gross abnormality of the tricuspid valves available in the Department of Anatomy & Department of Forensic medicine in Rajarajeswari Medical College and Hospital, Bengaluru. Tricuspid valve complex was studied in Hearts of embalmed human cadaver. The cadavers were from South Indian adult population.

#### Steps of dissection of heart

The dissection was done by following the guidelines of Cunninghans manual.<sup>5</sup> The hearts were dissected with least destruction of valves after cleaning thoroughly under the tap water. The first incision was given from right aspect of inferior vena cava to the superior vena cava and the right atrium was opened. The second incision was given along the inferior border of the heart to the inferior margin of anterior interventricular groove i.e. along the acute margin of the heart. The third incision was made just right to the anterior interventricular groove. The walls were carefully retracted and the interior was thoroughly washed under running tap water to remove the clots. The accessory leaflets of the tricuspid valve was observed. Excessive water was soaked with a clean cotton cloth.<sup>6</sup>

#### Morphometric parameters observed were

- Number of leaflets
- Location of accessory leaflet
- Height of Accessory leaflet

Accessory leaflets were present between the

commissures and it was different from the scallop of the main leaflet. The commissure and depth of the indentation made by the chordae were well demarcated in the main leaflets<sup>2</sup>

**Measurements of the leaflet:** A vernier caliper (in millimeters) was used to measure the height 'h' of the accessory leaflets. The height 'h' of the leaflets was considered to be the minimum vertical distance of the commissure, which ranged from the attachments of the fan shaped chordae on the papillary muscles to the fibrous collagenous rim of the atrioventricular orifice.<sup>7</sup>

### Results

The number of leaflets of Tricuspid Valve ranged from 3 to 7. The most common leaflets were 3 cuspidal and 4 cuspidal forms with 42% of heart specimens studied. The 4 cuspidal forms of leaflets have 3 main and 1 accessory leaflet. 2 accessory leaflets constituting total 5 leaflets were present in 13% of heart specimens. Three accessory leaflets were present in 2% of heart specimens. The greatest number of leaflets found was 7 which existed in 1% of heart specimen.

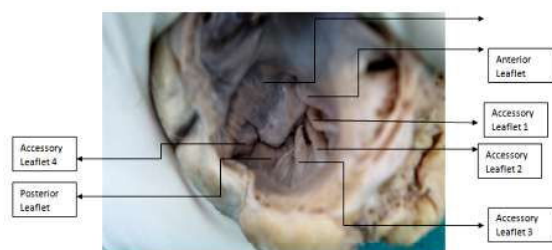
Depending on the location, the accessory leaflets were present between posterior and septal leaflet, septal and anterior leaflet and anterior and posterior leaflet.

In 50 Heart specimens Accessory leaflets were present in between posterior and septal leaflets. In 19 Hearts accessory leaflets were present in between anterior and posterior leaflets and 9 Hearts specimens accessory leaflets were present between septal and anterior leaflet. The most important observation was that the 'typical' form of the tricuspid valve with only three main leaflets was present only in 42% of cases studied.

The length of majority of accessory leaflet ranges from 5.6-10.5 cm constituting 78.5%. 1.3% of accessory leaflet length was less than 5.5 cm and 20.5% of accessory leaflet length was ranged from 10.6-15.5 cm.

**Table 1:** Frequency of occurrence of different types of tricuspid leaflets.

Number of leaflets	Number of specimens	Percentage of specimens
3	42	42
4	42	42
5	13	13
6	2	2
7	1	1



Photograph showing maximum number of leaflets

**Table 2:** Position of Accessory Leaflets PS-Posterior and Superior, SA-Septal and Anterior, AP-Anterior and Posterior.

Accessory leaflet	Frequency	Percentage (%)
PS	50	64.0
SA	9	12.0
AP	19	24.0

**Table 2:** Range of length of Accessory leaflet.

Range of measurements	Frequency	Percentage (%)
0.6-5.5	1	1.3
5.6-10.5	61	78.2
10.6-15.5	16	20.5

**Table 3:** Comparison of number of leaflets with other studies

Author	Number of leaflets(%)					Position of Accessory leaflets (%)			Length of Accessory leaflet (mm)
	Three	Four	Five	Six	Seven	AP	PS	SA	
Polly lama et al 2015 (n=120)	16.6	8.3	34.3	25	16.6	--	--	--	12.02±0.65
Mishra et al 2015 (n=36)	57.5	29.1	8.3	4.1	0.8	19.4	50	13.81	--
Present study 2016 (n=100)	42	42	13	2	1	24.3	64.1	11.53	9.09±0.19

probably due to less number of heart specimen studied.

The accessory leaflets were located anterior and posterior leaflet in 24.3%, between the posterior and septal in 64.1 % and between the septal and anterior in 11.53%. In another study conducted by Mishra et al 17 in 36 adult human tricuspid valve showed accessory leaflets were present between anterior and posterior in 19.4%, between posterior and septal in 50% and between the septal and anterior in 13.81%. The present study was consistent with the study conducted by Mishra et al.<sup>7</sup>

The mean height of accessory leaflet of present study was 9.09±0.19 mm and that of polly lama et al<sup>2</sup> was 12.02±0.65 mm. In another study conducted by krunal et al<sup>9</sup> the maximum length of accessory

## Discussion

During the development, mesenchymal cells of cardiac tube around the right and left atrioventricular canals proliferate to form collars of endocardial cushions. The early endocardial cushions serve as primitive valves that assist in the forward propulsion of blood through the heart. Later in development, thin leaflets of anatomical valves take shape in the atrioventricular canal. The definitive valve leaflets do not seem to come from endocardial cushion tissue as much as from invagination of superficial epicardially derived tissues of the atrioventricular groove. The valve that protects the right atrioventricular canal develops three leaflets (tricuspid valve), but the valve in the left canal (mitral, or bicuspid, valve) develops only two.<sup>8</sup>

This study shows the importance of morphological variation of Tricuspid valve leaflets. Most of the specimens studied showed a more than three leaflet form, while only 42% of the specimens examined showed the typical three tricuspid leaflets and it was consistent with the study conducted by polly lama et al<sup>2</sup> where as the study by mishra et al<sup>7</sup> showed more number of typical 3 cuspidal form

cusps was 15.60 mm.

## Conclusion

The emergence of accessory leaflets is of common occurrence and further studies on the mechanism behind the appearance of such accessory leaflets are required from developmental genetics, physiological, functional and clinical points of view.<sup>2</sup> Study of variations of atrioventricular valve is important for cardiosurgeons and interventional radiologists. From the above results it is concluded that this study will be helpful to the cardiovascular surgeons as there is little data available on morphometry of accessory leaflet of Tricuspid valve which can aid in the development of the bioprosthetic valves used for tricuspid repair.

**References**

1. Bannister LH, Berus MM, Collins P, Dyson M, Dusek JE, Ferguson MWJ. *Grays Anatomy*. 40th edition. Edinburgh: Churchill living stone. 2008; 1769-1787.
2. Polly Lama, Binod Kumar Tamang, Jyoti Kulkarni. "Morphometry and aberrant morphology of the adult human tricuspid valve leaflets", *Anat Sci Int*;2016, 143-150.
3. Ashraf M Anwar, Marcel L Geleijnse, Folkert J ten Cate, Folkert J Meijboom. "Assessment of tricuspid valve annulus size, shape and function using real-time three dimensional echocardiography", *Interactive Cardio Vascular and Thoracic Surgery*; 2006, vol5: 683-687.
4. Andrew Yoon, Hussein Shaqra, Miles Levin, Barry Rudin, Jonathan N. Bella, M. "Accessory Tricuspid Valve Leaflet in an Asymptomatic Adult", *Texas Heart Institute Journal*; 2008, Vol 35: 327-328.
5. G.J.Romanes. "Cunningham's Manual of Practical Anatomy", 15th edition. Oxford: Newyork. 2010; 53-54.
6. MSkwarek, JHreczecha, MDudziak, JJerzemowski, M Szpinda, M Grzybiak. "Morphometric features of the right atrioventricular orifice in adult human hearts", *Folia Morphol*; Jan 2008, Vol. 67:53-57.
7. Parmatma P Mishra, Manvikar Purushottam Rao, Vaishali Paranjape, Jyoti P. Kulkarni. "Variations in the Shape of Atrioventricular Cusps", *heartindia*; Jun 2015, Vol 3 :39-42.
8. Bruce M. Carlson. *Human Embryology and Developmental Biology*. 5th Edition. Ann Arbor, Saunders.2014:894-907.
9. Krunal R Chauhan, Alka Udainia, C D Mehta, Kinnari Chavda. "Study of incidence of an abnormal tricuspid valve in the human cadaveric heart", *National Journal of Medical Research*; Sept 2014, Volume 4: 238-240.

