

Cystic Lesions of Bone: Challenges in Diagnosis and Management

Jayasree P V¹, Arun Geothe²

How to cite this article:

Jayasree P V, Arun Geothe/Cystic Lesions of Bone: Challenges in Diagnosis and Management/Indian J Canc Educ Res 2022;10(2):87-90.

Abstract

Cystic lesion of bone can occur in any bone at any age/sex. and often are asymptomatic or may easily be confused with other bone lesions. Many of them typically resolve after skeletal maturity but some can result in pathologic fractures or local recurrence. In some lesions the danger of biopsy or other surgery may outweigh any benefit. So precise diagnosis is needed to prevent over/under treatment of lesions.

Keywords: Cyst of bone; Simple bone cyst; Aneurismal bone cyst; Intra-osseous ganglion cyst; Subchondral cyst.

Key Message: Not all bone cysts require treatment, in some lesions the danger of biopsy or other surgery may outweigh any benefit as they are painful/ fast growing / large /cause a fracture. Specific treatments are determined based on size of the cyst, strength of the bone, medical history, extent of the disease, activity level and the symptoms an individual is experiencing, and tolerance for specific medications, procedures, or therapies.

INTRODUCTION

Bone cysts are fluid-filled cavities with a connective tissue lining and varying numbers of septae.

Patients with cystic bone lesions may present with swelling / limitation of joint movements / neurological deficit or as an incidental finding. Development of pain may indicate that the lesion may be developing a stress fracture and needs urgent treatment.

Cystic lesions include Simple bone cyst (SBC), Aneurismal bone cyst (ABC), Intraosseous

ganglion cyst (GC), Subchondral cyst (SUBCC), Epidermoid cyst, Hydatid cyst, Brown tumor of hyper parathyroidism, Hemophilic pseudotumor, Bone abscess, Cystic tuberculosis etc¹. Most of them present as radiolucent lytic lesions with a long diverse list of differential diagnosis ranging from indolent non ossifying fibroma (NOF) to benign chondromyxoid fibroma (CMF) to aggressive telangiectatic osteosarcoma (OS). Ancillary radiological investigations will help in the further differentiation. Computed tomography (CT) helps in analysis of lytic solid/ cystic lesions. MRI (Magnetic Resonance Imaging) is useful to detect fluid content of the cyst / fluid-fluid levels of ABC^{2,3}

Because of the multiplicity of conditions which produce cystic lesions of bone, it is obviously important to make an early diagnosis so that the patient may receive adequate treatment.⁴ Diagnostic features & behavior are outlined in the Table 1. Miscellaneous cystic lesions like Bone abscess, intra osseous lipoma & medullary bone infarct have characteristic radiological and pathological findings. Multifocality of lesions, as well as associated hypercalcemia / hyperphosphatemia,/

Author Affiliation: ¹Professor, Department of Pathology, Sree Mookambika Institute of Medical Sciences, Kanyakumari 629161, Tamil Nadu, India, ²CCU Registrar, SUT Hospital, Pattom, Trivandrum 695004, Kerala, India.

Corresponding Author: Jayasree P V, Professor, Department of Pathology, Sree Mookambika Institute of Medical Sciences, Kanyakumari 629161, Tamil Nadu, India.

E-mail: jayageothe@gmail.com

Received on: 26.01.2022

Accepted on: 28.02.2022

renal disorder helps in diagnosis of brown tumor of hyper parathyroidism.

The lack of communication between the cystic defect and the joint cavity, together with the absence of arthritic change, distinguishes ganglion cyst from the marginal cysts and subchondral bone cysts which is commonly associated with degenerative joint disease Solid ABC or Giant cell reparative granuloma (GCRG) usually involves the maxilla, mandible, short tubular bones of hands and feet, will have a sclerotic margin, thin but characteristically intact cortex & absent periosteal reaction.³ Histologically, its close differential diagnosis (DD) is Giant cell tumor of bone (GCT), which will have dual population of mononuclear stromal cells & uniformly distributed. Larger giant cells having similar nuclear features GCT exhibit lesser degree of fibrosis, osteoid formation

and mineralization of the matrix than solid ABC. Multidisciplinary approach with clinico radiopathological correlation is absolutely needed in making final diagnosis as was done in the case of a fibrous dysplasia femur in 30 yrs old lady with chronic hip pain.

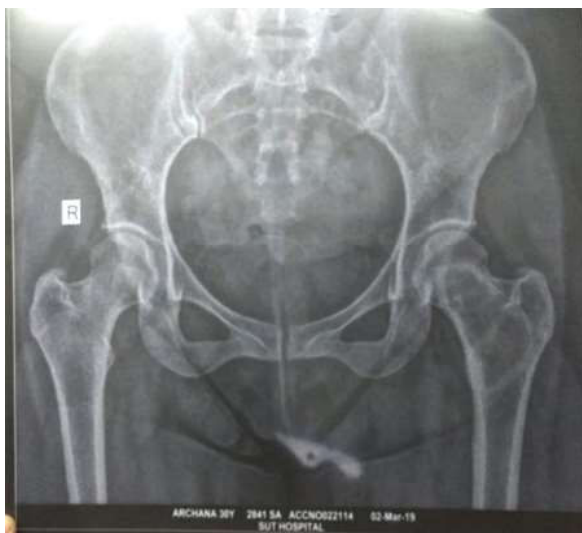

Fig. 1: X-Ray Pelvis AP-view. Well defined lytic lesion of left femoral neck with sclerotic borders and endosteal scalloping.

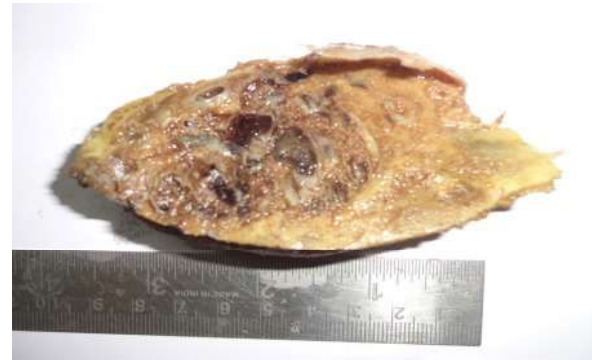


Fig. 2: Gross specimen - Resected bony hard lesion with multiple cystic areas containing hemorrhagic fluid.

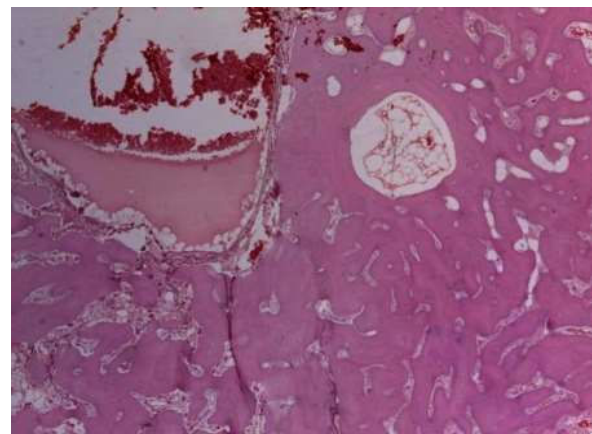


Fig. 3: Microscopy showing anastomosing irregular trabeculae of woven bone with pseudocyst lined by spindly cells and osteoclasts, H & E Stain

Table 1: Characteristic features of few cystic lesions of bone

Lesion	SBC	ABC	Ganglion cyst & Subchondral cyst	Epidermoid cyst	Cystic echinococcosis
Age/	<20 yrs	<30yrs	for GC=40yrs	More in males	
Sex	M:F 2:1	females	for SUBCC=>50yrs		
Common site/ location	Long bones proximal humerus, femur meta/ diaphysis	Distal femur proximal tibia, spine, pelvis meta = diaphysis GCRG (so-called solid ABC)	Tibia medial malleolus, femur, ulna, hands and feet = epiphysis subchondral	Skull bones & terminal phalanges of hand /toes	Flat bones vertebra, pelvis and mandible epiphysis
Etiology	Focal cessation of medullary bone formation	Trauma / tumor-induced anomalous vascular process	GC -> unknown SUB CC= with osteoarthritis	Congenital / traumatic implantation	Echinococustape worm's larval cystic stage

Radiology & Differential diagnosis	Central fusiform expansion with intact cortex fallen fragments sign DD: ABC, BrownTr, NOF, FD,	solitary, expansile eccentric multiloculated lesion breached cortex, buttress of solid periosteal response MRI: lobulated & fluid-fluid levels DD SBC GCT, CMF, NOF, OS	Eccentric, oval to round, well-defined peripheral trabeculated lytic lesion thin sclerotic rim.	Sharply outlined, lytic areas with a sclerotic border	4 different types single or multiple, uni or multiloculated, and thin- or thick calcified wall MRI: typical DD:tuberculosis, metastases and GCT
Gross	Yellowish fluid	Friable spongy hemorrhagic mass	Clear, gelatinous fluid.		Pearly white smooth surfaced cyst.
Micro & DD	Thin layer of fibrous tissue with collagen / cementum-like substance DD: ABC	Richly vascular fibrous septa with iron pigment, mitosis, clustered small osteoclasts DD; GCT, OS, hemophilic psuedotumor	focal areas of mucoid degeneration and patchy dense collagen.	Characteristic keratin filled cyst lined by squamous epithelium.	classical three layered cyst with brood capsules & scolices=hydatid sand
Comments	cholesterol clefts, giant cell reaction secondary to intracystic hemorrhage can mimic ABC	33% as solid ABC having expanded fibrous septa . 33 % are secondary to GCT / chondroblastoma/ fibrous dysplasia/ CMF / osteoblastoma/ OS /chondro/fibro sarcoma	Usually incidental MRI diagnostic	The radiology DDs: enchondroma GCRG, acral metastases, subungual melanoma	if the cysts were to rupture while in the body, the patient would go into anaphylactic shock
Prognosis	spontaneous regression in most . Rarely growth disturbances Recurrence =10-20%.	intermediate, locally aggressive neoplasm Local recurrence rate Up to 30% USP6 rearrangement of spindle cells used to differentiate primary & solid ABC from the secondary ABC	Very low rate of recurrence. Curettage if symptomatic;	Total removal of these cysts + washing of the cavity with 0.9% saline may prevent recurrence	Antibody detection by Casoni test, haemagglutination test or Antigen detection also an adjunct

SBC - Solitary Bone Cyst

ABC - Aneurysmal Bone cyst

GC - Ganglion Cyst

SUBCC - Subchondral Cyst

NOF - Non Ossifying Fibroma

GCT - Giant Cell Tumor

OS - Osteo sarcoma

GCRG - Giant cell Reparative Granuloma

CMF - ChondroMyxo Fibroma

FD - Fibrous Dysplasia

DD - Differential diagnosis

MANAGEMENT

Not all cysts require treatment in some lesions the danger of biopsy or other surgery may outweigh any benefit unless they are painful/ fast growing / large /cause a fracture Specific treatments are determined based on size of the cyst, strength of the bone, medical history, extent of the disease, activity level and the symptoms an individual is experiencing, and tolerance for specific medications, procedures, or therapies

Surgical options of aspiration with or without steroid infiltration are suitable for symptomatic simple bone cyst - If aspiration yields blood. It is more likely an ABC and recurrence likely so Burr the walls with a high speed burr until all tumor got removed Adjunctive ablation of surviving tumor cells is required in aggressive lesions with Cryosurgery, Phenol or filled with bone graft either autogenous or allograft. Block excision reserved for expendable bones e.g. ABC in shaft of fibula. Or the higher grade lesion e.g. giant cell tumor of the

proximal tibia. The whole of the involved bone can be excised and the defect replaced either with an arthrodesis, or custom made prosthesis. A variety of other different therapeutic options are available in selected patients including percutaneous injections, arterial embolization, radiation therapy and drug therapy using osteoclast inhibiting drugs such as bisphosphonate or denosumab.⁵

CONCLUSION

An early and precise diagnosis remains the key to tackling this condition. With the current trend of multidisciplinary diagnostic approach and advancements in therapeutic techniques, the future of management and treatment of bone cysts looks bright and promising.

REFERENCES

1. James W. Toumey. Differential Diagnosis of

Cystic Lesions of Bone Surgical Clinics of North America Volume 27, Issue 3, June 1947, Pages 737-754.

2. Kransdorf MJ, Sweet DE Aneurysmal bone cyst: concept, controversy, clinical presentation, and imaging AJR Am J Roentgenol. 1995 Mar; 164(3):573-80.
3. Ilaşlan H, Sundaram M, Unni KK, .Solid variant of aneurysmal bone cysts in long tubular bones: giant cell reparative granuloma.AJR Am J Roentgenol. 2003 Jun;180(6):1681-7.
4. Doğanavşargil B, Ayhan E, Argin M, Pehlivanoglu B, Keçeci B, Sezak M, Başdemir G, Öztop F Cystic bone lesions: histopathological spectrum and diagnostic challenges Turk PatolojiDerg. 2015;31(2):95-103.
5. H. W. B. Schreuder, R. P. H. Veth, M. Pruszczynski, J. A. M. Lemmens, H. S. Koops, and W. M. Molenaar, "Aneurysmal bone cysts treated by curettage, cryotherapy and bone grafting," Journal of Bone and Joint Surgery. British volume, vol. 79, no. 1, pp. 20-25, 1997.

