

## Morphometric Study on Mastoid Process for Determination of Sex by Using 3D CT Scan

MY Dofe<sup>1</sup>, KS Nemade<sup>2</sup>, NY kamadi<sup>3</sup>

### How to cite this article:

MY Dofe, KS Nemade, NY kamadi. Morphometric Study on Mastoid Process for Determination of Sex by Using 3D CT Scan. Indian J Anat. 2020;9(1):85-89.

**Author's Affiliation:** <sup>1</sup>Associate Professor <sup>2</sup>Associate Professor <sup>3</sup>Professor and Head, Department of Anatomy, Government Medical College, Nagpur, Maharashtra 440003, India.

**Corresponding Author:** Dr KS Nemade, Associate Professor, Department of Anatomy, Government Medical College, Nagpur, Maharashtra 440003, India.

E-mail: [knkirti84@gmail.com](mailto:knkirti84@gmail.com)

Received 28.11.2019 | Accepted 03.01.2020

### Abstract

**Objective:** The purpose of this study was to evaluate the accuracy of sex determination from the measurement of the area formed by 3 craniometric points related to the mastoid process i.e the porion, asterion, and mastoidale points in 3D reconstructed computed tomography of skull and comparison of its finding with the studies done by other authors where morphometric analysis of mastoid process is done by manual method using vernier caliper or xerographic copies of skull or from CT Scan.

**Method:** For the study, 200 3D reconstructed CT scan images of skull were analysed, 100 were males and 100 were females. The three craniometric points were marked to demarcate a triangle on both side of 3D skull and measurement was done by using Radiant Dicom software.

**Results:** We observed that the mean of all mastoid parameters was more in male than in female. Even the surface area of mastoid process was higher in male than female. Results of present study compared with studies done by different workers in different regions. Each study showed that all the mastoid variables i.e distance from Porion to Mastoidale, Asterion to Mastoidale, Asterion to Porion and surface area of mastoid process were more in males than in females which correlates with our study.

**Conclusion:** Knowledge of above dimensions of mastoid process and comparison of its findings with various methods of measurement increases the accuracy of sex determination.

**Keywords:** Mastoid process; Sex determination.

### Introduction

Determination of sex in fragmented bone is often a difficult task. The highest accuracy in sex determination is achieved when complete skeleton is available.<sup>1</sup>

Sex classification is more precise in pelvic remains than the skull but whole and complete pelvis is not always available for analysis.<sup>2</sup> Several studies have shown that cranium is also best indicator for sexual dimorphism by morphologic and morphometric analysis. Skull is probably the second best region of the skeleton to determine sex.<sup>3</sup> Dimorphism in skull is based on its size and robustness. The mastoid region is favorable for sex determination, as it is the most protected region and resistant to damage, due to its anatomical position at the base of skull.<sup>4</sup>

Sex determination from mastoid process is done metrically and non-metrically. Broca's (1875) and Hoshi (1921) have suggested that when the skull were placed on flat surface the male skull rests on mastoid process while female skull rests on occipital condyles.<sup>5</sup> Subsequently trends changed to morphometric and statistical methods. Mastoid process is examined metrically by various authors. Suazo et al. (2008) determine the sex on Brazilian skull by taking triangular area formed by the points



porion, mastoidale, and asterion with the help of statistical analysis and discriminant functional analysis.<sup>6</sup> Some authors used some variable like mastoid length, breadth and width of mastoid process to determine the sex.

Determination of sex using mastoid variables was done by various methods like manual method using vernier caliper, xerographic copies and CT images. Most of the studies used manual method. very few studies are done using CT scans. So, the present study is undertaken to determine the sex from morphometric measurement of mastoid process by using 3(D) CT scans of skull and it's findings were compared with previous studies. So the aim of this study is also to find out any discrimination in sexing of skull by using CT scans and other method.

### Materials and Methods

The present study is conducted in the Department of Anatomy, Government Medical College, Nagpur. Computerised tomographic images of 100 males and 100 females of age above 25 years were obtained from Radiology department. From this data 3D images of skull were reconstructed by using Radiant Dicom software. These 3D images were studied to determine the accuracy of mastoid process in sex determination. For mastoid measurement, three craniometric points were used. These are porion, asterion and mastoidale. Porion is superior point of external acoustic meatus. Asterion is the meeting point of lamboid, occipitomastoid and parietomastoid sutures. Mastoidale is the tip of mastoid process.

These three points were located and marked The following readings were taken in cm. i.e shown in Figure 1.

- Porion to Mastoidale
- Asterion to Mastoidale
- Porion to Asterion

Figure 1. Showing demarcation of three craniometric point.

For better comparison with previous studies readings in cm were converted in millimeter. The area of mastoid triangle was calculated by means of Herons formula.

All the mastoid variables were analysed by using software. The mean, standard deviation and *p* value were calculated and if "P" value less than 0.05 were consider to be stastastically significant difference between sexes.

### Results

Total 200 CT images of skull were taken (100 male, 100 female). The univariate analysis shown in Table 1, Table 2, Table 3 and Table 4. Table 1 showed analysis of male skulls of right and left side where all the mastoid variables were insignificant except the distance from Asterion to Mastoidale (*p* valve less than 0.05).

Table 2 showed analysis of female skull of right and left side where all the mastoid variables shows significant differences with *p* value less than 0.05 except the distance from Porion to Mastoidale.

Table 3 showed comparison of right sided mastoid parameters between male and female and Table 4. Showed comparison of left sided parameters between male and female. All the differences were highly significant with *p* valve less than 0.001 when male right side compared with female right side as well as when male left side compared with female left side which indicate that the measurement of these mastoid variables can be used for sex determination.

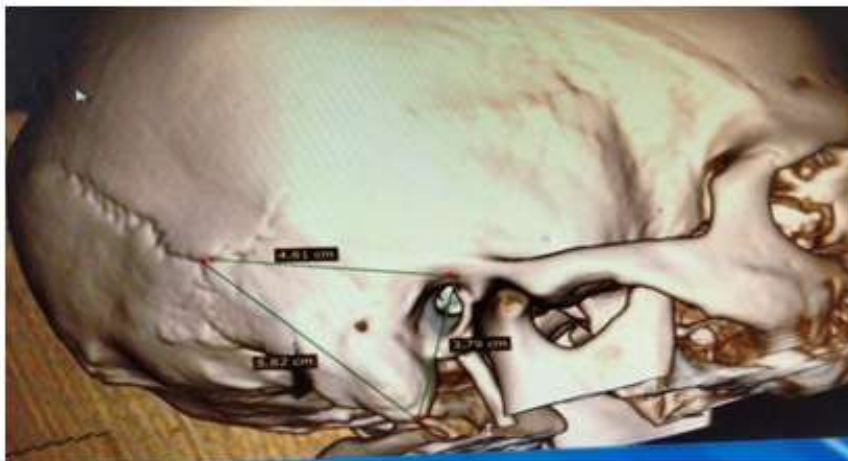


Fig. 1:

**Table 1:** Measurements of Mastoid variables in Male

Sr. No	Mastoid variable		Mean	SD	T test	p
1	Porion - Mastoidale	Right	31.04 mm	3.28	1.2072	0.2302
		Left	30.71 mm	3.78		
2	Asterion - Mastoidale	Right	47.04 mm	6.29	5.7028	<0.001*
		Left	45.10 mm	6.14		
3	Porion - Asterion	Right	42.98 mm	4.92	1.6378	0.1046
		Left	42.45 mm	4.78		
4	Surface area	Right	645.49 mm <sup>2</sup>	123.07	1.4210	0.1585
		Left	631.45 mm <sup>2</sup>	145.92		

**Table 2:** Measurements of Mastoid variable in Female

Sr. No	Mastoid variable		Female Mean	SD	T test	p
1	Porion - Mastoidale	Right	27.38 mm	4.57	0.760	0.445
		Left	27.14 mm	3.23		
2	Asterion - Mastoidale	Right	40.53 mm	7.48	3.894	0.0002*
		Left	38.7 mm	6.84		
3	Porion - Asterion	Right	39.02 mm	5.56	2.9078	0.0045*
		Left	37.96 mm	4.63		
4	Surface area	Right	505.75 mm <sup>2</sup>	132.41	3.905	0.001*
		Left	477.78 mm <sup>2</sup>	97.25		

**Table 3:** Showing comparson of mastoid variables in male and female of right side

Sr. No	Mastoid variable		Mean	SD	T test	p
1	Porion - Mastoidale	Male	31.04 mm	3.28	6.503	<0.001**
		Female	27.38 mm	4.57		
2	Asterion - Mastoidale	Male	47.04 mm	6.29	6.6496	<0.001**
		Female	40.53 mm	7.48		
3	Porion - Asterion	Male	42.98 mm	4.92	5.3371	<0.001**
		Female	39.02 mm	5.56		
4	Surface area	Male	645.49 mm <sup>2</sup>	123.07	7.729	<0.001**
		Female	505.75 mm <sup>2</sup>	132.41		

**Table 4:** Showing comparson of mastoid variables in male and female of left side

Sr. No	Mastoid variable		Mean	SD	T test	p
1	Porion - Mastoidale	Male	30.71 mm	3.78	7.1679	<0.001**
		Female	27.14 mm	3.23		
2	Asterion - Mastoidale	Male	45.10 mm	6.14	6.9593	<0.001**
		Female	38.7 mm	6.84		
3	Porion - Asterion	Male	42.45 mm	4.78	6.6379	<0.001**
		Female	37.96 mm	4.63		
4	Surface area	Male	631.45 mm <sup>2</sup>	145.92	8.7628	<0.001**
		Female	477.78 mm <sup>2</sup>	97.25		

\*--significant

\*\*--Highly significant

## Discussion

Present study was undertaken on morphometric measurement of mastoid process by using CT images and its findings were compared with the studies done by other authors using various methods. We found that the mean value of all mastoid variables i.e Porion to mastoidale; Asterion to mastoidale; Porion to Asterion and surface area of mastoid process was higher in males than in females on both right and left side of skulls which correlates with other studies.

In the present study we also found that the mean value of mastoid variables of right side was higher than left side in both male and female.

Table 5 shows the findings of study of various mastoid parameters done by different workers in different regions. Each study showed that all the mastoid variables were higher in male.

In 2003, Saavedra de Paiva and Segre<sup>4</sup> affirmed that the value of mastoid triangular areas defined by three distinct craniometric landmarks (Porion,

Asterion and mastoidale) were useful in sexing the skull. They used xerographic copies of skulls and they found significant difference in the area between mastoid triangle while comparing male and female skull. Because of asymmetrical measurements of mastoid triangle on right and left sides they recommended that the value of the total area (adding right and left sides) should be used for the inference. When this area was higher or equal to 1444.40 mm<sup>2</sup>, the skull was recongnised as male and when total area was lower than or equal to 1260.36 mm<sup>2</sup> skull was recongnised as female.

In present study, in CT images of male, surface area of mastoid triangle of right side is 645 mm<sup>2</sup> and 631 mm<sup>2</sup> on left side and the value of total area (adding of right and left sides) is 1276 mm<sup>2</sup> while in female surface area of mastoid triangle on right side is 505 mm<sup>2</sup> and on left side is 477 mm<sup>2</sup> and total area (adding right and left sides) is 982 mm<sup>2</sup>. This also shows that surface area was higher in male than in female.

Kemkes and Gobel<sup>12</sup> have hypothesized that population specific variability of the asterion

**Table 5:** Comparison between present study and studies conducted by previous workers for measurement (Porion to mastoidale; Asterion to mastoidale; Porion to Asterion and surface area).

Authors Manual Method	Population studied	No of skull	Po-Ms	AST-Ms	AST-Po	Surface area
Vineeta Saini et al. (2012) <sup>7</sup>	North India	M-104 F-34	M = 31.77 + 3.07 F = 27.98 + 3.47	M = 47.83 + 4.06 F = 43.0 + 4.32	M = 47.89 + 3.17 F = 44.69 + 3.75	
Nidugala H (2013) <sup>8</sup>	South India	M = 40 F = 40	M = 29.52 + 3.3 F = 24.26 + 3.7	M = 50.11 + 4.54 F = 46.51 + 4.12	M = 44.48 + 4.14 F = 42.87 + 3.08	
Albin Babu M Wilson (2013) <sup>9</sup>	South India	M = 40 F = 40				M=805.87 mm <sup>2</sup> F=620.56 mm <sup>2</sup>
SB sukare et al. (2017) <sup>10</sup>	Marathwada (Maharashtra)	M = 80 F = 52	M = 29.86 + 0.41 F = 25.17 + 0.69	M = 48.33 + 0.64 F = 42.59 + 1.12	M = 44.96 + 0.57 F = 40.46 + 1.03	
PR Chavan, SL Sarda et al. (2018) <sup>11</sup>	Marathwada (Maharashtra)	M = 80  F = 52	R-30.32 L-29.40  R-27.12 L-23.23	R-48.92 L-47.75  R-45.38 L-39.80	R-45.82 L-44.10  R-43.30 L-37.61	586.05 mm <sup>2</sup> 565.30 mm <sup>2</sup> 508.47 mm <sup>2</sup> 436.37 mm <sup>2</sup>
Authors Xerographic Copy Pavia and Segre (2003) <sup>4</sup>						M=1447.40 mm <sup>2</sup> F=1260.36 mm <sup>2</sup> Surface area of addition of both side
Author 3(D) CT scan Albin Babu M Wilson (2013) <sup>9</sup>	South India	M = 40 F = 40				M=828.53 mm <sup>2</sup> F=578.24 mm <sup>2</sup> Readings of one side. side not determined
Present study	Central India	M = 100  F = 100	R-31.04 mm L-30.71 mm R-27.38 mm L-27.14 mm	R-47.04 mm L-45.10 mm R-40.53 mm L-38.7 mm	R-42.98 mm L-42.45 mm R-39.02 mm L-37.96 mm	R-645 mm <sup>2</sup> L-631 mm <sup>2</sup> R-505 mm <sup>2</sup> L-477 mm <sup>2</sup>

location undermine the value of the mastoid triangle as a sex determinant.

In 2003 Albin Babu M Wilson et al.<sup>9</sup> did the comparison between 3(D) CT scan and manual method of area measurement of mastoid process in sex determination of south Indian population to find out any significant difference between CT scan method measurement and manual method measurement of mastoid process in sex determination in south Indian Population. They found that on CT measurement, the area of single side in male is  $828.53 \pm 18.54 \text{ mm}^2$  and in female  $578.24 \pm 71.53 \text{ mm}^2$  while the area measured by manual method is  $805.87 \pm 90.99 \text{ mm}^2$  in male and  $620.56 \pm 90.63 \text{ mm}^2$  in female on single side. The side of measurement were not mentioned and they found that there was no significant difference in measurements taken by CT scan and manual method.

In present study, measurements of mastoid triangle were taken of both right and left side on CT images and mean of surface area was more on right side than left in both male and female.

### Conclusion

Very few works were done on mastoid process by using 3D CT films to sex the skull. So the present study has provided a baseline data for sex determination of mastoid process of skull and on comparison with other studies, we found there is no discrimination in sexing of skull by using any method. The range of value for sexing the skull may be varies due racial difference or population based position of asterion.

More research on same parameters using various method of measurement increases the accuracy of sex determination.

Conclusion of the study knowledge of above dimensions of mastoid process and comparison its finding with various methods of measurements increases the accuracy of sex determination.

### References

1. Krogmm WM. The human skeletal in forensic medicine. Spring field II Charles C. Thomas 1962.
2. Phrenic TW. A newly developed visual method of sexing the os pubis. American Journal of Physical Anthropology 1969;30:297-301.
3. Bass WM. Human Osteology A Laboratory Field Manual of the Human Skeleton. Special Publications of the Missouri Archaeological Society Columbia 1971.
4. Saavedra de Paiva La, Segre M. Sexing the human skull through the mastoid process. Rev Hosp Clin Fac MedSao Paulo 2003 Jan-feb.53(1):15-20.
5. Hoshi H. Sex difference in shape of the mastoid process in normal occipitalis and its importance to the sex determination of human skull. Okajimas Folia Anat Jpn. 1962 Oct;38:309-13.
6. Suazo GIC. Zavando. MDA, Smith R. Sex determination using mastoid process measurement in Braillian Skull. Int.J Morphology 2008;26(4):941-44.
7. Vineeta S. Rashmi S et al. Sex Estimation from the mastoid process among North Indians. J Forensic Sci. 2012 Mar;57(2):434-9.
8. Nidugala H, Avadhani R Bhaskar B. Mastoid process. A tool for sex determination an anatomical Study in South India skull. International J. Boimed Res 2013;04(02):106-10.
9. Albin Babu M Wilson et al. Comparison Between CT scan and manual method of area measurement of mastoid process in sex determination of south population, International Journal of Pharmacy and Biological Sciences 2013;3(1):536-39.
10. SB Sukare et al., Morphometric analysis of mastoid process for sex determination among Marathwada population. International Journal of Anatomy Feb 2013;1(2):27-32.
11. PR Chavan, SL Sarada et al., Metric Study of Mastoid Triangle For Sexual Dimorphism. Indian Journal of Anatomy. Jan-Feb 2018;7:41-44.
12. Kemkes A, Gobel T. Metric assessment of the "mastoid triangle" for sex determination: a validation study. J Forensic Sci 2006 Sep;51(5):985-9.