

Congenital Dengue Masquerading as Neonatal Sepsis in a Baby with Previously Undiagnosed Febrile Mother

Manoj Bhatnagar¹, Minal Ambade², Satish Dudhbhate³, Faraz Mohammed Ashfaque⁴

How to cite this article:

Manoj Bhatnagar, Minal Ambade, Satish Dudhbhate, Faraz Mohammed Ashfaque, Congenital Dengue Masquerading as Neonatal Sepsis in a Baby with Previously Undiagnosed Febrile Mother. Indian J Matern Fetal Neonatal Med. 2021;8(2): 71–13.

Author's Affiliations: ¹Associate professor, ²Senior Resident, ^{3,4}Student, Department of Pediatrics, Government Medical College, Medical Chowk, Ajni, Nagpur, Maharashtra 440003, India.

Corresponding Author: Satish Dudhbhate, Student, Department of pediatrics, Government Medical College, Medical Chowk, Ajni, Nagpur, Maharashtra 440003, India.

Email: manojbhatnagar76@gmail.com

Abstract

Congenital dengue is rare. The prevalence of this entity is described recently. We hereby present a case report of a neonate who was previously thought to be a heart disease, later found out to be congenital dengue, the patient underwent intensive care and later discharged on improvement. The objective of this case report is to highlight the unusual presentation of congenital dengue in a neonate.

Keywords: Congenital Dengue; Neonatal Dengue; Vertical Transmission; Different Presentation.

Introduction

Dengue is an infectious disease caused by dengue virus and is transmitted classically by bite of female *Aedes aegypti* mosquito. The infection is endemic in India. In pregnant females, it can lead to premature labor. Breastfeeding has been proposed as a route of vertical transmission of dengue virus. Majority of reported cases demonstrate dengue in neonates whose mothers were infected very late in pregnancy. Vertical transmission of dengue has been reported and should be considered in cases where illness in the mother occurs within 10 days before delivery. In neonates, vertical transmission of dengue produce varying symptoms, from fever with thrombocytopenia, cerebral hemorrhage and myocarditis.^{1,3} Due to lack of resources and capacity to survey congenital dengue effectively, very little is known about transplacental transmission of dengue.

Case Report

A term 3.2 kg male baby was delivered by cesarean birth with Apgar scores 5, 7, and 9 at 1, 5, and 10 minutes,

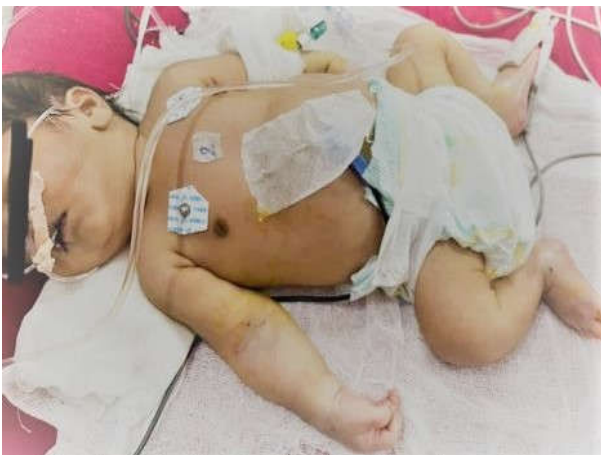respectively. His mother had a history of fever since 10 days before delivery. ANC USG was suggestive of mild ascites and pleural effusion in the fetus USG was done at 39 weeks of gestation. In anticipation of probable heart disease and meconium stained liquor the baby was admitted in NICU. Initially the ascites and pleural effusion was suspected to be of cardiac origin, a 2 D Echo was done which revealed a tiny PFO. As feeding was established and baby was clinically stable, was discharged to mother side on day 3 of life. At day 6 of life the baby was readmitted with the complaints decreased acceptance of feed and lethargy. In due time baby had evidence of arrhythmia and was controlled on amiodarone, during the course patient had hypotension, hepatomegaly, edema, ascites and pleural effusion. A complete blood count revealed thrombocytopenia along with leucopenia, liver enzymes were deranged (AST 1500, ALT 700), INR was 2.44, cardiac troponin I was 0.4 which corresponded to upper reference range, blood culture was sterile please see for detail investigations.



Table 1: Serial investigations.

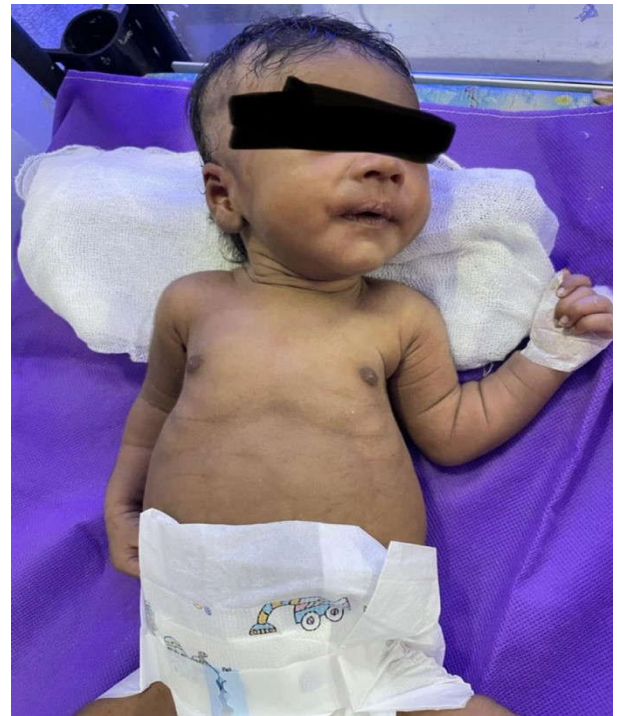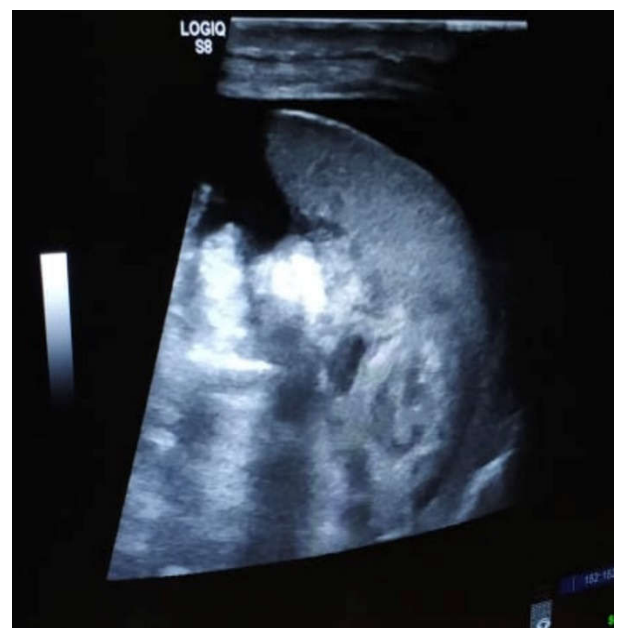
Parameter Days	HB	HCT	TLC	Platelet Count	SGOT	SGPT	CREAT	PT INR
Day 1	19	50	12000	23,000	211	113	0.9	2.7
Day 3	14	38	10000	24000	–	–	0.8	–
Day 5	11.6	33.6	7000	9000	1020	450	1.4	–
Day 7	12	32	4000	45000	342	78	1.8	–
Day 10	14	40	9700	84000	98	62	0.9	1.3
Day 12	15	45	6000	1240000	–	–	–	–

Due to clinical suspicion of dengue, serology of the baby was sent which was positive for nonstructural antigen 1 (NS1) and Ig G test. Retrospectively the mother's serological test results were sent and were positive for nonstructural antigen 1 (NS1) and IgM test for dengue and were negative for human immunodeficiency virus, Hepatitis B surface antigen, and venereal disease research laboratory. The baby developed severe respiratory distress. His peripheral pulses were feeble, blood oxygen saturation fluctuated between 80% and 92% on pulse oximetry. He had massive hepatomegaly (liver 4 cm in the right midclavicular line), gross ascites, gross pleural effusion confirmed on USG (gall bladder wall pseudo thickening was noted), decreased air entry in bilateral basal region of the lung. Urine output was decreased. Intensive care was given to the baby with CPAP support, fluid as per dengue protocol, inotropes and blood transfusions. The shock improved gradually in response to treatment with normalizing urine output, blood pressure and decrease in edema. Patient was shifted to nasogastric tube feeds. After stabilization patient was discharged.

**Fig. 1:** Dengue Patient Presentation.

Discussion

This child, born during the peak of the dengue season in Central India, had congenital dengue as evidenced by symptoms in the mother 10 days before delivery as well as the dengue antigen positivity both in the mother and child. The likelihood of vertical transmission when the mother is infected is low. To date, there have been no reports of congenital dengue infection in neonates born to mothers infected early in pregnancy.¹

**Fig. 2:** Dengue Patient recovered.**Fig. 3:** Ultrasound Showing Ascitis.

Conclusion

A possible explanation is that maternal infections acquired near the time of delivery would not have had enough time for protective antibodies to be produced and transferred to the neonate, therefore conferring a passive immunity. The maternal viremia would therefore be transferred to the unprotected fetus in last trimester.² In a prospective study of 2958 pregnant female, 2531 paired maternal-umbilical cord blood samples were tested for dengue IgM. Sixty-three women (prevalence of 2.5 percent) had a positive IgM serology. Only one (vertical transmission of 1.6 percent) of the paired umbilical cord samples was seropositive for dengue. All the maternal and fetal blood samples were negative for viral RNA by polymerase chain reaction.⁵ Some reports have described variable neonatal outcomes, from asymptomatic infections to death. Our case is unique as maternal dengue is retrospectively diagnosed and vertical transmission was confirmed. Swaminathan et al reports association of persistent hematological derangements and presence of PDA and pulmonary hypertension in a similar patient.⁴ The limitation of this report is that the cause effect relationship was retrospectively proven. However, in endemic areas with this type of presentation, vertical transmission of dengue must be considered. The case report highlights the importance of diagnosing

congenital dengue in a proper setting and appropriate selection of treatment modality and ensure timely diagnosis and improve patient management.

References

1. Barthel A, Gourinat AC, Cazorla C, Joubert C, Dupont-Rouzeyrol M, Descloux E. Breast milk as a possible route of vertical transmission of dengue virus? *Clinical infectious diseases: an official publication of the Infectious Diseases Society of America*. 2013;57(3):415-7.
2. Thomas J, Thomas P, Reeba George C. Neonatal dengue. *International Journal of Contemporary Pediatrics*. 2017;4(6):2234.
3. Gupta S, Choudhury V, Gupta NP, Gupta V, Pandita A. Congenital dengue in neonate. *Clinical case reports*. 2021;9(2):704-6.
4. Shastri J, Williamson M, Vaidya N, Agrawal S, Shrivastav O. Nine year trends of dengue virus infection in Mumbai, Western India. *Journal of laboratory physicians*. 2017;9(4):296-302.
5. Swaminathan A, Kirupanandhan S, Rathnavelu E. Challenges in a unique presentation of congenital dengue with congenital heart disease. *BMJ case reports*. 2019;12(6).