

Isolation and Antibigram Study of Infectious Bovine Kerato-conjunctivitis

G Deepika Kumari¹, M Navya², P Tejaswi³, Mohd. Umar⁴

How to cite this article:

G Deepika Kumari, M Navya, P Tejaswi, et al. Isolation and Antibigram Study of Infectious Bovine Kerato-conjunctivitis. Indian Journal of Agriculture Business. 2019;5(2):65-67.

Author's Affiliation

¹Assistant Professor, ^{2,3,4}PG Scholars,
Department of Veterinary Microbiology,
NTR College of Veterinary Science,
Gannavaram, Andhra Pradesh 521101,
India.

Coresponding Author:

G Deepika Kumari, Assistant Professor,
Department of Veterinary Microbiology,
NTR College of Veterinary Science,
Gannavaram, Andhra Pradesh 521101,
India.

E-mail: deepu.angrau@gmail.com

Received on 20.11.2019

Accepted on 24.12.2019

Abstract

A buffalo of 4 lactations was presented to the Teaching Veterinary Clinical Complex, NTRC VSc., Gannavaram with a case history of lacrimation, pinkness of both the eyes and mild conjunctivitis. The lacrimal samples were collected aseptically and sent for further laboratory diagnosis for confirming the causative agent. The colonies were mucoid with sticky in nature, on Grams staining characteristic diplococci were observed, produced β -hemolysis on blood agar and biochemically oxidase and catalase positive provisionally suggestive of *Moraxella bovis*. The bacterium was susceptible to tetracyclines.

Keywords: *Moraxella bovis*; Diplococci; Conjunctivitis.

Introduction

Moraxella bovis, a Gram negative aerobic diplococci bacterium responsible for causing an eye disease in bovines called Infectious bovine kerato-conjunctivitis (IBK) characterised by conjunctivitis, odema of the eye, ulceration and corneal opacity.⁵ It causes high morbidity and low mortality with marked reduction in production. The infection is seen only in bovines and synonymously called as pink eye or New forest disease.² The disease is highly contagious and is transmitted by direct contact or by flies from the infected ones. The cattle exhibits signs of pain in the eye with increased lacrimation, excessive blinking and pinkness of eye. Predisposing factors impose a major role in the disease occurrence. Disease is complicated with concurrent infections of virus like Infectious bovine rhinotracheitis (IBR), bacterial infections related with mycoplasma and listeria and rarely with

thelazia nematodal infections.⁶ The disease is more susceptible in summer than in autumn.¹

Materials and Methods

A buffalo was presented to the Teaching Veterinary Clinical Complex, NTR CVSc., Gannavaram with a case history of severe lacrimation, mild conjunctivitis associated with pinkness of both the eyes. The lacrimal secretions were aseptically collected in a sterile swab container having nutrient broth and incubated in an incubator for a period of 24 hrs and 37°C was maintained.

Isolation of *Moraxella bovis* on basal and differential agars

After attaining sufficient growth in the pre enrichment medium, i.e. nutrient broth, it was streaked on brain heart infusion agar. For further



confirmation it was isolated on blood agar for detecting the haemolytic activity.

Direct Microscopic examination

Grams staining was performed to examine the smears prepared from basal and differential agars.

Biochemical characterisation

The colonies from the blood agar were further subjected for biochemical tests like oxidase and catalase test.

Catalase test: Catalase enzyme catalyzes the decomposition of hydrogen peroxide to water and oxygen. It is a very important enzyme in protecting the cell from oxidative damage by reactive oxygen species.

Oxidase test: The oxidase test was used to identify bacteria that produce cytochrome c oxidase, an enzyme of the bacterial electron transport chain. When present, the *cytochrome - C oxidase* oxidizes the reagent (*tetramethyl-p-phenylenediamine*) to (*indophenols*) purple color end product. When the enzyme is not present, the reagent remains reduced and is colorless.

Antibiotic resistance pattern

The antibiotic disc diffusion method was done to test the sensitivity of *Moraxella bovis* isolates as per the Kirby and Buear method. The Mueller-Hinton agar plates were incubated for 24 hrs at 37°C and the zone of inhibition of bacterial growth by the antibiotic discs was noted in comparison with the standard charts.

Results and Discussion

Based on the clinical symptoms it was suggestive that the ocular disease may either be a bacterial or viral infection. Morphological characterisation was carried to rule out the viral infections which might be of Infectious bovine rhinotracheitis virus (IBR). The ocular swabs enriched in nutrient broth were streaked on basal and differential media.

Growth on basal and differential agars

On the basal agar, i.e. Brain heart infusion agar white mucoid, sticky colonies were grown after a period of 24 hrs. When further streaked on blood agar beta hemolysis was noted (Fig 1). *Moraxella bovis* produces partial hemolysis on the blood agar confirming the presence of the bacteria.



Fig. 1: On blood agar beta hemolysis, i.e. partial hemolysis was observed

Direct Microscopic examination

Grams staining was performed from the smears prepared from basal and differential agars. Typical characteristic Gram negative pink coloured diplococci were noticed (Fig. 2). Majority of the bacteria appeared in cocci and in groups and few characteristic diplococci significant of *Moraxella bovis* was also identified.

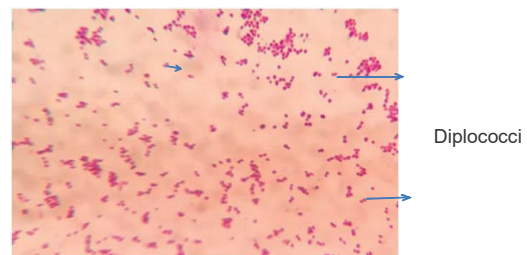


Fig 2: Characteristic appearance of gram negative diplococci on grams staining

Biochemical tests

Biochemical characterisation revealed catalase positive, production of catalase enzyme by the bacterium with production of bubbles in the form of oxygen (Fig. 3). Oxidase test was also positive indicated by the presence of production of indophenols detected in the form of purple colour (Fig. 4). Both the tests were confirmative for *Moraxella bovis* bacteria.

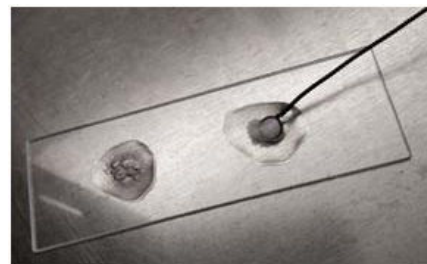


Fig. 3: Catalase test-production of oxygen




Fig. 4: Oxidase test–production of indophenols

Antibiotic susceptibility

On performing ABST the culture was susceptible primarily to tetracyclines, pencillins and enrofloxins and totally resistant to gentamicin. Similar results were reported by Parin et al., and revealed that oxytetracyclines were susceptible to *Moraxella bovis* bacteria.

Conclusion

Moraxella bovis is one of the microorganism responsible for the ocular infections in cattle. In the above case study an attempt was made to isolate and confirm the Gram negative bacteria *Moraxella bovis*. Colonial morphology and biochemical tests

provisionally confirm the infection as *Moraxella bovis*. The bacteria was susceptible to tetracyclines when compared to other antibiotics.

References

1. Angelos JA, Edman JM & Chigerwe M. Ocular immune responses in steers following intranasal vaccination with recombinant *Moraxella bovis* cytotoxin adjuvanted with polyacrylic acid. *Clin. Vaccine Immunol.* 2014;21(2):181–87.
2. John A Angelos MSD Veterinary Manual.
3. George L, Smith J & Kaswan R. Distribution of oxytetracycline into ocular tissues and tears of calves. *J. vet. Pharmacol. Therap.* 1985;8:47–54.
4. Parin U, Kirkan S and Gumus S. Isolation of *Moraxella bovis* in cattle and detection of antibiotic susceptibilities. *International Journal of Veterinary Science*, 2017;6(4):228–31.
5. Postma GC, Carfagnini JC and Minatel L. *Moraxella bovis* pathogenicity: an update. *Comparative immunology, microbiology and infectious diseases*, 2008;31(6):449–58.
6. Rebhun's diseases of dairy cattle (Third edition) 2018.