

Original Research Article

Clinical and Histopathological Presentation of Papulosquamous Skin Disorders with Special Emphasis on Lichen Planus in Tertiary Care Hospital

Sapana Bhadane¹, Sushant Bhadane²

¹Assistant Professor, Department of Pathology, ²Associate Professor, Department of Radiology, SMBT Medical College, Dhamangaon Ghoti, Tal. Igatpuri, Dist Nasik, Maharashtra 422403, India.

Corresponding Author:

Sushant Bhadane, Associate Professor, Department of Radiology, SMBT Medical College, Dhamangaon Ghoti, Tal. Igatpuri, Dist Nasik, Maharashtra 422403, India.

E-mail: drsushbhadane@gmail.com

Received on 18.06.2019,

Accepted on 24.07.2019

Abstract

Background: The papulosquamous disorders are complex to diagnose, because of the difficulty in identification and may resemble a similar disorder of the group. Lichen planus is an inflammatory dermal condition of the muco-cutaneous surfaces which present with a varied clinical manifestations. High prevalence of disease noted on the Indian subcontinent. **Aim:** To study the clinical & histopathological presentation of papulosquamous disorders with special emphasis on Lichen Planus. **Material and Methods:** Descriptive histopathological study of papulosquamous disorders of skin was conducted at Department of Pathology with 61 cases of clinically diagnosed papulosquamous eruptions. **Results:** Lichen planus was the commonest (57.37%) followed by Psoriasis and Prurigo nodularis. High predominance was observed in males for all diseases. Lichen planus occurred in all age groups but was commonly seen in young and middle age groups. Flat topped papules and plaques were the commonest type of clinical patterns seen in Lichen planus. Out of 35 cases of Lichen planus, 29 were clinically diagnosed and confirmed by histopathology. **Conclusion:** Clinical diagnosis was difficult due to overlapping of both clinical pattern and distribution of papulosquamous skin disorders. Combination of proper clinical observation, histo-pathological & morphological study for conclusive diagnosis.

Keywords: Dermatitis; Eruptions; Psoriasis; Scaly Papules; Pityriasis.

How to cite this article:

Sapana Bhadane, Sushant Bhadane. Clinical and Histopathological Presentation of Papulosquamous Skin Disorders with Special Emphasis on Lichen Planus in Tertiary Care Hospital. Indian J Pathol Res Pract. 2019;8(5):645-649.

Introduction

A papulosquamous disorder is a condition which presents with both papules and scales, or both scaly papules and plaques. Lichen planus,

Psoriasis, Pityriasis rosea, Pityriasis rubra pilaris, Prurigo nodularis, Prurigo simplex, Lichen nitidus, Parapsoriasis, Inflammatory Linear Verrucous Epidermal Nevus, Pityriasis lichenoides are common papulosquamous disorders.¹



Lichen planus (LP) is an inflammatory dermal condition of the muco-cutaneous surfaces which present with a varied clinical manifestations. High prevalence of disease noted on the Indian subcontinent. LP most commonly affects middle-aged people, but childhood-onset LP has also been noted. Both gender are get affected equally. LP is a self-limited condition that, according to one epidemiologic study, may resolve after 1 month to 7 years.²

The papulosquamous disorders are complex to diagnose, because of the difficulty in identification and may resemble a similar disorder of the group. Hence these lesions are commonly misdiagnosed.³ The aim of the study was to determine the clinical & histopathological presentation of papulosquamous disorders with special emphasis on Lichen Planus.

Materials and Methods

An observational, descriptive histopathological study of papulosquamous disorders of skin was conducted at Department of Pathology in Dr, Vasantarao Pawar Medical College, Nashik. Study included 61 cases of clinically diagnosed papulosquamous eruptions who attended Department of Dermatology, Venerology and Leprosy of same institute. Institutional Ethics Committee permission was taken before data collection. Cases attending skin OPD and fulfilling inclusion and exclusion criteria were included in study. Written informed consent was taken from

each study participant. Cases with clinical features suggestive of papulosquamous skin disorders like Lichen planus, Psoriasis, Pityriasis rosea, Prurigo nodularis, Prurigo simplex and inflammatory linear verrucous epidermal nevus were included. Patients having high bleeding time, clotting time, keloidal tendency and not willing to give consent were excluded. A brief history and dermatological examination was carried out. Skin biopsies taken were fixed in 10% formalin and subjected for tissue processing. The processed tissue was embedded in paraffin to obtain 5 micron thin sections. The sections were stained with routine H & E stain, followed by microscopic examination. There H & E sections were studied and correlated with clinical features. Standard operational definitions and protocols were set before start of study and followed till end.

Data was entered in Microsoft Excel 2007 and analysed using SPSS V.16. Descriptive statistics like frequency and proportions were used to analyse data. Data presented with appropriate tables and graphs.

Results

In the present study of 61 cases of papulosquamous disorders, Lichen planus was the commonest (57.37%) followed by Psoriasis, Prurigo nodularis, Pityriasis rosea, Lichen nitidus, Prurigo simplex and inflammatory linear verrucous epidermal nevus. High predominance was observed in males for all diseases (Table 1).

Table 1: Gender wise distribution of cases-papulosquamous skin diseases

Disease	Male	Female	Total (%)
Lichen Planus	21	14	35 (57.37)
Psoriasis	15	5	20 (32.78)
Prurigo Nodularis	1	1	2 (3.27)
Pityriasis Rosea	1	0	1 (1.63)
Lichen Nitidus	1	0	1 (1.63)
Prurigo Simplex	1	0	1 (1.63)
Inflammatory Linear Verrucous Epidermal Nevus	1	0	1 (1.63)
Total	41	20	61 (100)

As indicated in Table 2, Lichen planus occurred in all age groups but was commonly seen in young and middle age groups. Prurigo nodularis and Psoriasis was seen in middle age groups. Pityriasis rosea, Lichen nitidus, Prurigo simplex and inflammatory linear verrucous epidermal nevus were seen in children and young adults. Pityriasis rosea presented with scaly plaque, patch and macule. Histologically common features were

parakeratosis and upper malphigian spongiosis. Lichen nitidus presented with papule and flat topped plaque.

Histologically it had circumscribed chronic inflammatory infiltrate. Prurigo nodularis had hyperkeratosis and papulomatosis. Prurigo simplex had acanthosis and parakeratosis. Inflammatory Linear Verrucous Epidermal Nevus had focal parakeratosis and acanthosis.

Table 2: Age wise distribution of cases- papulosquamous skin diseases

Age group in years	Lichen Planus	Psoriasis	Prurigo Nodularis	Pityriasis Rosea	Lichen Nitidus	Prurigo Simplex	Inflammatory Linear Verrucous Epidermal Nevus
1 to 10	1	0	0	0	1	0	0
11 to 20	7	4	0	0	0	0	0
21 to 40	11	5	2	1	0	1	1
41 to 60	7	8	0	0	0	0	0
>60	9	3	0	0	0	0	0

Figure 1 and Table 3 depict clinical presentations and histopathological changes in Lichen Planus. In present study, 35 cases of Lichen planus were studied. Flat topped papules and plaques were the commonest type of clinical patterns seen in Lichen planus in this study. Most of the cases showed hyperkeratosis, hypergranulosis, irregular acanthosis with saw toothed rete ridges, vacuolar degeneration, dermal band like infiltrate and pigment incontinence. All cases showed

mononuclear type of cellular infiltrate.

Out of 35 cases of Lichen planus, 29 were clinically diagnosed and confirmed by histopathology. Four cases had clinical diagnosis of Psoriasis, tuberculosis verrucosa cutis and phytophotodermatitis which were Lichen planus under histopathology study. In 2 cases, Lichen planus was differential diagnosis along with lichenoid drug eruptions and Prurigo nodularis.

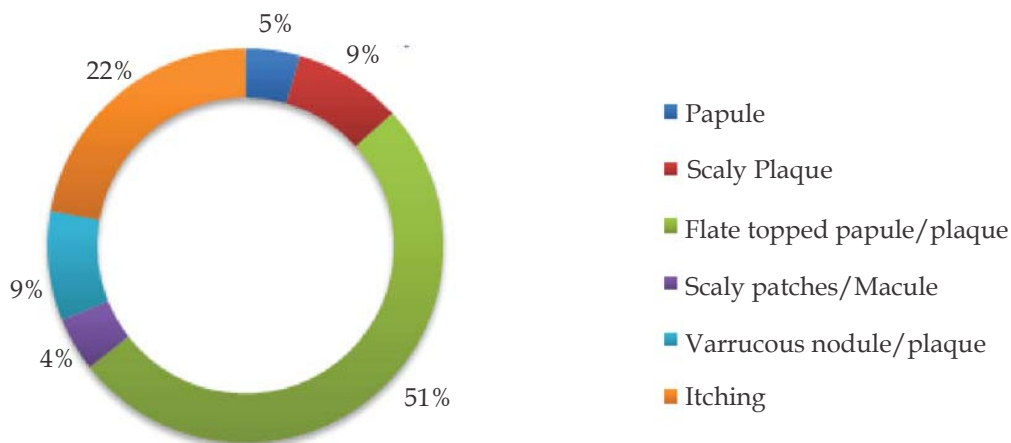


Fig. 1: Clinical presentation of histologically diagnosed Lichen Planus

Table 3: Histological changes in Lichen Planus.

Histopathological changes	No. of cases	%	
Epidermal changes	Hyperkeratosis	10	28.57
	Focal parakeratosis	2	5.71
	Irregular acanthosis with saw toothed rete ridges	23	65.71
	Hypergranulosis	31	88.57
	Vacuolar degeneration of basal cells	29	82.85
	Max Josef spaces	2	5.71
	Civatte bodies	2	5.71
	Dermal changes	Dermal infiltrate-Band like	31
Dermal infiltrate-Spotty		4	11.43
Cell type infiltrate- Mononuclear		35	100
Cell type infiltrate- Epitheloid		0	0
Pigment incontinence		17	48.57
Vascular changes		0	0

Discussion

A study of 61 cases with clinical diagnosis of papulosquamous skin disorders was undertaken. In present study age incidence was distributed almost equally from 11 to 50 years of age corresponding to 80.95% of total cases of Lichen planus. Less than 10 years and 51 to 60 years of age groups had 4.76% of cases each. Maximum number of cases were reported from 21 to 40 years. Studies done by Rahnama *et al.*,⁴ Chaudhary *et al.*⁵ and Kumar *et al.*⁶ also reported age group of 20 to 40 years for maximum occurrence of cases. Seema *et al.*⁷ and Mani *et al.*⁸ reported wide range of age group from 21 to 50 years for occurrence of cases. In present study, Lichen planus was reported more commonly in males. Female preponderance was noted in Chaudhary *et al.*,⁵ Kumar *et al.*⁶ Mani *et al.*,⁸ Rahnama *et al.*⁴ and Seema *et al.*⁷ reported male preponderance.

In present study, 57.37% cases were classical Lichen planus. Majority of cases showed hyperkeratosis, irregular acanthosis, hypergranulosis and vacuolar degenerations. Dermis showed typical dermal infiltrate. Four cases of Lichen planus pigmentosus showed increased pigmented macrophages in upper dermis along with other classical features of Lichen planus. These findings are consistent with the classic description of Lichen planus given by Mobini *et al.*⁹ In present study, other than Lichen planus, hypertrophic Lichen planus was the commonest subtype followed by pigmented Lichen planus. Thippeswamy *et al.*¹⁰ and Banushree *et al.*¹¹ showed almost similar findings.

Mani *et al.*⁸ had 46 cases of histologically diagnosed as Lichen planus. Nineteen of them were clinically diagnosed (without differential diagnosis) and confirmed histologically while 27 cases had clinically differential diagnosis and diagnosed Lichen planus on histology. In present study, out of 35 cases, 29 cases were diagnosed clinically as Lichen planus and confirmed histologically while 6 cases had differential diagnosis as Psoriasis, tuberculosis verrucosa cutis, lichenoid drug eruption, prurigo nodularis and phytophotodermatitis. Psoriasis was commonest differential diagnosis (14/27 cases) in study done by Mani *et al.*⁸ while in present study, 2 out of 6 cases had Psoriasis as clinical differential. One case in study done by Mani⁸ and 2 cases in present study were confused for Tuberculosis verrucosa cutis clinically. Mani⁸ had 1 case in which clinical diagnosis was Lichen planus but histologically it turned out to be parapsoriasis.

Though diagnosis of Lichen planus is usually made with ease clinically, confirmation with skin biopsy is always warranted.¹²

Conclusion

Clinical diagnosis was difficult due to overlapping of both clinical pattern and distribution of papulosquamous skin disorders. Some of the histologic features were specific and characteristics to each entity. However some of the histological features overlapped in lesions like Lichen planus, Psoriasis, Prurigo nodularis, Pityriasis rosea, and Prurigo simplex. This underlines use of combination of proper clinical observation, histo-pathological & morphological study for conclusive diagnosis.

References

1. D' Costa G, Bharambe BM. Spectrum of non-infectious erythematous, papular and squamous lesions of the skin. *Indian J Dermatol.* 2010;55(3):225-228.
2. Bhattacharya A, Kaur I, Kumar B. Lichen planus: a clinical and epidemiological study. *J Dermatol.* 2000;27:576-582.
3. Norman RA, Blanco PM. Papulosquamous diseases in the elderly. *Dermatol Ther.* 2003;16(3):231-242.
4. Rahnama Z, Esfandiarpour I, Farajzadeh S. The relationship between lichen planus and hepatitis C in dermatology out patients in Kerman, Iran. *Int J dermatol.* 2005;44:746-8.
5. Chaudhary Raju G *et al.* Study of Clinico-histopathological Correlation of Papulosquamous Disorders at Tertiary Care Hospital. *Sch. J. App. Med. Sci.*, 2015;3(3B):1154-58.
6. Kumar V, Nangia A, Logani K, *et al.* Lichen planus- a clinic histopathological correlation. *Indian J Dermatol Venerol Leprol* 2000 Jul-Aug;66(4):193-5.
7. Seema BN. Histopathological study of papulosquamous disorders of skin. *Mysore J Dermatol.* 2010;4:135-8.
8. Mani A. Histological spectrum of papulosquamous lesions of skin, encountered at MSRMC from January 2003 to December 2005. *Ind J Dermatol.* 2006;4:152-6.
9. Mobini N, Toussaint S, Kamino H. Non-infectious erythematous papular and squamous disorders. In: Elder DE, Elenistas R, editors. *Lever's histopathology of skin.* 9th ed. Philadelphia: Lippincott Williams and Wilkins; 2005. pp.179-214.

10. Thippeswamy MTR. Histomorphologic study of papulosquamous disorders of skin. *Ind J Dermatol.* 2000;3:104-7.
11. Banushree CS, Nagarajappa AH. Clinicopathological study of lichen planus and lichenoid eruptions. In: XXXIV Annual conference of Karnataka chapter- IAPM: 2nd to 4th November 2007 Danangere: JJMMC & SSIMC: p.4.
12. Wu H, Harrist TJ, Branding-Bennett HA. Noninfectious vesiculobullous and vesiculopustular diseases. In Elder DE editor; *Lever's histopathology of the skin.* 10th edition, Wolters Kluwer (India) Pvt. Ltd., New Delhi, 2010.pp.235-278.

