

## Liver in-place of Lung: Rare Diaphragmatic Injury

Pintu Kumar<sup>1</sup>, Manisha Rajaure<sup>2</sup>, Anita Rawat<sup>3</sup>, Kishalay Datta<sup>4</sup>

### How to cite this article:

Pintu Kumar, Manisha Rajaure, Anita Rawat, *et al.* Liver in-place of Lung: Rare Diaphragmatic Injury. *Ind J Emerg Med.* 2024;10(2):61-63.

### Abstract

Diaphragmatic rupture injury is usually seen in the setting of a high speed motor vehicle accident. Rupture of the left diaphragm is common when compared to the right side in the setting of diaphragmatic blunt injury. In this case report, we discuss a rare incident of right hepatothorax following a high speed motor accident.

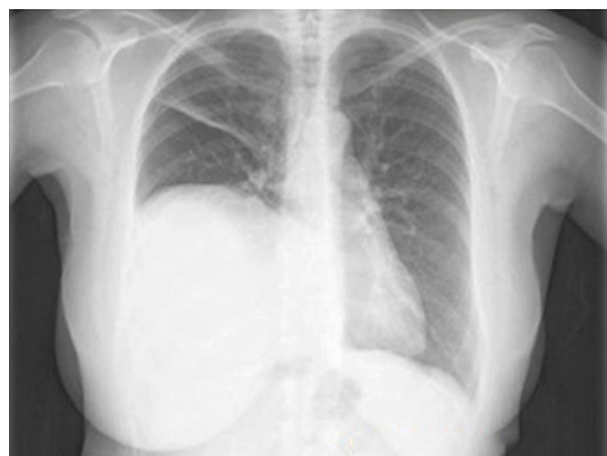**Keywords:** Hepatothorax; Diaphragm Injury; Massive Transfusion Protocol.

### INTRODUCTION

Injury to the diaphragm is usually a rare entity in cases of high speed motor vehicle accidents.<sup>1</sup> 90% of the cases of diaphragmatic injuries occur over the left side, but right side diaphragmatic injury cases are on rise in cases of blunt abdominal trauma following road traffic accidents.<sup>2</sup> The lower rate of incidence and difficult in diagnosis can lead to delayed treatment, thus, increasing the mortality and morbidity in such patients. Delayed treatment can lead to atelectasis of lung, bowel herniation and strangulation, solid viscera herniation, all this can occur as late as 50 years from the time of incidence.<sup>3</sup>

### CASE

A 26 year old young girl was brought to the emergency department of Max hospital with an alleged history of road traffic accident. The event occurred around 2 hours before arrival to the ER. The patient was initially taken to nearby PHC (Primary health center) where initial treatment was given and referred to higher centers.



**Fig. 1:** An emergent chest x-ray

**Author's Affiliation:** <sup>1,2</sup>Resident, <sup>3</sup>Senior Consultant, <sup>4</sup>H.O.D, Emergency Medicine, Emergency Medicine, Max Superspeciality Hospital, Shalimar Bagh 110088, Delhi, India.

**Corresponding Author:** Manisha Rajaure, Resident, Emergency Medicine, Max Superspeciality Hospital, Shalimar Bagh 110088, Delhi, India.

**E-mail:** [rajauremanisha12@gmail.com](mailto:rajauremanisha12@gmail.com)

**Received on:** 19-12-2023

**Accepted on:** 20-02-2024



The patient complained of difficulty in breathing following arrival to the ER. The vitals recorded were - pulse rate - 122/min, BP - 90/50 mmHg, spo<sub>2</sub> - 91% on oxygen support, respiratory rate - 26/min. The patient was visibly tachypneic. The patient had an unstable pelvic fracture with bleeding from the urinary meatus with a tense abdomen. A high suspicion for pneumothorax was to be ruled out. An emergent chest x-ray was done.

The x-ray was suggestive for the decreased lung volume of the right lung.

An urgent ultrasonography (FAST) was done which was highly suggestive of upward migration of the liver parenchyma into the lung space with peritoneal collection (more suggestive of blood collection). The patient was going into hypotensive shock, massive transfusion was given.

The patient was immediately taken for emergency laparotomy by the surgery team (multi-disciplinary approach) consisting of general surgeon, vascular surgeon and cardiothoracic surgeon, orthopedics, in-order to replace back the abdominal content into the peritoneal cavity and stabilize the pelvis. On laparotomy, peritoneal blood collection was noted with visceral rupture, the liver positioned high into the pleural cavity, diaphragmatic rupture was noted. The liver was pushed down and the diaphragm was closed "in layers". The visceral injuries were repaired, the pelvis fracture was stabilized by screws and nuts. A total of 10 units of blood was transfused along with other blood

products, the surgery lasting for a total of 20-22 hours.

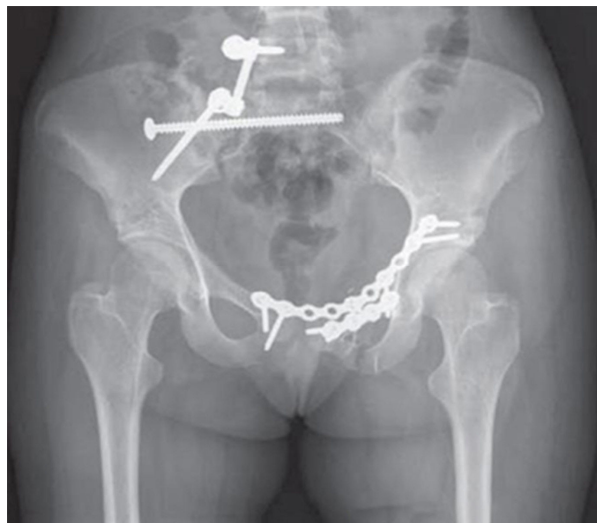

Fig. 2: Show Helical CT of the Abdomen

The patient was successfully extubated on day 2 of surgery, the patient's vital parameters were continued to resolve and the patient was successfully discharged on 25th day after her accident from hospital. Her regular follow-ups continued with the doctors and she recovered well.

## DISCUSSION

This case report explains the rare occurrence of right diaphragmatic rupture injury secondary

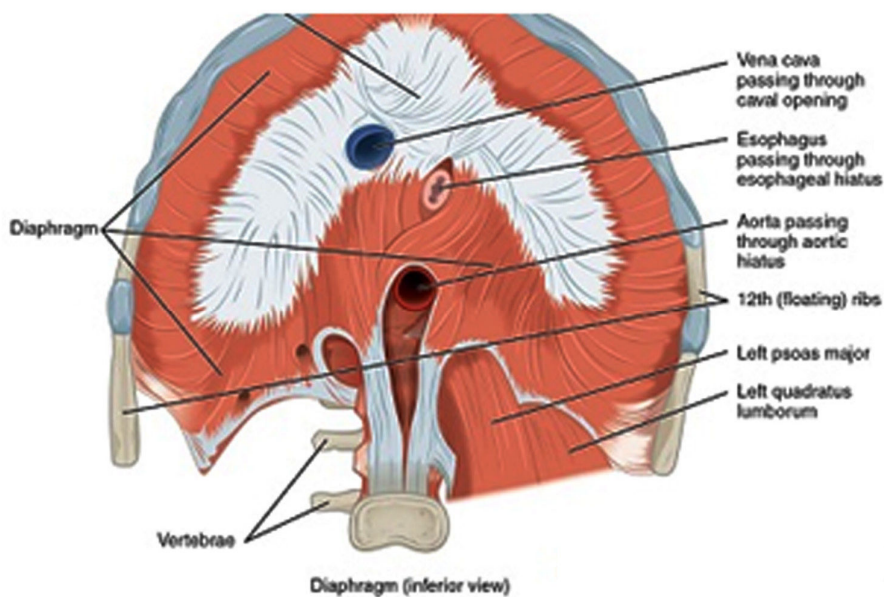


Fig. 3: Diaphragm (Inferior View)

to severe abdominal and pelvis injury. The right diaphragmatic injury is rare when compared to left diaphragm injury, approximately 0.25-1% of diaphragm injuries, the liver acting as a major shock absorber.<sup>4</sup> The diaphragm serves a major muscle of respiration<sup>4</sup> and rupture of diaphragm can present majorly with respiratory distress, lung atelectasis or mediastinal shift.

Right diaphragmatic injuries, due to its rare nature, are delayed or never detected. Right diaphragmatic injuries are always associated with underlying abdominal or pelvic injuries.<sup>5</sup> The sudden increase in intra abdominal pressure due to blunt abdominal trauma results in diaphragm rupture. In this case, we suggest that there was a high impact of the accident on the patient leading to fracture of pelvis and rupture of the viscera, leading to increased intraabdominal pressure and thus, herniation of the liver into the right pleural space.

Chest X Ray, when done, detects the right pleural fullness which prompts the emergency team to investigate further. Focussed assessment with sonography in trauma (FAST) is helpful in detection of displaced liver into the right pleural space<sup>6</sup>, although some studies show helical CT of the abdomen having more sensitivity than FAST or conventional CT abdomen.<sup>6</sup>

The treatment mainstay is abdominal laparotomy for reducing the abdominal contents into the abdomen and closure and strengthening the diaphragm wall.

## CONCLUSION

In conclusion, this patient was a polytrauma patient having injuries to pelvis, viscera and

diaphragm. Right diaphragmatic injury is rare and thus, increases the chances of misdiagnosis and delayed treatment. This patient had a critical prognosis due to involvement of multiple injuries, prolonged surgery and hospital stay, anesthetic complications during the surgery and post operative physiotherapy sessions for pelvis mobilization, lung ventilation strategies.

This case report is unique in terms of the patient presentation and hopeful to guide clinicians more about diaphragmatic injuries and approach.

## REFERENCES

1. Delayed hepatothorax due to right-side traumatic diaphragmatic rupture Igai, H. Yokomise, K. Kumagai, *et al.* Gen Thorac Cardiovasc Surg, 55 (2007), pp. 434-436.
2. P. A. Kearney, S. W. Rouhana, and R. E. Burney, "Blunt rupture of the diaphragm: mechanism, diagnosis, and treatment," *Annals of Emergency Medicine*, vol. 18, no. 12, pp. 1326-1330, 1989.
3. S. Singh, M. M. Kalan, C. E. Moreyra, and R. F. Buckman, "Diaphragmatic rupture presenting 50 years after the traumatic event," *Journal of Trauma*, vol. 49, no. 1, pp. 156-159, 2000.
4. S.W. Hwang, H.Y. Kim, J.H. Byun -Management of patients with traumatic rupture of the diaphragm" *Korean J Thorac Cardiovasc Surg*, 44 (2011), pp. 348-354.
5. G.A. Tiberio, N. Portolani, A. Coniglio, *et al.* Traumatic lesions of the diaphragm. Our experience in 33 cases and review of the literature *Acta Chir Belg*, 1 (2005), pp. 82-88.
6. A. Nchimi, D. Szapiro, B. Ghaye, *et al.* Helical CT of blunt diaphragmatic rupture *AJR Am J Roentgenol*, 184 (2005), pp. 24-30.