

# Investigating the Healing Potential of Topical Phenytoin for Therapeutic Treatment in Thermal Burns

Karthikeyan<sup>1</sup>, Ravi Kumar Chittoria<sup>2</sup>, Jacob Antony Chakiath<sup>3</sup>,  
Kanav Gupta<sup>4</sup>, Padmalakshmi Bharathi Mohan<sup>5</sup>

## How to cite this article:

Karthikeyan, Ravi Kumar Chittoria, Jacob Antony Chakiath *et al.* Investigating the Healing Potential of Topical Phenytoin for Therapeutic Treatment in Thermal Burns. *New Indian J Surg.* 2024; 15(2):59-61.

## Abstract

Thermal burn injuries impose significant physical and psychological distress, particularly in under developed regions. Facilitating early wound healing is paramount to mitigate ensuing complications. Phenytoin, easily accessible, has emerged as a potential agent for expediting wound recovery. This study endeavours to assess the therapeutic efficacy of topical phenytoin in second and third-degree burn injuries. The research involved a 70-year-old female with thermal burns affecting both gluteal regions. Intravenous phenytoin solution was topically applied every two days. Data collection encompassed demographic details, tissue culture findings, wound discharge, pain intensity, granulation tissue formation, and wound contraction. Self-inflicted burns predominated the cases examined. Despite initial colonization with pathogenic bacteria, phenytoin treatment did not impede wound healing. Following 2-4 sessions, a significant reduction in wound discharge and pain relief was observed. Digital planimetry demonstrated progressive wound contraction across all cases. In conclusion, topical phenytoin application demonstrated efficacy in promoting wound contraction, re-epithelialization, and alleviating pain, thereby expediting wound healing. Furthermore, some cases exhibited a bacteriostatic effect. Nevertheless, further rigorous trials are imperative to validate these findings.

**Keywords:** Topical phenytoin therapy; Regenerative therapy; Wound management.

**Author Affiliation:** <sup>1</sup>Junior Resident, Department of Orthopedic Surgery, <sup>2</sup>Professor, Head of IT Wing and Telemedicine, Department of Plastic Surgery & Telemedicine, <sup>3,4</sup>Senior Resident, <sup>5</sup>Assistant Professor, Department of Plastic Surgery, Jawaharlal Institute of Postgraduate Medical Education and Research, Pondicherry 605006, India.

**Corresponding Author:** Ravi Kumar Chittoria, Professor, Head of IT Wing and Telemedicine, Department of Plastic Surgery & Telemedicine, Jawaharlal Institute of Postgraduate Medical Education and Research, Pondicherry 605006, India.

**Email:** drchittoria@yahoo.com

**Received on:** 06-05-2024 **Accepted on:** 29-06-2024

## INTRODUCTION

Burn injuries present notable physiological and psychological hurdles, necessitating specialized interventions including fluid regulation, electrolyte monitoring, wound management, respiratory and nutritional support, infection control, and in severe cases, addressing sepsis and multiple organ failure. Accelerating wound recovery is paramount to mitigate burn related complications like hypertrophic scarring and joint contractures. Evaluation of burn severity, typically done via



the rule of nines or Lund and Browder chart, guides fluid and nutritional therapy. Assessing burn depth is crucial for determining appropriate conservative or surgical measures, distinguishing between epidermal, superficial partial-thickness, deep partial-thickness, and full-thickness burns. Effective burn care mandates a thorough evaluation, assessment, and treatment approach. While superficial and partial-thickness burns may resolve spontaneously, deeper burns often require prompt surgical intervention to prevent complications and prepare the wound bed for tissue coverage. Infection stands as a primary culprit for morbidity and mortality in extensive burns, leading to delayed healing and systemic infections. Diverse topical therapies, ranging from antibiotic creams to silver/iodine-releasing dressings, are utilized in burn wound management. Moreover, certain medications like insulin and phenytoin, originally designed for unrelated conditions, exhibit wound-healing properties and are increasingly utilized in burn care. Phenytoin, initially indicated for seizure management,<sup>1,2</sup> is linked with gingival overgrowth<sup>3</sup> and mild skin and skull thickening, suggesting its potential in wound healing due to its impact on connective tissue stimulation.

## MATERIALS AND METHODS

The case report was conducted at the JIPMER tertiary burn care center, focusing on a 70-year-old female presenting with thermal burns affecting the gluteal region (Fig. 1). Topical phenytoin therapy was initiated within 48 hours post-admission

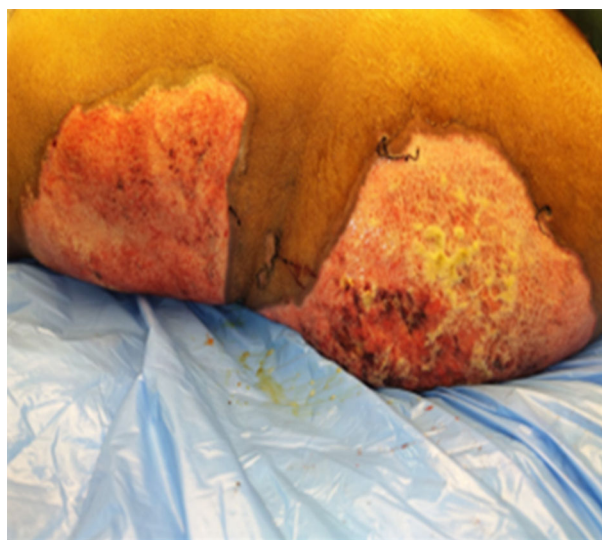


Fig. 1: Showing condition of thermal burns over gluteal region at time of presentation BJWAT score 48

(Fig. 2). Before commencing phenytoin therapy, the surface area of the raw wound was assessed using digital planimetry software, and tissue cultures were obtained. Topical phenytoin was applied every third day until the skin grafting, or resolution of the burn wound. Intravenous phenytoin solution, ranging from 100-300 mg (50mg/1ml), was dispersed over the wound surface and covered with Vaseline gauze dressings. Patient underwent monitoring for wound discharge, pain intensity, granulation tissue formation, and wound contraction every three days. Additional systemic support, such as nutritional supplementation, antibiotics, and analgesics, was administered as deemed necessary for individual patient care.

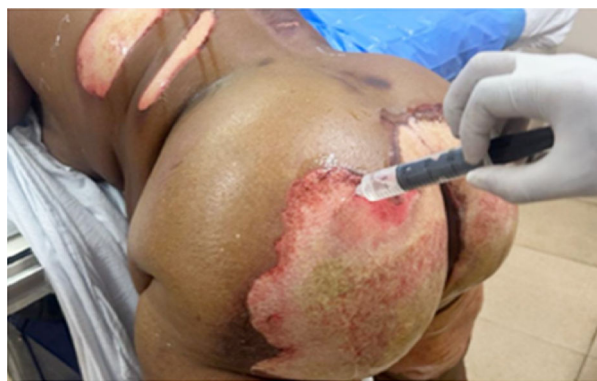
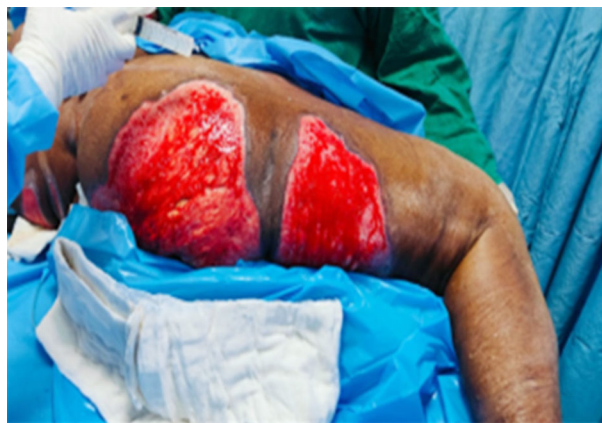
Fig. 2: Showing application of phenytoin solution over the thermal burns

## RESULTS

This investigation is a case report involving a 70-year-old female with thermal burns encompassing approximately 15% of her body surface area, primarily due to accidental injuries affecting the gluteal region. Intravenous phenytoin solution was administered over 5-7 sessions. Substantial progress in wound healing was evident as in Fig. 1 and 3 with fall in BJWAT score from 48 to 34. Wound bed preparation was characterized by heightened granulation tissue formation and re-epithelialization, assessed through digital planimetry software to quantify wound contraction (Fig. 3). Gradual reduction in wound discharge from moderate to mild was observed, alongside a notable decrease in subjective pain perception from severe to mild/no pain. She reported experiencing a mild burning sensation during phenytoin application, lasting only briefly. No systemic or local adverse effects were documented in this patient.



**Fig. 3:** Shows improvement in the condition of thermal burns three sessions after application of topical phenytoin solution BJWAT Score - 34

## DISCUSSION

Phenytoin, primarily acknowledged for its antiepileptic attributes, has emerged as a promising agent in fostering wound healing across a spectrum of conditions, including diabetes ulcers, decubitus ulcers<sup>4,5</sup>, traumatic ulcers<sup>6,7</sup>, venous ulcers<sup>8</sup>, tuberculous ulcers, epidermolysis bullosa, and burns.<sup>9</sup> Its multifaceted mechanisms encompass augmentation of neovascularization, proliferation of myofibroblasts and fibroblasts, synthesis and deposition of collagen, extracellular matrix assembly, and modulation of growth factors<sup>10</sup> and their mediators. Phenytoin exerts additional benefits by mitigating edema, wound exudate, bacterial load, and pain while facilitating re-epithelialization. Although the exact mechanism remains elusive, it is postulated to involve the upregulation of platelet-derived growth factor gene expression in monocytes and macrophages, alongside an overall inhibitory impact on collagenase. The topical administration of phenytoin ensures targeted delivery to the wound site while minimizing systemic repercussions. Diverse formulations, including powdered tablets, saline or IV solutions, creams, ointments, lotions, and aerosols, are available for wound application. Investigations by Firmino *et al.* have elucidated the advantageous effects of topical phenytoin in wound healing and grafting preparation across various ulcer types. Carneiro *et al.*'s comparative research has underscored the efficacy of topical phenytoin versus silver sulfadiazine in acute burn treatment, emphasizing substantial pain reduction with phenytoin application. Furthermore, another prospective randomized study by Carneiro *et al.* has

emphasized the favorable effects of topical phenytoin in expediting wound healing, diminishing pain and discharge in chronic leg ulcers, findings in line with observations in acute burn wound management.

## CONCLUSION

Our study delved into the adjunctive use of topically administered phenytoin, revealing a notable progression in wound contracture, wound bed preparation, diminished discharge, and alleviated pain, collectively expediting the process of wound healing. Moreover, select cases exhibited a bacteriostatic effect. Nevertheless, it is paramount to conduct additional controlled trials to validate these observations and ascertain the efficacy of phenytoin as an adjunctive intervention in wound management.

## REFERENCES

1. Meritt HH, Putnam TJ. Sodium diphenylhydantoinate in the treatment of convulsive disorders. *JAMA*. 1938;111:1068-73.
2. Silverman AK, Fairley J, Wong RC. Cutaneous and immunologic reactions to phenytoin. *J Am Acad Dermatol*. 1988;18:721-41.
3. Bethesda MD. ASHP drug information 2001. Vol. 3. American Society of Health System Pharmacists; 2001. pp. 78-79
4. el Zayat SG. Preliminary experience with topical phenytoin in wound healing in a war zone. *Mil Med*. 1989;154:178-80.
5. Rhodes RS, Heyneman CA, Culbertson VL, Wilson SE, Phatak HM. Topical phenytoin treatment of stage II decubitus ulcers in the elderly. *Ann Pharmacother*. 2001;35:675-81.
6. Simpson GM, Kunz E, Slafta J. Use of sodium diphenylhydantoin in treatment of leg ulcers. *N Y State J Med*. 1965;65:886-8.
7. Modagheh S, Salehian B, Tavassoli M, Djamshidi A, Rezai AS. Use of phenytoin in healing of war and non-war wounds. A pilot study of 25 cases. *Int J Dermatol*. 1989;28:347-50.
8. Pendse AK, Sharma A, Sodani A, Hada S. Topical phenytoin in wound healing. *Int J Dermatol*. 1993;32:214-7.
9. Lodha SC. New application of an old drug: topical phenytoin for burns. *J Burn Care Rehabil*. 1991;12:96.
10. Ramalingam A, Saravana K, Sekar A. A study of topical phenytoin sodium in diabetic foot ulcer healing. *Ann Int Med Den Res*. 2017;3:SG43-8.