

## Spectrum of Pulmonary Histopathological Lesions: A Study of 191 Medicolegal Autopsies

Sarita Dakhure<sup>1</sup>, Pragati Phulgirkar<sup>2</sup>

<sup>1,2</sup>Assistant Professor, Department of Pathology, Government Medical College Aurangabad, Maharashtra 431004, India.

### Abstract

**Background:** Autopsy is an important and most useful way to find out the condition of internal organs in which a thorough examination is performed on a body after death to evaluate disease or injury that may be present and to determine the cause and manner of a person's death. **Material & Methods:** This retrospective study was carried out in the Department of Pathology. Tissue pieces from lungs, retrieved at the time of autopsy, were preserved in 10% formalin. These were processed and paraffin sectioning was done followed by Haematoxylin and Eosin staining. The sections were then examined microscopically. **Results:** Out of 191 specimens of lungs from autopsy subjects, 142 cases (74.3%) were males and 49 cases (25.6%) were females with maximum numbers of cases, in age group of 16-30 years were 73 cases (38.2%). In our study, congestion and edema were the commonest findings and seen in 72 cases (37.69%). Granulomatous (Tuberculosis) lesion was seen in 7 cases (3.6%) and Pneumonia was seen in 15 cases (7.8%). There was only one case of malignancy. **Conclusion:** In medicolegal autopsies, the histopathological examination helps in establishing the final cause of death. Gross and histopathological study of lung in medicolegal autopsies may quite often reveal some natural disease and its relative contribution towards death.

**Keywords:** Autopsy; Pneumonia and tuberculosis.

### Corresponding Author:

**Pragati Phulgirkar**, Assistant Professor,  
Department of Pathology, Government  
Medical College Aurangabad, Maharashtra  
431004, India.

E-mail: [pphulgirkar@gmail.com](mailto:pphulgirkar@gmail.com)

Received on 05.08.2019,

Accepted on 04.09.2019

### How to cite this article:

Sarita Dakhure, Pragati Phulgirkar. Spectrum of Pulmonary Histopathological Lesions: A Study of 191 Medicolegal Autopsies. Indian J Pathol Res Pract. 2019;8(5):569-574.

### Introduction

Autopsy is a medical procedure that consists of a thorough examination performed on a body after death, to evaluate disease or injury that may be present and to determine the cause and

manner of a person's death.<sup>1,2</sup> An autopsy may be required in deaths that may have medical and legal issues. Examination of all the three cavities of body including cranium, thorax and abdomen are an essential part of autopsies. In thorax, lungs examination is the most important part of both the



This work is licensed under a Creative Commons  
Attribution-NonCommercial-ShareAlike 4.0.

medicolegal as well as clinical autopsies. The lungs are involved in various kinds of inflammatory, neoplastic and other lesions, but they are secondarily involved in almost all form of terminal diseases. Present days air pollution, environmental inhalants and chemical cum toxic substances become uncontrollable worldwide.<sup>3</sup> Millions of people around the world suffer from preventable chronic respiratory diseases.<sup>4</sup> A large number of conditions that involve the parenchyma of lung are associated with inflammation, fibrosis or granulomatous reactions. Pathologic examination of autopsy lungs gives valuable information such as various stages of fibrosis, including early patchy fibrosis and honeycombing lesions, and their distribution and progression in the lungs. Tuberculosis (TB) today remains one of the world's most lethal infectious diseases.<sup>5</sup> Despite the availability of effective treatment for most cases, tuberculosis is still a cause of death in our environment. Some cases of active tuberculosis are not identified until after the patient had died and an autopsy has been performed.<sup>6</sup> Postmortem examination of lung specimen can increase the overall proportion of pneumonia cases with a definitive diagnosis and importantly provide information that increases our understanding of the various causes of pneumonia.<sup>7</sup>

### Aims and Objectives

The aim of this study was to analyse the findings lung tissue received in autopsy specimens, to determine the underlying diseases and to study the prevalence of lung diseases in medicolegal autopsies, confirmed by histopathological examination.

### Materials and Methods

The retrospective present study was conducted on lung specimens of 200 routine autopsies received in the department of pathology, Government Medical College, Aurangabad, Maharashtra to find out the frequency of various pulmonary lesions in autopsy. The medical history and clinical history was traced. The pieces of lungs were fixed in 10% formalin, weighed and dimensions measured. Grossly pieces of lungs were examined for color, volume, consistency, presence of scarring, fibrosis, consolidation, nodules, infarction, congestion, granuloma/abscess formation, status of bronchi & pleura & findings were recorded. A minimum of two sections per lung were studied. All the histological sections were stained in H & Estain & mounted. All the histological sections were examined microscopically & findings were recorded and tabulated.

### Results

In the present study a total of 200 specimens of lungs were studied during a period of January 2018 to January 2019 along with relevant clinical details and autopsy findings. Histopathological examination was carried out in each case. After thorough histopathological examinations various pathological lesions were identified in 185 (92.5%) cases while in 6 (3%) cases no significant pathology was identified and in 9 (4.5%) cases the tissue was autolysed, those cases were excluded from the study (Table 1).

**Table 1:** Status of lung tissue on histopathology.

Parameters	New born-15 yrs	16-30 yrs	31-45 yrs	46-60 yrs	>61 yrs	Total
Normal lung	-	3	-	2	1	06
Diseased lung	13	70	50	35	17	185
Lysed lung tissue	1	3	2	2	1	09
<b>Total</b>	<b>14</b>	<b>76</b>	<b>52</b>	<b>39</b>	<b>19</b>	<b>200</b>

**Table 2:** Distribution of lesions in males and females in cases of medicolegal autopsy

S. No	Pulmonary lesion	No. of cases (%)	Male	Female
1.	Interstitial pneumonia	28 (14.6%)	22	06
2.	Emphysematous lesions	06 (3.1%)	03	03
3.	Pulmonary edema	38 (19.8%)	28	10
4.	Congestion	34 (17.8%)	28	06
5.	Chronic venous congestion	22 (11.5%)	18	04
6.	Atelectasis	04 (2%)	03	01
7.	Intra-alveolar hemorrhage	23 (12%)	17	06
8.	Red infarct	07 (3.6%)	05	02

S. No	Pulmonary lesion	No. of cases (%)	Male	Female
9.	Granulomatous(Tuberculous) lesions	07 (3.6%)	04	03
10.	Lobar Pneumonia	15 (7.8%)	09	06
11.	Adenocarcinoma	01 (0.5%)	01	00
12.	Normal lung	06 (3.1%)	04	02
	<b>Total</b>	<b>191</b>	<b>142</b>	<b>49</b>

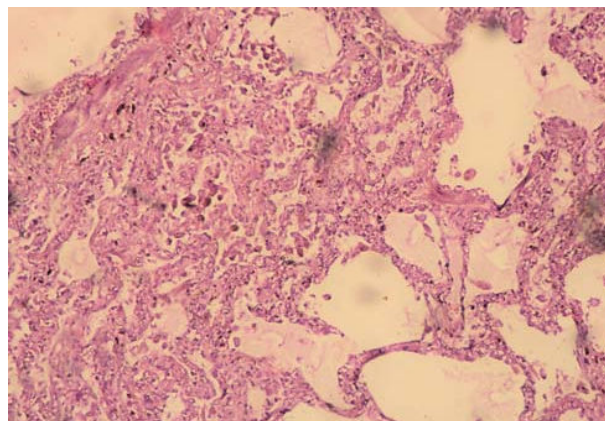
Out of total 191 cases, 142 cases (74.3%) were males and 49 cases (25.6%) were females. The male to female ratio was 2.8:1 (Table 2). The age ranged from 2 days to 81 years. There were 6.8% cases below 15 years of age. Maximum numbers of cases, in age group of 16–30 years were 73 cases (38.2%) followed by in age group 31–45 years were 50 cases (26.2%) followed by age group of 46–60 years were 37 cases (19.4%) (Table 3)

Interstitial Pneumonia was seen in 28 cases (14.6%) (Table 2) Among which 22 were males and 6 were females. Emphysematous lesions were seen in 6 cases (3%), out of which 3 were males and 3 were

females. Pulmonary edema was seen in 38 cases (19.8%), congestion was seen in 34 cases (17.8%), Granulomatous (Tuberculous) lesions seen in 7 cases (3.6%), out of which 4 were males and 3 were females. Pneumonia was seen in 15 cases (7.8%), out of which 9 were males. The cause of death was due to extra pulmonary pathology, but the lungs were showing associated findings like chronic venous congestion in 22 cases (11%), atelectasis was seen in 4 cases (2%), intra-alveolar hemorrhage was seen in 23 cases (12%) and red infarct was seen in 7 cases (3.6%). There was only one case (0.5%) of malignancy which was a case of adenocarcinoma in a Male.

**Table 3:** Age wise distribution of lung lesions in cases of medicolegal autopsy

S. No.	Pulmonary lesion	New born-15 yrs	16-30 yrs	31-45 yrs	46-60 Yrs	>61 yrs	Total
1.	Interstitial pneumonia	3	9	14	2	-	28
2.	Emphysematous lesions	2	-	-	3	1	06
3.	Pulmonary edema	-	13	10	11	4	38
4.	Congestion	4	14	8	2	6	34
5.	Chronic venous congestion	-	6	6	7	3	22
6.	Atelectasis	-	2	-	2	-	04
7.	Intra-alveolar hemorrhage	2	15	2	1	3	23
8.	Red infarct	-	3	2	2	-	07
9.	Granulomatous(Tuberculous) lesions	-	3	2	2	-	07
10.	Lobar Pneumonia	2	5	6	2	-	15
11.	Adenocarcinoma	-	-	-	1	-	01
12.	Normal lung	-	3	-	2	1	06
	<b>Total</b>	<b>13</b>	<b>73</b>	<b>50</b>	<b>37</b>	<b>18</b>	<b>191</b>



**Fig. 1:** CVC lung shows Hemosiderin laden macrophages. (H&E: 40x)

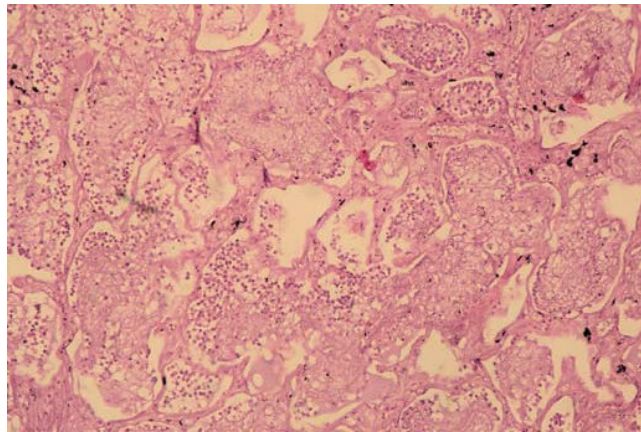


Fig. 2: Lobar pneumonia shows abundant acute inflammatory infiltrate, focal areas of edema and congestion.(H&E: 40x)

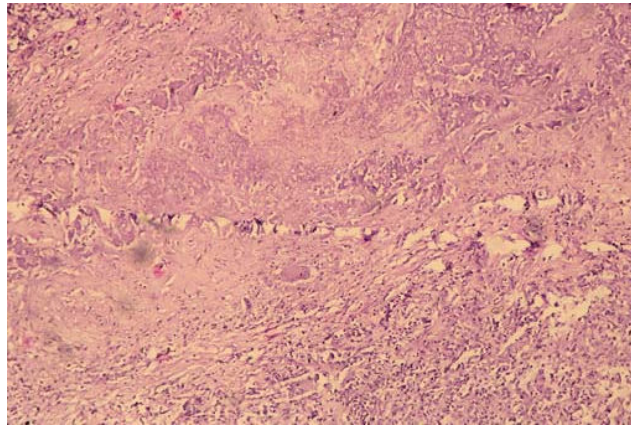


Fig. 3: Shows caseous necrosis with Langhans giant cells. (H&E: 40x)

## Discussion

Medicolegal autopsies are a mandatory legal requirement in un-natural deaths to assist the law. In most of the cases are with unknown history of past illness. Moreover, in some cases with nonfatal injuries, natural diseases may be the actual cause of death, which may have been precipitated by the assault. The facilities for medicolegal autopsies are available across all districts of our country.<sup>8</sup> The autopsy, if combined with relevant details and histopathological examination, is of great value in establishing reasons which led to death.<sup>9</sup> Pathological examination of autopsy organ is important diagnostic tool to know the spectrum of various disease, to understand disease process or pathogenesis, to assess various morphological pattern of same disease and provide opportunity to discover new disease.

Kandy NC *et al.*, quoted that even in the era of high-tech medicine the autopsy remains an

important tool for quality assessment of clinical diagnoses.<sup>10</sup> As far as lungs are concerned, these were normal in only 9.80% of the total number of autopsies in their series. In our retrospective study of 191 cases, in 6 cases (3.1%) histopathological findings were unremarkable and all were adults between 16 to >60 years age group, signifying the healthy status of lungs in the adults.

Bal MS *et al.*, in their series of 150 cases had 19 autolysed samples and 11 cases with normal lung tissue.<sup>11</sup> Unlike their series we had much lower percentage of cases with no remarkable pathology. The very low number of autolysed samples in our series was probably due to availability of autopsy facilities in the hospital. There was male predominance in our series with males and females accounting for 142 (74.3%) and 49 (26.5%) respectively. Similar sex distribution has also been observed by many other authors.<sup>12,13</sup>

In our study, congestion and oedema was the commonest finding and was seen in 72 cases. This

was 37.69% of the total lung cases with pathological changes. Similar observations were also observed by many authors in their series.<sup>13,14</sup> This could be a death related change or secondary involvement of lungs in all forms of terminal events due to cardiovascular causes. The second commonest finding was Interstitial pneumonia in our series. It was seen in 28 cases (14.6%). Such changes could be due to pollution, smoking or any restrictive lung disease leading to fibrosis.

We had 6 cases (3.1%) of emphysema in our series of 191 cases. Among those two were children and rest four were in age group of more than 46 years. All of these cases had urban background. The two children were known cases of bronchial asthma. Selvam V *et al.*, reported 54 cases (50%) of emphysematous changes in the lungs in their series of 108 cases.<sup>13</sup>

The cause of death was due to extra pulmonary pathology, but the lungs were showing associated findings like chronic venous congestion (CVC) in 22 cases (11%). In Patel CB *et al.*, 92 cases (26.44%) of CVC in their series of 348 cases.<sup>15</sup> Intra alveolar haemorrhages were seen in 12% of the cases in our study while Soeiro *et al.* observed it in 10.4% cases.<sup>16</sup> Hanmante *et al.* observed alveolar haemorrhages in 5.8% of cases in their study population.<sup>17</sup>

In this study, we came across 15 cases (7.8%) of Pneumonia. Seven cases were seen in children and young adults and 8 cases in middle aged male. Kandy NC *et al.*, found 26.3% cases of pneumonia on histopathology of lung samples in their series of 51 cases.<sup>10</sup>

Granulomatous inflammation was seen in 7 cases (3.6%) in present series. Caseous necrosis and epithelioid cell granulomas were seen in all these cases, however only three were positive for AFB on ZN staining.

Thus autopsy confirmed three cases having definitive diagnosis of pulmonary tuberculosis and another four with high probability of having pulmonary tuberculosis during their life time. Similar results were seen in studies conducted by Garg M, *et al.*<sup>18</sup>, In their study granulomatous inflammation was an incidental finding in majority of the cases (6 out of 8) not correlating with postmortem findings or history. Kandy NC *et al.*, found tuberculous changes in lungs confirmed by histopathology in 15.78% cases in their series of 51 cases.

In our study, only 1 case of adenocarcinoma was seen, which was comparable to studies done by Manjeet *et al.*<sup>11</sup> and Chauhan *et al.*<sup>4</sup>

## Conclusion

In medicolegal autopsies, the histopathological examination helps in establishing the final cause of death. Gross and histopathological study of lung in medicolegal autopsies may quite often reveal some natural disease and its relative contribution towards death. Facilities of histopathological examinations of the autopsied tissues are available only in small number of institutions which often leads to delay and damages to the autopsy tissue samples. Also, factors like inadequate sampling, improper fixation and failure to send representative sections leads to contradiction between autopsy finding and histopathological examination. This study highlights various lesions in lungs which were either incidental or direct cause of death. Pulmonary edema was a common finding in our study; even though the co-morbid conditions of the lung were not directly responsible for the deaths, they could have contributed to these deaths up to some extent.

Source(s) of support: Nil.

Acknowledgement: Nil

If the manuscript was presented as part at a meeting: Nil

Conflicts of Interest of each author/ contributor: Nil

## References

1. Tahir T, Rehman F, Anwar S *et al.* Pattern of pulmonary morphological lesions seen at autopsy. *Biomedica*. 2013 Apr-Jun;29:64-8.
2. Kurawar R and Vasaikar MS. Spectrum of histomorphological Changes in Lungs at Autopsy: A 5 Year Study. *Annals of Pathology and Laboratory Medicine*. 2017 Jan-Feb;4(1):107-12.
3. Selvambigai G, Amudhavalli S, Chakravarthi CD. Histopathological study of lung in autopsy cases: a prospective study: *Int J Res Med Sci*. 2016 Nov;4(11):4816-19.
4. Chauhan G, Agrawal M, Parghi TB. Spectrum of histopathological lesions in lung autopsy. *Journal of Research in Medical and Dental Science*. 2015 Apr-Jun;3(2):109-12.
5. Abbas K, Aster, Robbins, Cotran. *Pathologic basis of disease*. South Asia Ed. Vol 2 Elsevier: 2014.
6. Udayashankar SK, Shashikala P, Kavita GU. Histomorphological Pattern of Lung in Medicolegal Autopsies. *International Journal*

- of Science and Research. 2015 Jul;6(14):1937-39.
7. Gareth DH, Bunthi TC, Chizoba B. *et al.* The Role of Postmortem Studies in Pneumonia Etiology Research. *Clin Infect Dis.* 2012;54(2):165-71.
  8. Yadwad BS. Medicolegal autopsy-what, why and how. *J Indian Med Assoc.* 2002;100(12):703-7.
  9. Nadesan K. The importance of the medico-legal autopsy. *Malays J Pathol.* 1997;19(2):105-9.
  10. Kandy NC, Pai MR, Reba Philipose T. Role of histopathology on autopsy study, an audit. *SAS Journal of Medicine.* 2015;1(3):7-15.
  11. Bal Manjeet S, Sethi PS, Suri Anil K, Bodal Vijay K, Kaur G. Histopathological pattern in lungs autopsies. *JPAFMAT.* 2008;8(2):29-31.
  12. Chauhan G, Aggarwal M, Thakkar N, Praghi B. Spectrum of lung histopathological lesions in lung autopsies. *J Res Med Den Sci.* 2015;3(2):109-12.
  13. Selvam V, Thamil Selvi R, Subramnium PM, Vijaynath V. Prevalence of common diseases in lungs and liver: A histopathological study. *Journal of Pharmaceutical and Biomedical Sciences.* 2011;12(12):1-5.
  14. Pathak A, Mangal HM. Histo-pathological examination in medico-legal autopsy. *J Indian Acad Forensic Med.* 2010;32(2):128-30.
  15. Patel C, Patel K, Vasudha M. *et al.* Pattern of histopathological lesions in lung autopsy. *Int J Res Med Sci.* 2018;6(1):279-283.
  16. Soeiro AM, Ruppert AD, Canzian M, *et al.* Demographic, etiological, and histological pulmonary analysis of patients with acute respiratory failure: a study of 19 years of autopsies. *Clinics.* 2011;66(7):1193-7.
  17. Hanmante RD, Chavan YH, Mulay PS, *et al.* Histopathological patterns of Lung lesions in Autopsy cases. *International Journal of Advances in Health Sciences.* 2014;1(1):15-9.
  18. Garg M, Aggarwal AD, Singh S, *et al.* Tuberculous lesions at autopsy. *J Indian Acad Forensic Med.* 2011;33(2):116-19.
- 
-