

Anatomical Study of Origin of Sinuatrial Nodal Artery in Human Cadaveric Heart Specimens

Savitha V¹, Vidya H K²

How to cite this article:

Savitha V, Vidya H K/Anatomical Study of Origin of Sinuatrial Nodal Artery In Human Cadaveric Heart Specimens/ Indian J Anat. 2021;10(2):52-55.

Author's Affiliation: ¹Assistant Professor, Department of Anatomy, Adichunchanagiri Institute of Medical Sciences, Adichunchanagiri University, BG Nagara, Nagamangala Taluk, Mandya District, Karnataka 571448, India, ²Associate Professor, Department of Anatomy, Shridevi Institute of Medical Sciences and Research Hospital, Tumkur, Karnataka 572106, India.

Corresponding Author: Savitha V, Assistant Professor, Department of Anatomy, Adichunchanagiri Institute of Medical Sciences, Adichunchanagiri University, B G Nagara, Nagamangala Taluk, Mandya District. Karnataka 571448, India.

E-mail: doctorsavithav@gmail.com

Abstract

Background: Sinoatrial Nodal artery is an artery which supplies the Sinoatrial node, the natural pacemaker center of the heart, usually a branch of right coronary artery but also from left coronary artery in variable percentage in different population.

Aim: The aim of the study was To establish anatomical origin of sinoatrial Nodal artery , from Right coronary artery or left coronary artery in Indian human cadavers.To observe relation of Sinuatrial nodal artery to the root of Superior Vena cava

Materials and Methods: The study was carried out on 64 formalin fixed Adult Human Cadaveric Heart Specimens of Indian population obtained from department of Anatomy, Sridevi Medical College, Tumkur and Adichunchanagiri Institute of Medical Sciences B. G. Nagara, Karnataka, India. Specimens with gross congenital anomalies were excluded from the study. The coronary arteries were dissected for the origin of sinoatrial Nodal artery.

Results: Out of total 64 cases studied, sinoatrial nodal artery was originating from right coronary artery in 34 (53.12 %) hearts, from left coronary artery in 17 (26.56 %) while in remaining 13 (20.31) hearts SA nodal artery was arising from both right and left coronary arteries. When it is arising from left coronary artery it is a branch of left circumflex artery rather than the main trunk.

Keywords: Sinoatrial Nodal Artery; Right Coronary Artery; Ischemic; Cadaveric Heart.

Conclusions: The data extracted from this study will be helpful for cardiac surgeons during atrial surgical interventions, Radiologists and Anatomists. Further studies are needed in Indian population in relation to SA Nodal Artery. Study of origin and distribution of sinoatrial nodal artery helps cardiologist and cardiac surgeons to understand the ischemic etiology of sinus node diseases and corrective steps needed.

Introduction

The sinoatrial nodal artery is anatomically significant, because it is the landmark for the identification of the sinoatrial node (SA node), which is the natural pacemaker of heart. The artery of SA node is an atrial branch distributed to both atria, mainly the right. Origin of the SA nodal artery is highly variable. In most of the cases it is a branch of right coronary artery (RCA), but in 35% cases it may arise from circumflex branch of left coronary artery (LCA). During its course, SA nodal artery (SANA) passes back in the groove between right auricular appendage and aorta. Then it divides into branches around the base of superior vena cava¹.

The artery supplying sinoatrial node mostly arises from the first segment of the right coronary artery, from its initial 1-2 cm. First branch of right coronary artery is Conal artery and second branch of the RCA is Sinoatrial Nodal artery. Sinoatrial Nodal artery also arises from left coronary artery (LCA). When originating from the LCA the artery is most



commonly a branch of the left circumflex artery rather than from the trunk of the artery. Origin of sinoatrial nodal artery from left main trunk has also been reported in few cases. Gray's anatomy describes the artery of the sinoatrial node as atrial branch, distributed largely to the myocardium of both atria, mainly the right. Accurate identification of coronary arterial branches is important in the interpretation and description of coronary arteries, especially if surgery or angioplasty is considered².

The aim of the present study is to assess the normal anatomy and variations of SA nodal artery by studying number, origin, course and relation with superior vena cava.³

Materials and Methods

The study was carried out on 64 formalin fixed Adult Human Cadaveric Heart of Indian population obtained from department of Anatomy Shridevi Institute of Medical Sciences and Research Hospital, Tumkur and Adichunchanagiri Institute of Medical Sciences, B G Nagar, Karnataka. The study was conducted for a period of 2 years from 2018 to 2020. Human heart specimens of both sexes between the age of 18 to 80 years were included in the study. Any injured, damaged or pathological heart samples were excluded from the study. The specimens were numbered serially & fixed in 10% formaline for a week. Branches of coronary arteries were dissected in the conventional method after removing the epicardial fatty tissue. The details of origin, course & relation with Superior vena cava were noted.

Results

As shown in Table 01 and Figure 01 Out of 64 heart specimens, the SA nodal artery was arising as a single branch from RCA in 34 specimens (53.12%) as shown in Figure 2, from left circumflex artery in 17 (26.56 %)as shown in Figure 3 and in 13 (20.31%) specimens as shown in Figure 4 SANA was arising both RCA and LCX.

Sino atrial nodal artery was related to posterior aspect of Superior vena cava in all cadaveric heart specimens.

Table 1: Origin of SA Nodal Artery.

| Origin of SA nodal artery | RCA | LCA | Both |
|---------------------------|--------|--------|--------|
| No of specimens (64) | 34 | 17 | 13 |
| Percentage | 53.12% | 26.56% | 20.31% |

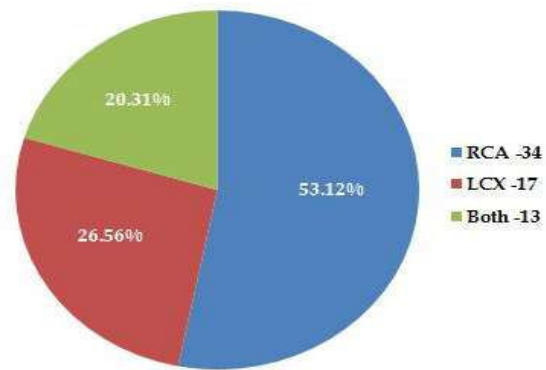


Fig. 1: Origin of SA Nodal Artery (RCA - Right coronary artery, LCX -Circumflex branch of Left coronary artery).

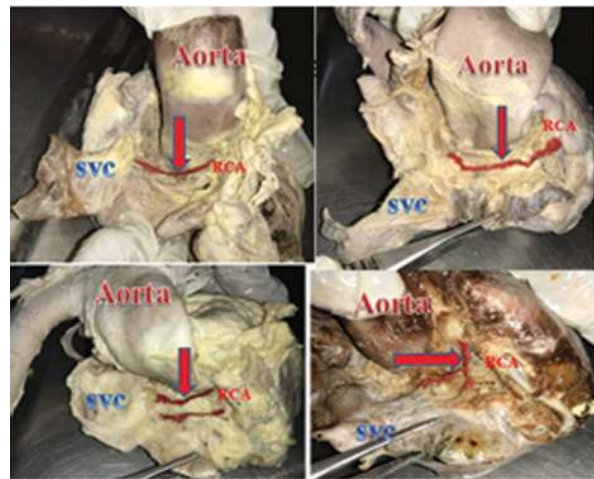


Fig. 2: SA Nodal artery arising from Right coronary artery.

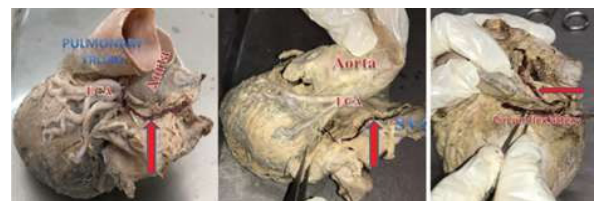

Fig. 3: SA Nodal artery arising from Circumflex branch of Left coronary artery.

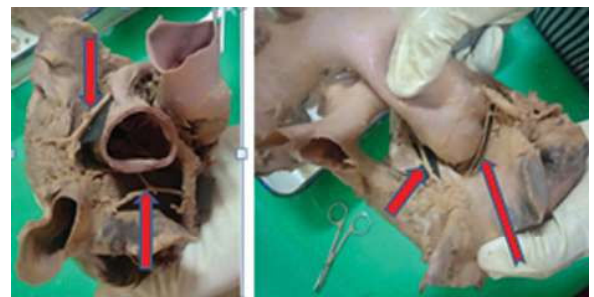


Fig. 4: SA Nodal artery arising from both right coronary and Circumflex branch of Left coronary artery.

Table 2: Comparison of percentage wise arterial distribution pattern of Sino atrial nodal artery origin.

| Sl. No | Author | Year | Sample size | RCA (%) | LCA (%) | Both (%) |
|--------|--------------------------|------|-------------|---------|---------|----------|
| 1 | Denis Berdajs (3) | 2003 | 50 | 66 | 34 | - |
| 2 | Anjali S Sabnis (4) | 2012 | 110 | 90 | 10 | - |
| 3 | Vidyashambhava Pare (5) | 2017 | 60 | 57 | 25 | 17 |
| 4 | Mitchell Lee Milanuk (6) | 2017 | 60 | 76.7 | 18.3 | ? |
| 5 | Priti Sinha (2) | 2018 | 50 | 78 | 21.27 | |
| 6 | Rekha Sinha (7) | 2018 | 50 | 76 | 16 | - |
| 7 | Lakshmi Prabha R (8) | 2019 | 55 | 64 | 34 | 2 |
| 8 | Present study | 2020 | 64 | 53.12 | 26.56 | 20.31 |

Discussion

The present study of sinoatrial nodal artery in Indian cadaveric hearts, 34 out of 64 hearts (53.12%) received SA nodal artery from the right coronary artery, 17 out of 64 hearts (26.56 %) from the left coronary artery and 13 out of 64 hearts (20.31%) from both right coronary artery, Circumflex branch of Left coronary artery.⁴ When SA nodal artery was a branch of the left coronary, it arised most commonly from the circumflex branch of the left coronary artery and not from the main trunk of the artery.⁵ Thus a constant pattern of blood supply to the SA node comparable with that given in literature and other published reports was observed. Similar observations noted by a study done by Vidya shambhava Pare during 2017 where they have found in SA nodal artery arising from right coronary in 57% population, from circumflex branch of Left coronary in 25% population and from both right and left coronary in 17% population, which is almost near to values observed in the present study.⁶ When we compare with remaining studies incidence of SA nodal artery arising from right coronary is higher in all studies and incidence of SA nodal artery arising from circumflex branch of left coronary is lower than the present study (2,3,4,6,7) as shown in Table - 02.

Gray's anatomy states that the artery of the sinoatrial node is an atrial branch, distributed largely to the myocardium of both atria, mainly the right.⁷ Its origin is variable; it came from the circumflex branch of the left coronary in 35% and from right coronary artery in 65% cases (1). Snell's anatomy has a similar view, stating that the artery of the sinoatrial node supplies the node and the right and left

atria and in 35% of individuals it arises from the left coronary artery.⁹

In cases of dual origin of SANA, the most common pattern was one branch arising from RCA and the other from LCx. Such dual supply would prevent ischaemia in vaso-occlusive disease of one of the coronary arteries.⁸ When a single artery supplies the SA node, there is more chance of ischaemia leading to sick sinus syndrome.¹⁰

Conclusion

Origin and distribution of Sinoatrial nodal artery helps Cardiologist and Cardiac surgeons to understand the ischemic etiology of sinus node diseases. The SA node is the pacemaker of the heart situated at the junction of the superior vena cava and the right atrium. The present study of Indian human cadaveric hearts the blood supply to SA node was from the sinoatrial nodal branch of the right coronary artery in 53.12% of cases, from the left coronary artery in 26.56% of cases from both in 20.31% of cases. In cases in which the SA node is supplied by the left coronary artery it is most often a branch of the circumflex artery rather than from the main trunk. SA nodal artery was related to posterior aspect of superior Vena cava irrespective of its source of origin.

Thus knowing the variations in the blood supply of SA node and study of origin and distribution of sinoatrial nodal artery helps cardiologist and cardiac surgeons to understand the ischemic etiology of sinus node diseases and corrective steps needed.

References

1. Standring S. Larynx. In: Barry K B Berkovitz (editors). Gray's Anatomy. 40th Edition. London: Elsevier Charchill Livingstone: 2006. The anatomical basis of clinical practice; pp. 577-593.
2. Priti Sinha, Sanjeev Saxena 2, Satyam Khare 1, Shilpi Jain 1, Rashmi ghai, Ramkumar Kaushik Anatomical study of origin of Sino atrial nodal artery in human cadaveric hearts. Int J Anat Res 2018, Vol 6(1.1):4857-60.
3. Denis Berdajs, MD, Lajos Patonay, MD, DD, and Marko I. Turina, MD The Clinical Anatomy of the Sinus Node Artery, 2003: The Society of Thoracic Surgeons Published by Elsevier Inc. 732-735.
4. Anjali S Sabnis, Nazmeen N Silotry : Anatomical variations of nodal arteries in human hearts: Journal of Evolution of Medical and Dental Sciences 2012, vol 1(4):482 - 486.
5. Vidyashambhava Pare, Roopa Kulkarni, Sheela G. Nayak, Interesting observations on Sinoatrial nodal artery: A clinical perspective: International

- journal of anatomy and research 2017, vol 5(1): 3372-78.
6. Mitchell Lee Milanuk A Cadaveric Study of Coronary Artery Variations University of Nebraska Medical Center Digital Commons@UNMC Theses & Dissertations 1-74.
 7. Rekha Sinha, Mundrika PD, Sudhanshu. Assessment of origin of Sinoatrial nodal artery in human cadaveric hearts: International Journal of Sino atrial nodal artery in human cadaveric hearts 2018, Vol 4(9): 144-146.
 8. Lakshmi Prabha R, Ramesh P, Khizer Hussain Afroze, Kavyashree A N, Anupama D. Study of Arterial Supply to Sioatrial Node in Normal Human Hearts: Research Journal of Medical and Allied Health Sciences 2019, Vol 2(1): 7-10.
 9. B PejkoVIC, I Krajnc, F anderhuber and D Kosutic. Anatomical aspects of the Arterial blood supply to the sinuatrial and Atrioventricular Nodes of the Human Heart: The Journal of International Medical Research 2008, 691-698.
 10. Raniprabha Sukumaran, usha Krishnan Kuruppath. A Study on Anatomy and variations of Sinoatrial nodal Artery Journal of Evolution of Medical and Dental Sciences 2017, Vol 6 (71): 5065-5068.

