

## A Histo-Morphological Study on the Effects of Aging in Human Adrenal Glands

A Sharmila<sup>1</sup>, Meeta Thomas<sup>2</sup>

<sup>1,2</sup>Assistant Professor, Department of Pathology, Pushpagiri Institute of Medical Sciences & Research Center, Thiruvalla, Kerala 689101, India.

### Corresponding Author:

**Meeta Thomas**, Assistant Professor, Department of Pathology, Pushpagiri Institute of Medical Sciences & Research Center, Thiruvalla, Kerala 689101, India.

E-mail: [dr.meetathomas@gmail.com](mailto:dr.meetathomas@gmail.com)

Received on 27.06.2019,

Accepted on 24.07.2019

### Abstract

*Background:* Aging in humans is characterised by a selective decline in circulating levels of adrenal androgens, whose production in Zona Reticularis (ZR) of adrenal is enhanced by Cytochrome-B5 (CytB5). *Objectives:* The present work aims to determine the histo-morphological effects of aging and CytB5 distribution in the adult human adrenal cortex during the aging process. *Methods:* This is an analytical study in which human adult adrenal glands were obtained at autopsy from 39 men and 33 women who suffered a sudden death. The right & the left adrenal glands were received separately and Gross findings, microscopic features and Immunohistochemistry with CytB5 were studied in detail. *Results:* The mean of weight, length & breadth of both Right & Left adrenal glands were found to decrease with increasing age, which is statistically significant, but without significant difference in the thickness of adrenal glands. The thickness of ZR and expression of CytB5 also showed statistically significant reduction with increasing age. The area which was histologically identified as ZR on H & E staining, corresponded well to the area of CytB5 positivity on IHC.

**Keywords:** Cytochrome B5; Adrenal; Aging.

### How to cite this article:

A Sharmila, Meeta Thomas. A Histo-Morphological Study on the Effects of Aging in Human Adrenal Glands. Indian J Pathol Res Pract. 2019;8(5):519-525.

### Introduction

The two components of the adrenal gland are the adrenal cortex and adrenal medulla. The cortex has been divided into 3 areas based on light microscopy findings from the capsule inward, the zona glomerulosa (ZG), the zona fasciculate (ZF),

and the zona Reticularis (ZR) forming the typical zonation pattern of the adrenal cortex.

The functional significance of this morphologic separation is questionable, but ZG is the site of aldosterone production, and the ZF and ZR synthesize glucocorticoids and sex hormones.



Aging in humans is characterized by a selective decline in circulating levels of adrenal androgens, especially dehydroepiandrosterone (DHEA) and dehydroepiandrosterone sulfate (DHEAS).<sup>1-5</sup> Reductions in the adrenal androgen production are clinically relevant because they have a role in maintaining cognitive ability, bone mineral density and libido.

The production of DHEA/DHEAS is determined in part by cytochrome P450c17 (P450c17), an enzyme that catalyzes both 17-hydroxylase and 17, 20-lyase activities.<sup>6</sup>

The hydroxylase reaction is important in the formation of glucocorticoids and of intermediates in androgen synthesis. On the other hand, 17, 20-lyase activity is required for androgen production. The results of *in vivo* studies are suggestive of reduced adrenal 17,20-lyase activity in aging men and women.<sup>7</sup> 17,20-lyase activity can be modulated by Cytochrome-B5 (CytB5), an accessory protein that alters the conformation of P450c17 and enhances 17, 20-lyase independently of 17-hydroxylase activity, which subsequently increases adrenal androgen production.<sup>8-10</sup>

The present work aims to determine the histomorphological effects of aging in human adrenal gland cortex, which is determined by changes in the percentage of adrenal cortex that consisted of the Zona reticularis (ZR/Total Cortex%), and CytB5 distribution in the adult human adrenal cortex during the aging process, along with other histopathological changes in adrenal gland, to further elucidate the mechanism of decline in adrenal androgen production with aging, which can help to reduce the age-related morbidity, if early institution of androgens is given & can help in the intervention of targeted therapies in near future, which can minimize these changes.

## Materials and Methods

This is an analytical study in which human adult adrenal glands were obtained at autopsy from 39 men and 33 women who suffered a sudden death. This includes sudden death due to trauma, accidents & also sudden deaths due to myocardial infarction. Cases with prolonged hospitalisation and chronic illnesses have been excluded.

Of these tissue specimens, 20 were obtained from females & 43 from males. Of these 13 females & 21 males are in the age group of 20-40years, 4 females & 17 males are in the age group of 40-60

years and 3 females & 5 males are in the age group of 60-80years.

The material was obtained from the department of Forensic medicine, Government medical college, Kottayam. The right & the left adrenal glands were received separately and they are weighed & measured and were compared with respect to age.

All specimens were received in 10% formalin and processed by paraffin embedding. Each tissue sample chosen for analysis contained either a full-thickness cross-section of the cortex extending from the adrenal capsule to the medulla and/or a full-thickness section of the adrenal alae.

Blocks were cut serially into sections of 3 $\mu$  thickness and stained with hematoxylin and eosin and immunohistochemistry staining was performed by use of a rabbit polyclonal antiserum (diluted-used at a concentration of 1 $\mu$ g/ml) directed against human Cytochrome B5 (ab-69801).

## Quantitative image analyses

Photomicrographs of histological and immunohistochemical staining patterns of the adrenal specimens were taken with the Leica Application Suite V3, which was connected to the Leica microscope.

Quantitative assessment of the thickness of Zona Reticularis & the thickness were measured using user length.

All H & E stained slides and CytB5 slides were examined at 4X magnification and representative areas in which the full-thickness of cortex extending from the capsule to the medulla or an alae with the full-thickness of the cortex extending from the capsule to the capsule without intervening medulla were captured through the use of a digital color camera mounted to our Leica microscope. The images of the H & E-stained sections were analysed by measuring the width of ZR, recognised by standard histological features and the width of the total cortex.

For the immunoreactive distribution of CytB5, width of the cortex positive for CytB5 was measured. Three separate areas of each adrenal section were analysed in the aforementioned manner, and the average values were used. The data for the width of the zona reticularis and for the cortex immunopositive for CytB5 were normalized by expressing the width of each as a percentage of the total cortical width (ZR/TC  $\times$  100% & CYTOCHROME B5/TC  $\times$  100%).

The observations were analyzed using statistical

test ANOVA. The Pearson test was used to establish the linear correlation of each parameter (the weight of the Right & Left adrenal gland, the size of the Right & Left adrenal gland, thickness of ZR/thickness of total cortex%, Thickness of cytochrome B5 positive area/thickness of total cortex%) against age.

### Observation and Results

The year wise distribution showed that 27 cases in this study were received in the year 2012 and 36 cases were received in 2013. The results were presented as Tables (1,2) & Figures (1-8).

**Table 1:** To Show the Mean SD & Number in Each Age Group

Age Group		Weight R	Weight L	Length R	Length L	Breadth R	Breadth L
20-40 years	Mean	4.65	4.90	4.84	4.90	2.95	2.93
	N	34	34	34	34	34	34
	SD	0.60	0.58	0.38	0.30	0.47	0.30
40-60 Years	Mean	3.69	3.74	4.08	4.28	2.81	2.90
	N	21	21	21	21	21	21
	SD	0.43	0.68	0.33	0.40	0.46	0.36
60-80 years	Mean	2.88	2.91	3.31	3.44	1.95	1.95
	N	8	8	8	8	8	8
	SD	0.58	0.58	0.46	0.28	0.28	0.28
<b>Total</b>	<b>Mean</b>	<b>4.10</b>	<b>4.26</b>	<b>4.39</b>	<b>4.51</b>	<b>2.78</b>	<b>2.79</b>
	N	63	63	63	63	63	63
	SD	0.84	0.66	0.66	0.55	0.55	0.45

**Table 2:** To Show the Mean, SD & Number in Each Age Group

Age Group		Thick R	Thick L	Ihc-Width of CytB5/Tc%	H&E-Zr/Tc%
20-40 Years	Mean	1.03	1.08	40.24	40.24
	N	34	34	34	34
	Sd	0.19	0.21	5.75	5.76
40-60 Years	Mean	0.99	0.99	20.57	20.62
	N	21	21	21	21
	Sd	0.20	.10	5.08	5.05
60-80 Years	Mean	0.94	1.04	14.16	14.19
	N	8	8	8	8
	Sd	0.16	0.26	4.78	4.93
<b>Total</b>	<b>Mean</b>	<b>1.01</b>	<b>1.04</b>	<b>30.37</b>	<b>30.39</b>
	N	63	63	63	63
	Sd	0.19	0.19	12.18	12.17

ANOVA test was done & it showed that there is a decrease in the mean weight, length & breadth of both the right & the left adrenal glands, decrease in the thickness of the ZR as a percentage of the total cortex(ZR/TC%) & there is a decrease in the thickness of the Cytochrome B5 positive area, which is also expressed as a percentage of the total cortex (CytB5 /TC%) as age increases, all of which were found to be significant with a *p*-value of <0.001.

Also the region that was histologically identified as ZR corresponded well to the area of CytB5 positivity (Figs. 1-4).

But, there was no significant decrease in the thickness of both Right & Left Adrenal glands

with increasing age, with a *p*-value of 0.41 & 0.187 respectively.

Independent samples *t*-test was done to compare the right & Left adrenal glands & it showed that there is no significant difference between the right & left adrenal glands with respect to weight, length, breadth & thickness.

Another finding in our study is that the Lymphocytic infiltration & a thicker capsule are more commonly seen in the older age group, than in the younger age group

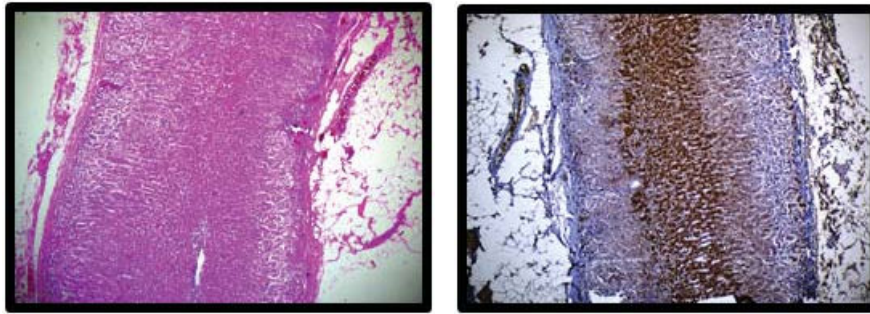
Another finding is that, in H & E-stained sections of adrenals from young adults, ZR consisted of

cells that were prominently eosinophilic and was usually found to have clearly distinguishable and smooth borders with the medulla and the adjacent ZF.

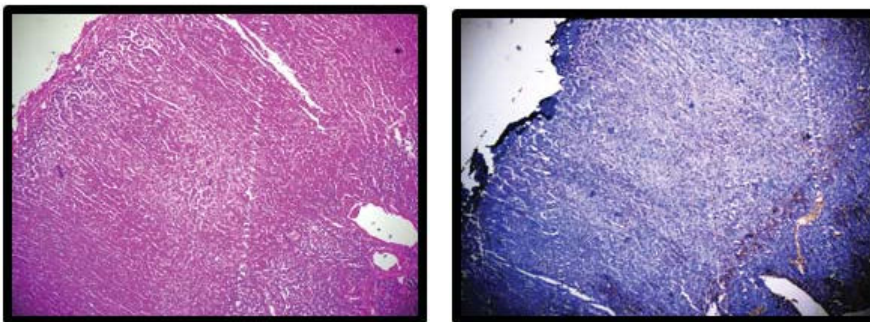
However, in adrenals from older subjects, cells that were immunopositive for CytB5 and that appeared to represent ZR cells on H & E-stained

sections occasionally were found in scattered clusters rather than as a continuous zone or band of cells (Fig. 3,4).

There was evidence for blurring of the border between ZR (CytB5-containing cells) and ZF (which we find to be negative for CytB5) in aging.



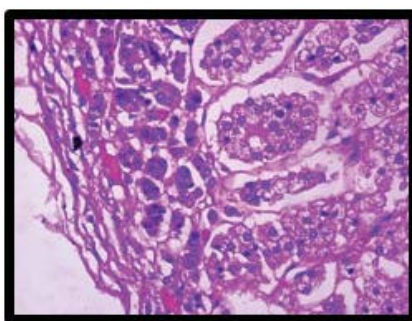
**Fig. 1,2:** Adrenal cortex section of a 29 year/Male-H&E & IHC pictures showing ZG, ZF, ZR. IHC Staining for Cytochrome B5 corresponds well to the histologically recognisable ZR. Note the clearly distinguishable and smooth borders with the adjacent ZF. Also note the thin capsule.



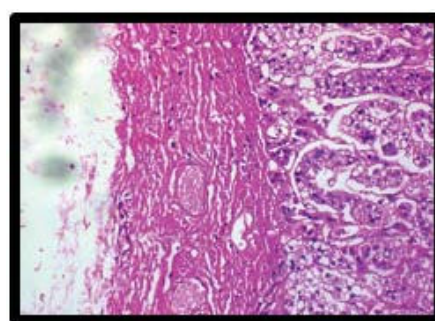
**Fig. 3,4:** Adrenal cortex section of a 60 year/Male-H&E & IHC pictures showing ZG, ZF, ZR & medulla. IHC staining for Cytochrome B5 corresponds well to the histologically recognisable ZR. Note the blurring of the border between ZR (CytB5-containing cells) and ZF (negative for CytB5)

In the adrenal of the young adults there is uniformity in the border of the cortical zone immunopositive for CytB5.

In contrast, in the adrenal from the older adult, CytB5 expression was diffuse, and there was evidence for significantly irregular zonal borders.



**Fig. 5:** 22/F-Thin capsule.



**Fig. 6:** 65/M-Thick capsule.

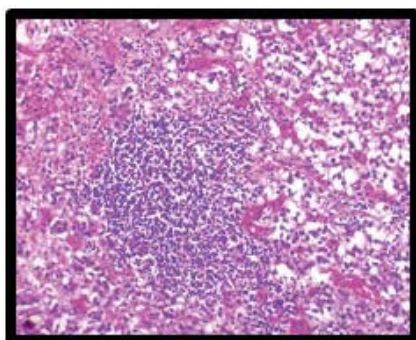


Fig. 7: 72/M-Lymphocytic infiltrates.

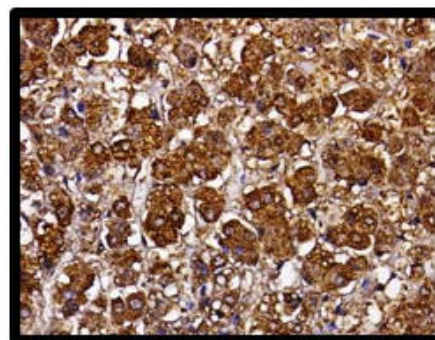


Fig. 8: IHC for CytB5 showing cytoplasmic positivity

## Discussion

This study deals with evaluating the various histo-morphological changes in the cortex of human adrenal glands obtained at autopsy after sudden death, which were obtained and fixed within 24 hours postmortem & to determine whether there are changes in the distribution and/or expression of cytochrome B5 (CytB5), an accessory protein important in the regulation of 17, 20-lyase activity, in the adrenals of aging humans, using qualitative and quantitative analysis with respect to age.

Quinan & Berger (1933)<sup>11</sup> examined right & left adrenal glands in fifty selected coroner cases & found that the mean weight of the right gland was 4.161 gms & that of the left 4.165 gms.

The average weight of of right & Left adrenal glands in different age groups obtained in the present study are given in (Table 1). In our present study, the difference between the right & left adrenal glands with respect to size, weight were not statistically different.

In our present study, it was noted that as age increases, there was a significant reduction in the size & weight of the adrenal glands, which was similar to the results obtained by Quinan & Berger.<sup>11</sup>

Reductions in adrenal androgen production during aging are clinically relevant because of age-associated changes in many physiological systems that are regulated to varying degrees by androgens.

Adrenal androgens may affect the immune system and cognitive ability.<sup>6</sup> Also, there may be a role of DHEAS/DHEA in age-related physiological and patho-physiological declines in bone mass density<sup>12</sup> and libido.<sup>7</sup>

Similar to the study done by Parker *et al.*<sup>13</sup> & Dharia *et al.*,<sup>14</sup> on adrenals from men, the results of our study also confirmed the relative reductions in

the percentage of adrenal cortex that consisted of the zona reticularis during aging.

Zona reticularis cells of human and nonhuman primates have high levels of CytB5 and DHEA sulfotransferase (DST).<sup>15-17</sup> Previously, Parker *et al.* found a decrease in the distribution of cells immunoreactive for DST with aging & Dharia *et al.* found a decrease in the cells immunoreactive for Cytochrome b5 with aging.

Consistent with conclusions reached previously by Dharia *et al.*, our findings in the current study confirms the decrease in the relative width of the cortex immunopositive for CytB5 as age advances.

These findings are suggestive of a decline in the mass of the zona reticularis in aging, which would impair DHEA/DHEAS synthesis relative to young adults.

Another finding in our study is that, In H&E-stained sections of adrenals from young adults, the ZR consisted of cells that were prominently eosinophilic and was usually found to have clearly distinguishable and smooth borders with the medulla and the adjacent ZF.

However, in adrenals from older subjects, cells that were immunopositive for CytB5 and that appeared to represent ZR cells on H&E-stained sections occasionally were found in scattered clusters rather than as continuous zone or band of cells. There was evidence for blurring of the border between the zona reticularis (CytB5-containing cells) and the zona fasciculata (which we find to be negative for CytB5) in aging. Our findings of irregularities in histological zonation of the adrenal in aging are consistent with the results of previous studies done by Parker *et al.*<sup>13</sup> & Dharia *et al.*<sup>14</sup>

One potential limitation of our study is attributable to the type of tissue we obtained for analysis. We used autopsy specimens from subjects who died of sudden trauma that were collected

and fixed within 2–24 h postmortem. Although not expected, there could be cellular changes in adrenal histology or enzyme levels that occur at or after death that are not reflective of the *in vivo* situation.

Although this is possible, we are reassured by the work of Didenko *et al.*<sup>18</sup> that suggests that the pattern of markers of DNA damage (*p21*, *p53*, and DNA fragmentation) found in postoperative or postmortem tissues is the result of the underlying pathophysiological process and do not appear to be the result of artifactual changes.

Additionally, our data on the localization of CytB5 in autopsy cases from trauma victims is consistent with the localization of CytB5 in the zona reticularis noted by Yanase *et al.*<sup>79</sup> in surgical adrenal specimens obtained at time of nephrectomy.

This supports the view that there are no functional immunohistochemical differences in adrenal tissues obtained within the first 24 h after death compared with those from surgical extirpation.

In this study, consistent with the study done by Dharia *et al.*<sup>10</sup> & Parker *et al.*,<sup>72</sup> we detected an age-dependent reduction in the percentage of the adrenal gland immunoreactive for CytB5 that parallels a reduction in the width of the zona reticularis.

We believe that the reduction in the apparent mass of the zona reticularis and the accompanying reduction in the distribution of this important factor in androgen synthesis play a role in the reduced adrenal secretion of DHEA and DHEAS in aging, which is consistent with the study done by Parker LN *et al.*,<sup>5</sup> Labrie *et al.*,<sup>20</sup> Laughlin *et al.*,<sup>21</sup> Parker CR<sup>22</sup>, Meldrum *et al.*,<sup>23</sup> Vermeulen *et al.*<sup>24</sup>

However involution of the zona reticularis may not be the only factor responsible for the reduction in adrenal capacity.

Nevertheless, we propose that these changes are likely to contribute to the etiology of diminished adrenal production of DHEA and DHEAS during aging.

Additional investigation into the mechanism for selective loss in aging of cells having the histological and enzymatic properties characteristic of zona reticularis cells is warranted.

## Conclusion

Autopsy specimens of Adrenal gland (both right & left) were collected from 63 cases, who died of sudden trauma & were evaluated in 3 age groups

(20–40 years, 40–60 years, 60–80 years), with respect to Weight, Size, H&E findings, ZR/TC%, IHC-CYTB5/TC%.

The findings of our study are as follows:

1. In the age wise distribution of cases, maximum number of patients were in the age group of 20 to 40 years, constituting 53.97% of cases.
2. The mean weight of Right & Left adrenal Glands were **4.10 grams** & **4.26 grams** respectively.
3. The mean size of the Right Adrenal Gland is **4.39 × 2.78 × 1.01 cms** & the mean size of the Left Adrenal gland is **4.51 × 2.79 × 1.04 cms**.
4. The mean of weight, length & breadth of both Right & Left adrenal glands were found to decrease with increasing age, which is statistically significant.
5. There is no significant decrease in the thickness of both the Right & Left Adrenal glands, as age increases.
6. There is no significant difference between the right & left Adrenal glands with respect to weight & size.
7. The mean thickness of Zona Reticularis as a percentage of the Total cortex (ZR/TC%) is **30.39%**.
8. The mean thickness of Cytochrome b5 positive area as a percentage of the Total cortex (CYTB5/TC%) is **30.37%**.
9. The mean of ZR/TC% & CYTB5/TC% of the adrenal gland cortex were found to decrease with increasing age, which is statistically significant.
10. The area which was histologically identified as Zona Reticularis on H & E staining, corresponded well to the area of Cytochrome B5 positivity on IHC.
11. There is no statistically significant difference between the mean of ZR/TC% & CYTB5/TC%
12. Lymphocytic infiltration & a thicker capsule are more common in the elderly age group.
13. In the adrenal of the young adult there is uniformity in the border of the cortical zone immunopositive for CytB5.
14. In contrast, in the adrenal from the older adult, CytB5 expression was diffuse, and there was evidence for significantly irregular zonal borders.

## References

1. Sasano H. New approaches in human adrenocortical pathology. Assessment of adrenocortical function in surgical specimen of human adrenal glands. *Endocr Pathol.* 1992; 3:4-13.
2. Young WF. The incidentally discovered adrenal mass. *N Engl J Med.* 2007;356:601-10.
3. Hayashi Y, Hiyoshi T, Takemura T, *et al.* Focal lymphocytic infiltration in the adrenal cortex of the elderly: immunohistological analysis of infiltrating lymphocytes. *Clin Exp Immunol.* 1998;77:101-05.
4. Sasano H, Saito Y, Sato I, *et al.* Nucleolar organizer regions in human adrenocortical disorders. *Mod Pathol.* 1990;3:591-95.
5. Parker LN, Odell WD. Decline of adrenal androgen production as measured by radioimmunoassay of urinary unconjugated dehydroepiandrosterone. *J Clin Endocrinol Metab.* 1978;47:600-602.
6. Flood JF, Roberts E. Dehydroepiandrosterone sulfate improves memory in aging mice. *Brain Res.* 1988;448:178-81.
7. Bachmann GA. The hypoandrogenic woman: pathophysiologic overview. *Fertil Steril.* 2002; 77:S72-S76.
8. Parker LN, Levin ER, Lifrak ET. Evidence for adrenocortical adaptation to severe illness. *J Clin Endocrinol Metab.* 1985;60:947-52.
9. Fan YS, Sasi R, Lee C, Winter JSD, Waterman MR, Lin CC. Localization of the human CYP17 gene (P45017\_ to 10q24.3) by fluorescence in situ hybridization and simultaneous chromosome banding. *Genomics.* 1992;14:1110-11.
10. Lin D, Black SM, Nagahama Y, Miller WL. Steroid 17-hydroxylase and 17,20-lyase activities of P450c17: contributions of serine106 and P450 reductase. *Endocrinology.* 1993; 132:2498-2506.
11. Quinan C, Berger AA. Observations on human adrenals with especial reference to the relative weight of the normal medulla. *Ann Intern Med* 1933;6:1180-1192.
12. Notelovitz M. Androgen effects on bone and muscle. *Fertil Steril.* 2002;77:S34-S41.
13. Parker Jr CR, Mixon RL, Brissie RM, Grizzle WE. Aging alters zonation in the adrenal cortex of men. *J Clin Endocrinol Metab.* 1997;82:3898-3901.
14. Dharia *et al.* Effects of aging on cytochrome b5 expression in the human adrenal gland. *The Journal of Clinical Endocrinology & Metabolism.* 2005;90(7):4357-61.
15. Parker LN, Lifrak ET, Mamadan MB, LaiMK. Aging and the human zona reticularis. *Arch Androl.* 1983;10:17-20.
16. Kennerson AR, McDonald DA, Adams JB. Dehydroepiandrosterone sulfotransferase localization in human adrenal glands: a light and electron microscopic study. *J Clin Endocrinol Metab.* 1983;56:786-90.
17. Parker Jr CR, Jian M, Conley AJ. The localization of DHEA sulfotransferase in steroidogenic and steroid metabolizing tissues of the adult rhesus macaque monkey. *Endocr Res.* 2000;517-22.
18. Didenko VV, Wang X, Yang L, Hornsby P. Expression of p21WAF1/ CIP1/SDI1 and p53 in apoptotic cells in the adrenal cortex and induction by ischemia/reperfusion injury. *J Clin Invest.* 1996;97:1723-1731.
19. Yanase T, Sasano H, Yubisui T, *et al.* Immunohistochemical study of cytochrome b5 in human adrenal gland and in adrenocortical adenomas from patients with Cushing's syndrome. *Endocr J.* 1998;45:89-95.
20. Labrie F, Belanger A, Cusan L, *et al.* Marked decline in serum concentrations of adrenal C19 sex steroid precursors and conjugated androgen metabolites during aging. *J Clin Endocrinol Metab.* 1997;82:2396-2402.
21. Laughlin GA, Barrett-Connor E. Sexual dimorphism in the influence of advanced aging on adrenal hormone levels: the Rancho Bernardo Study. *J Clin Endocrinol Metab.* 2000; 85:3561-68.
22. Meldrum DR, Davidson BJ, Tataryn IV, Judd HL. Changes in circulating steroids with aging in postmenopausal women. *Obstet Gynecol.* 1981;57:624-628.
23. Parker CR. Dehydroepiandrosterone and dehydroepiandrosterone sulphate production in the human adrenal during development and aging. *Steroids.* 1999;64:640-647.
24. Vermeulen A, Deslypere JP, Schelfhout W, Verdonck L, Rubens R. Adrenocortical function in old age: response to acute adrenocorticotropin stimulation. *J Clin Endocrinol Metab.* 1987; 54:187-91.