

A Case Report of a Left long leaf of a Bifid Xiphisternum Misdiagnosed Intraoperatively as a Xeno-osteum and Iatrogenically Excised

Hamad Alajmi¹, Samy Magdy², Saleh Alhasan³

How to cite this article:

Hamad Alajmi, Samy Magdy, Saleh Alhasan/A Case Report of a Left long leaf of a Bifid Xiphisternum Misdiagnosed Intraoperatively as a Xeno-osteum and Iatrogenically Excised./Indian J Anat. 2023;12(1):37-40.

Abstract

Anatomical variations and aberrations represent an ever-present challenge to clinicians in general and surgeons in particular. This is particularly true if the variation is rare and the clinical context doesn't permit thorough investigation, such as would happen intraoperatively. The unfamiliarity with abnormal anatomy and contextual time constraints may preclude their timely recognition, which may result, subsequently in significant morbidity. The shifting paradigms in anatomy education in both under graduate and residency medical programs may be linked to an increasingly cited "abnormal anatomy" as a cause for morbidity and mortality in litigious literature. Therefore, Continuous, and self-directed learning, in the face of a diminished formal anatomy curricula, is essential to achieving this end. In this case report we describe an incident of iatrogenic excision of a leaf of a bifid xiphisternum mistaken for a migrated ingested bone and the clinical lessons imparted from it. We also provide a relevant literature review.

Keywords: anatomical variation; bifid; xiphisternum.

INTRODUCTION

The xiphoid process is the lowest part of the sternal complex, which lies at the junction between the chest and the abdomen. Several medical

and surgical specialties perform procedures on it or in its proximity and is included in imaging of both the chest and the abdomen. Like many midline anatomical structures, the sternum is prone to abnormalities of fusion, which can cause fissures, foraminae and clefts, that may occur in isolation or together with other midline anomalies.^{1,2}

The xiphoid process is the most variable part of the sternum. A multitude of anatomical variations, anomalies and aberrations are known to occur in the dagger-shaped bone, which include perforations, angulations, bifurcation and even trifurcation.^{2,3,4} A bifid xiphisternum is the most common anatomical variation, with a reported prevalence of up to 41% in some cadaveric series.⁴ Despite its prevalence,

Author's Affiliation: ¹Consultant General Surgeon, Ministry of Health, Kuwait, ^{2,3}Faculty of Surgery, Department of General Surgery, Farwanijah Hospital, Sabah Alnasser, Block 6, PO Box 13373 Farwaniya 81004, Kuwait.

Corresponding Author: Saleh Alhasan, Faculty of Surgery, Department of General Surgery, Farwanijah Hospital, Sabah Alnasser, Block 6, PO Box 13373 Farwaniya 81004, Kuwait.

E-mail: drsalhasan@gmail.com

Received on: 10.01.2023

Accepted on: 27.01.2023



This work is licensed under a Creative Commons Attribution-NonCommercial-ShareAlike 4.0.

there is a paucity of reported ante-mortem clinical cases of this anatomical variance.⁵ To our best knowledge there is no reports of xiphoidal variation encountered intraoperatively.

We describe the first case in which the left leaf of a bifid xiphisternum was iatrogenically excised, when it was mistaken for a migrated ingested bone during a laparotomy incision closure. We also provide a root cause analysis of the incident and a relevant literature review.

CASE REPORT

A 45 year-old Syrian male patient was undergoing a reversal of a colonic stoma, which was constructed during an earlier Hartmann's colectomy for a perforated sigmoid cancer. At the time of closing the midline laparotomy incision, the operating surgeon was unable to pass the suture needle through the left limb of the incision's upper angle. He reported a gritty resistance to the needle's tip and felt a hard oblong mass when he palpated the area. The operator decided to explore the lesion by incising the tissues overlying it, which revealed a bony twig of 1cm in diameter and 5 cm in length. The bone had a caudal free rounded end embedded in the left rectus abdominis muscle. The surgeon proceeded to dissect the bone, not knowing its nature, cephalically, where it was found to join the sternum by a fibrous band. The bone was excised (Figure 1)

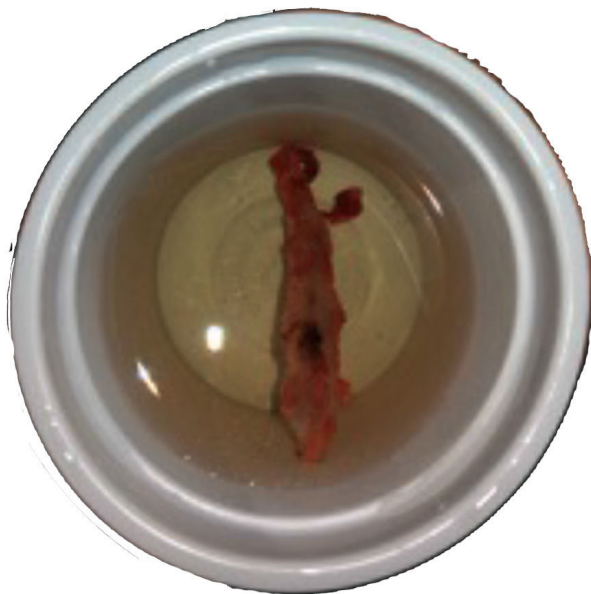

Fig. 1: Shows the excised bony twig of 1 cm in diameter and 5 cm in length

and the senior attending surgeon was summoned, who raised the possibility that the excised bone was

the left leaf of a bifid xiphisternum. The diagnosis was established by reviewing a CT scan of the abdomen which was performed prior to the first surgery (Figure 2).

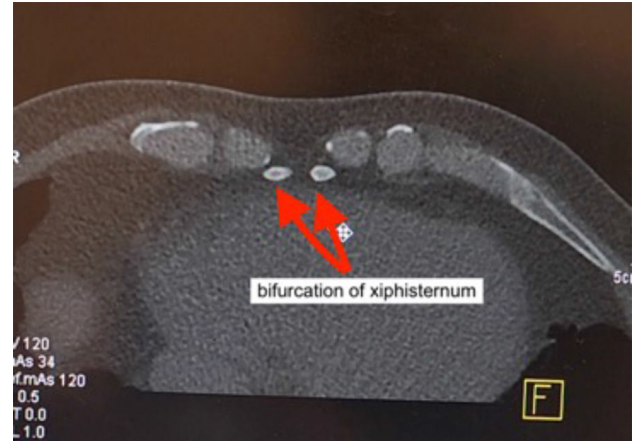


Fig. 2: Pre-operative CT abdomen reveals bifurcation of the xiphisternum confirming the diagnosis of Bifid xiphisternum

A later 3D reconstruction of the bony skeleton (Figure 3) further confirmed the diagnosis.

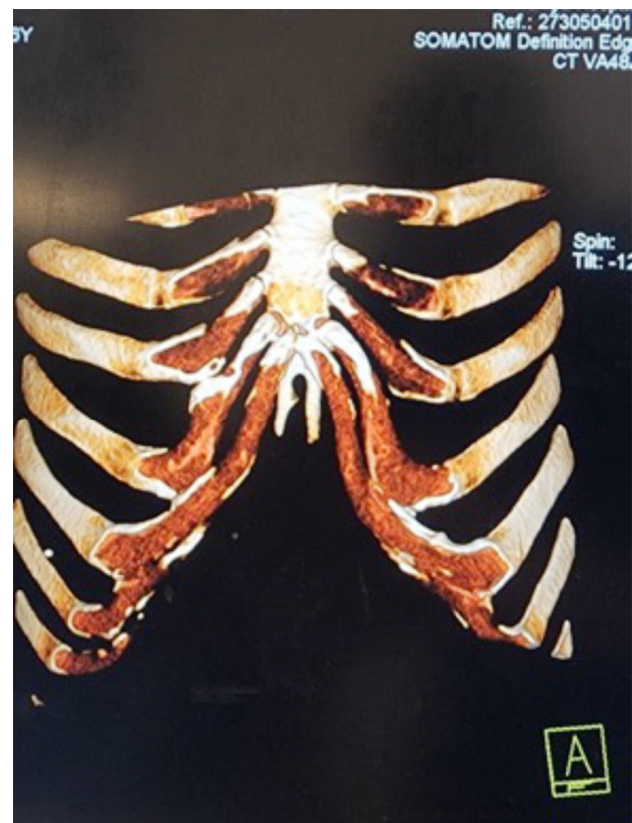

Fig. 3: 3D reconstruction of the bony skeleton confirming the diagnosis of Bifid xiphisternum

Histopathological examination of the extirpated bone was unremarkable. An incident report was submitted to the morbidity committee, and the patient was informed of the intraoperative event,

for which he received counseling. The incident resulted in no litigious actions by the patient, who remained in good terms with the treating surgical team. The patient is symptoms free at one year postoperatively, with no Incisional complications or apparent dysfunction.

DISCUSSION

The xiphoid process is an anterior midline dagger shaped osteo-cartilaginous structure at the junction of the thoracic and abdominal parieties. The process travels down from the xiphisternal junction a variable distance. It has an average length of 5 cm and a range of 3-8 cm.^{3,6}

The xiphoid process has no clear bodily function and may represent an evolutionary vestige.³ It receives muscle fibers on its ventral and dorsal surfaces from the rectus abdominis, Linea alba and the diaphragm.⁷ The xiphisternum is absent in about 2% of the population without apparent morphological or biomechanical consequences.²

Anatomical variations of the sternum are common. In a retrospective study by Vatiza et al such variations were detected in 74.1% of more than a thousand MDCT reconstruction of the chest. More than half of these variations were bifid sternum.² Such findings correlate closely with cadaveric series findings.^{5,8,9}

Despite the central and junctional position of the xiphisternum, and the prevalence it's anatomical variations, there is a dearth of clinical literature on the topic. This may be partially explained by the asymptomatic nature of such variations.

Unlike many less common asymptomatic incidentalomas, which are frequently reported on cross-sectional radiological studies, the abnormalities of the xiphisternum are infrequently reported by radiologists. This may reflect an oversight or the attachment of little clinical value to such findings. In our case the post hoc revision of the CT abdomen revealed the existence of a bifurcated xiphisternum which was overlooked by the radiologists.

Another explanation may be related to the existence of anatomical knowledge gaps and blind spots. Anomalies of the xiphisternum are rarely depicted in anatomical textbooks or included in anatomical curricula.^{7,9} The xiphoid process is depicted in anatomical texts and illustrations as a straight sword- tip plate of bone, while cadaveric and MDCT series find such ideal specimen in less than third of the cases.^{6,10,11} The operating surgical team,

made of residents and an attending, was unaware of the existence of such anatomical variation. The senior surgeon who made the diagnosis had never encountered a similar clinical case before but had seen this variation during cadaveric dissections during his undergraduate anatomy teaching. The changes in anatomy teaching in the past two decades has resulted in abbreviation of the scope and depth of instruction and the replacement of cadaveric dissection by synthetic models, prosection specimens and 3D interactive digital models.^{12,13} Such changes in the educational paradigms have significant implications on surgeons' competence, patient safety and litigation.¹⁴

Anatomical variations can lead to surgical errors and iatrogenic injuries.¹⁵ In surgical malpractice cases, abnormal anatomy is widely cited as a cause of operative difficulties.¹⁵

CONCLUSION

Knowledge of anatomical variations and common nonmetric structural aberrations is essential for the safe conduct of invasive procedures and for the detection and correct interpretation of radiological, intraoperative, and post-mortem findings. Continuous and self-directed learning, in the face of diminished formal anatomy curricula, is essential to achieving this end. The xiphisternum is a highly variable bone and even though such variation rarely rises to clinical significance it is important for clinician whose work encompasses this bone to be aware of such variations.

REFERENCES

1. Altalib AA, Miao KH, Menezes RG. Anatomy, Thorax, Sternum. 2021 Jul 31. In: StatPearls [Internet]. Treasure Island (FL): StatPearls Publishing; 2022 Jan-. PMID: 31082185.
2. Vatzia K, Fanariotis M, Makridis K, Vlychou M, Fezoulidis I. Frequency of sternal variations and anomalies in living individuals evaluated by MDCT. *European Journal of Radiology*. 2021;142:109828.
3. Lachkar S, Iwanaga J, Tubbs R. An elongated dorsally curved xiphoid process. *Anatomy & Cell Biology*. 2019;52(1):102.
4. Kirum G, Munabi I, Kukiriza J, Tumusiime G, Kange M. Anatomical variations of the sternal angle and anomalies of adult human sterna from the Galloway osteological collection at Makerere University Anatomy Department. *Folia Morphologica*. 2017;76(4):689-694.
5. Macaluso P, Lucena J. Morphological variations of the anterior thoracic skeleton and their forensic

- significance: Radiographic findings in a Spanish autopsy sample. *Forensic Science International*. 2014;241:220.e1-220.e7.
6. Akin K, Kosehan D, Topcu A, Koktener A. Anatomic evaluation of the xiphoid process with 64-row multidetector computed tomography. *Skeletal Radiology*. 2010;40(4):447-452.
 7. Standring S, Gray H. *Anatomy. Gray's anatomy*. Edinburgh: Churchill Livingstone; 2015.
 8. Mashriqi F, D'Antoni A, Tubbs R. Xiphoid Process Variations: A Review with an Extremely Unusual Case Report. *Cureus*. 2017;.
 9. Turkay R, Inci E, Ors S, Nalbant M, Gurses I. Frequency of sternal variations in living individuals. *Surgical and Radiologic Anatomy*. 2017;39(11):1273-1278.
 10. Yekeler E, Tunaci M, Tunaci A, Dursun M, Acunas G. Frequency of Sternal Variations and Anomalies Evaluated by MDCT. *American Journal of Roentgenology*. 2006;186(4):956-960.
 11. Xie Y, Wang B, Yun J, Chung G, Ma Z. Morphology of the human xiphoid process: dissection and radiography of cadavers and MDCT of patients. *Surgical and Radiologic Anatomy*. 2013;36(3):209-217.
 12. Romero-Reverón R. Venezuelan surgeons view concerning teaching human anatomical dissection. *Anatomy & Cell Biology*. 2017;50(1):12.
 13. Sheikh A, Barry D, Gutierrez H, Cryan J, O'Keeffe G. Cadaveric anatomy in the future of medical education: What is the surgeons view?. *Anatomical Sciences Education*. 2015;9(2):203-208.
 14. Turney B. *Anatomy in a Modern Medical Curriculum. The Annals of The Royal College of Surgeons of England*. 2007;89(2):104-107.
 15. Kirum G, Munabi I, Kukiriza J, Tumusiime G, Kange M. Anatomical variations of the sternal angle and anomalies of adult human sterna from the Galloway osteological collection at Makerere University Anatomy Department. *Folia Morphologica*. 2017;76(4):689-694

