

Comparative Study of Conventional Smears, Cytospin Smears and Cell Block on Body Fluid Cytology

Teena D Murthy¹, R M Potekar², Amrutha M R³

Author's Affiliation: ¹3rd Year Post Graduate, ²Professor, Department of Pathology, Shri B M Patil Medical College, Hospital and Research Centre, Vijayapura, Karnataka 586103, India.

Corresponding Author: Teena D Murthy, 3rd Year Post Graduate, Department of Pathology, Shri B M Patil Medical College, Hospital and Research Centre, Vijayapura, Karnataka 586103, India.

E-mail: teenamurthy19@gmail.com

How to cite this article:

Teena D Murthy, R M Potekar, Amrutha M R. Comparative Study of Conventional Smears, Cytospin Smears and Cell Block on Body Fluid Cytology. Indian J Pathol Res Pract 2020;9(3):275-278.

Abstract

Purpose: There is a need for a reliable and cost-effective technique for processing of body fluids. Understanding of the wide range of reactive changes is essential for distinguishing benign from malignant cellular changes. In this study, a comparison of conventional smear, cytospin smear and cell block technique in analyzing cytology of body fluids is made.

Methods: Fresh body fluid samples received was divided into three parts. The first part was processed by routine centrifugation, second part by cytospin and third part of the fluid was used to prepare cell block by alcohol formalin method. Cytological and histological evaluation of the prepared smears will be done.

Results: Eighty body cavity fluid samples were evaluated. Cytospin smears showed clear background, high cellularity, better nuclear features and even distribution of cells.

Conclusion: The cytospin smears are better when compared to conventional smears and cell block in analyzing body fluids.

Keywords: Cytospin; Conventional smears; Cell block; Body fluid.

Introduction

Excessive accumulation of fluid in a serous cavity more than the normal amount is referred to as an effusion. The relatively non-invasive technique of fluid cytology can be used to identify benign and malignant causes of effusion.¹ Cytology of body fluid effusions helps to identify the cause of effusion, detect malignancy, specific diagnosis and prognosis of the disease process.^{1,2}

The technique most widely used in many cytology laboratories of India is the preparation of smears from sediment after centrifugation of the sample. This has resulted in increase in false negative results without definitive diagnosis.²

A common diagnostic problem in conventional

smears is to differentiate reactive mesothelial cells and malignant cells this requires thorough screening for wide range of reactive changes.³

Reporting of fluids with scant cellularity, routine centrifuge is not satisfactory. Cytospin and cell block are useful methods in such cases. The morphology of the cells is better appreciated by cytospin and cell block when compared to centrifuge smears.²

The cell block provides high cellularity, better morphological and architectural patterns when compared with the conventional smears.⁴ Cytospin smears preserves the cellular features and decreases overlapping of cells and aids in precise interpretation.¹

In this study, a comparison was made among various techniques in the analyzing body fluids



which include conventional smears, cytospin smears, and cell block technique.

Materials and Methods

A prospective hospital based study was carried out on patients fulfilling the inclusion criteria, referred to the Department of Pathology in BLDEU'S Shri B.M. Patil Medical College, Hospital and Research Centre, Vijayapura. The study was conducted from 1st December 2014 to 30th June 2016. Fresh body fluid samples received were divided into three parts. First part was processed by routine centrifugation at 3000 rpm for 5 minutes and smear was prepared from the sediment and was stained with hematoxylin and eosin after fixation with 95% ethanol. The second part of the fluid was spun in cytospin [MedSpin4] at 800rpm for 5 minutes i.e. 200 microlitre of fluid was placed in cytospin funnel with the filter paper placed between the slide and the funnel and the slide. The slides thus prepared were stained with hematoxylin and eosin after fixation with 95% ethanol. The third part of the fluid was fixed in 10% formal alcohol and it was centrifuged at 2000 rpm for 5 minutes. The supernatant was poured off and the cell button was obtained which was processed in tissue processor and embedded in paraffin. Sections prepared were stained with hematoxylin and eosin.

The smears obtained were evaluated for features such as background, cellularity, cell morphology and cell distribution and were scored from 0 to 2+ scale.

Results

A total of 80 body cavity fluid samples were studied. Out of which 43 (53.8%) were pleural, 36 (45%) were peritoneal and 1 (1.2%) were CSF

fluids. 57 cases (71.2%) were from male patients and 23 cases (28.8%) were from female patients. 20 cases (25%) were in the age group of 31-40 years and 18 cases were 41-50 years (22.5%). 74 (94.4%) cases were benign and the most common cause was Tuberculosis and Cirrhosis. 3 (5.6%) cases were malignant and were diagnosed to be adenocarcinoma with primary being lung and ovary.

The morphological features by each technique were analyzed, cytospin smears showed high cellularity, less cellular crowding, better cytoplasmic and nuclear preservation as compared to centrifuge smears. Cell block slides showed good architectural pattern, nuclear and cytoplasmic preservations similar to cytospin smears. Statistical analysis was done on the data obtained and the results were compared. (Table 1 and 2)

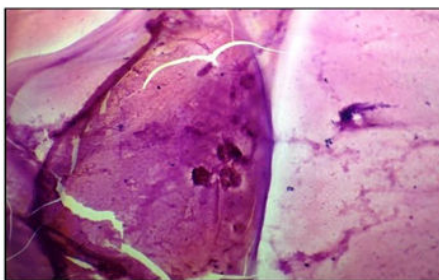
Table 1: Level of Significance difference of means of morphological features of Conventional smear, Cytospin smear and Cell Block.

Morphological features	Conventional and Cell Block and Cytospin (Anova)	Conventional and Cell Block	Cytospin and Cell Block
Background	<0.001*	<0.001*	<0.001*
Cellularity	<0.001*	<0.001*	<0.001*
Morphology	<0.001*	0.004*	<0.001*
Distribution	<0.001*	0.164	<0.001*

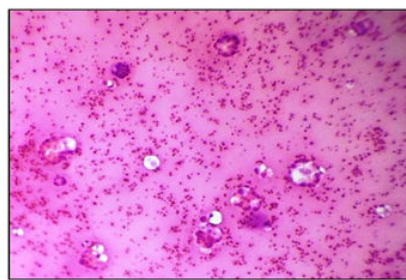
Note: *Difference is statistically significant at 5% level of significance

The difference of means of morphological features of conventional, cytospin and cell block by ANOVA method was found to be statistically significant ($p < 0.001$). The morphology and distribution of cells were statistically insignificant between conventional and cell block ($p > 0.05$).

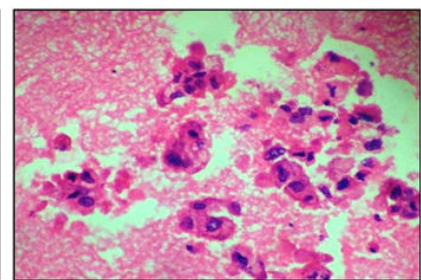
IQV (Index of Qualitative Variation) was found to be minimum for morphology and distribution of cells of cytospin smears (Table 2)



Conventional smear showing tumor cells in clusters and proteinaceous background. H&E X100



Cytospin smear showing tumor cells in clusters, acinar pattern and singly scattered in a proteinaceous background. H&E X100



Cell block showing tumor cells in clusters and proteinaceous background. H&E X400

Fig. 1 Positive For Malignancy-Pleural Fluid Cytology.

Table 2: Index of qualitative variation of morphological features of Conventional, Cytospin and Cell Block methods.

Method	Morphological features	IQV
Conventional	Background	0.818
	Cellularity	0.801
	Morphology	0.808
	Distribution	0.812
Cytospin	Background	0.736
	Cellularity	0.835
	Morphology	0.449
	Distribution	0.583
Cell Block	Background	0.957
	Cellularity	0.808
	Morphology	0.969
	Distribution	0.876

Discussion

Cytology of body fluids is important in clinical practice, as it is a definitive test which avoids unnecessary exploratory surgery.²⁴ Most of the cytology laboratories practice sediment smear preparation for routine evaluation of body fluids. The cell block technique is one of the oldest methods and its advantages have been reported by many authors as it provides valuable diagnostic information.²

In the present study conventional smears, cytospin smears and cellblock preparation from the same specimen were analyzed. Due consideration was given to age, sex, site of effusion and clinical findings to arrive at final diagnosis.

Present studies is in concordance with Singh M et al and Joshi A et al which showed cytospin preparations preserve the cellular details and reduce the overlapping of cells and thus helps in precise interpretation than conventional smears. The cellular morphology, nuclear and cytoplasmic details, were better appreciated on cytospin smears and cell block technique (Fig. 1). Cell block carries additional advantage of performing Immunohistochemistry which aids in the diagnosis and can be used for retrospective analysis.

A study done by Sumi M G et al⁵ on CSF-cytospin smears from Tuberculous meningitis patients showed the technical aspects of this immunocytological method. Demonstration of mycobacterial antigens was simple, specific, rapid and reproducible by this method. Hence can be applied for the early diagnosis of Tuberculous meningitis, particularly in patients in whom presence of M. tuberculosis in the CSF was not demonstrated by bacteriological methods.

A study done by Moreno MJ et al⁶ on 23 synovial fluids for differential counts, concluded that cytospin preparations gave better morphology and also the differential counts on cytospin preparations showed a higher percentage of monocytes, suggesting that these cells were undetected and misinterpreted as lymphocytes on routine smears.

The present study is in concordance with a study done by Singh et al showed in evaluating the cytological details brought out by each technique, cytospin smears were superior to routine centrifuge in demonstrating cellularity, cell retrieval, less cellular crowding, better cytoplasmic and nuclear preservation. Cell block showed good architectural pattern similar findings was seen in other studies.^{7,8,9}

According to various studies if conventional smear technique is supplemented by cytospin and cellblock method additional diagnostic yield for malignancy was noted. The present study also concludes cellblock serves as a useful adjunct to traditional Conventional smears. A major disadvantage of the cellblock is more turnaround time as compared to conventional smears. Lack of cellular material in cellblock maybe observed due to technical errors such as inadequate sampling or degenerated sample.

The present study showed cytospin smears are cost effective, and less amount of sample is sufficient for cytodagnosis. The screening time is less and malignancy can be easily diagnosed because of monolayer of cells, clear background, less cellular degeneration and even distribution of cells. Similar findings were noted by Joshi A et al and Singh M et al. Immunocytochemistry can be done on cytospin smears and thus the need for cell block is not required.

The limitation of this study which was for each case the quantity of fluid received was divided and conventional smears, cytospin and cell block were prepared. The cell blocks showed inadequate material because of insufficient sample in few cases.

Conclusion

Our study concludes that cytospin smears showed clear background, high cellularity, better nuclear feature, even distribution of cells and decreases the screening time thereby better when compared to conventional smears and cell block in analyzing body fluids.

Though cell blocks were complementary to Conventional smears in the overall categorization of benign and malignant groups, they appeared to

be more useful in the diagnosis of malignancy by better preserved architectural patterns, as seen in corresponding histopathology sections.

Cytospin and Cell blocks are an excellent resource material for ancillary techniques like immunocytochemistry/immunohistochemistry and also useful in predicting the primary site of malignancy.

References

1. Singh M, Khan L, Verma YN, Sachan N, Pantola C, Pathak A et al. Comparative study for the use of different techniques in Serous fluid cytology. *JEMDS* 2015;4:3154-61.
2. Joshi A, Mahajan N, Karmarkar PJ, Mahore SD. Diagnostic utility of various techniques used in body fluid cytology. *IOSR-JDMS* 2014;13:13-8.
3. Bhanvadia VM, Santwani PM, Vachhani JH. Analysis of diagnostic value of cytological smear method versus cell block method in body fluid cytology: study of 150 cases. *Ethiop J Health Sci* 2014;24:125-30.
4. Udasimath S, Arakeri SU, Karigowdar MH, Yelikar BR. Diagnostic utility of the cell block method versus the conventional smear study in pleural fluid cytology. *J Cytol* 2012;29:11-15.
5. Sumi MG, Mathai A, Reuben S, Sarada C, Radhakrishnan VV. Immunocytochemical Method for Early Laboratory Diagnosis of Tuberculous Meningitis. *Clin Diagn Lab Immunol* 2002;9:344-7.
6. Moreno MJ, Clayburne G, Schumacher HR. Processing of non inflammatory synovial fluids with hyaluronidase for cytospin preparations improves the accuracy of differential counts. *Diagn Cytopathol* 2000;22:256-58.
7. Thapar M, Mishra RK, Sharma A, Goyal V, Goyal V. Critical analysis of cell block versus smear examination in effusions. *J Cytol* 2009;26:60-64.
8. Shobha SN, Kodandaswamy CR. Utility of modified cell block technique in cases of pleural effusion suspected of malignancy. *International Journal of Health Science and Research* 2013; 3: 33-8.
9. Kulkarni MB, Desai SB, Ajit D, et al. Utility of thromboplastin plasma cell block technique for fine needle aspiration and serous effusions. *Diagnostic Cytopathology* 2008; 37: 86-90.

