

# Role of Topical Feracrylum in Management of Donor Site Raw Area

Vishnu Kumar K. S.<sup>1</sup>, Ravi Kumar Chittoria<sup>2</sup>, Bharath Prakash<sup>3</sup>

## How to cite this article:

Vishnu Kumar K. S., Ravi Kumar Chittoria, Bharath Prakash. Role of Topical Feracrylum in Management of Donor Site Raw Area. *Ind. Jr. Med. & Health Sci.* 2024;11(1):27-30.

## Abstract

Donor site raw area wounds present a difficult and challenging prognosis. Management of donor site raw area wounds inflicted by the different kinds of mechanisms require different regimes which are poles apart from the regimes used for any of the other wounds. In such raw area wounds, there is extensive loss of plasma leading to shock while whole blood loss is the cause of shock in other acute wounds. Even though the wounds are relatively clean after initial debridement, death in extensive donor raw areas is mainly because of wound infection and septicemia. Current techniques of wound care have significantly reduced the incidence of invasive wound infections, altered the organisms causing the infections that do occur, increased the interval between injury and the onset of infection, reduced the mortality associated with infection, decreased the overall incidence of infection in such patients, and increased patient survival.

Feracrylum, a water-soluble combination of partial ferrous salts (II and III) of polyacrylic acid, is one of the chemical hemostatic agents and an antibacterial agent. Its molecular weight ranges from 500,000 to 800,000 Daltons, which prevents systemic absorption and prevents any negative effects on the liver, kidney, adrenals, cardiovascular, or hemostatic systems. Feracrylum has antibacterial properties, which lowers the risk of wound infection.

**Keywords:** Topical; Feracrylum; Management; Donor Site Raw Area.

**Author Affiliation:** <sup>1</sup>Junior Resident, Department of Orthopaedic Surgery, <sup>2</sup>Professor, <sup>3</sup>Senior Resident, Department of Plastic Surgery & Telemedicine, Jawaharlal Institute of Postgraduate Medical Education and Research, Pondicherry 605006, India.

**Corresponding Author:** Ravi Kumar Chittoria, Professor, Department of Plastic Surgery & Telemedicine, Jawaharlal Institute of Postgraduate Medical Education and Research, Pondicherry 605006, India.

**E-mail:** drchittoria@yahoo.com

**Received on:** 06.04.2024

**Accepted on:** 27.06.2024

## INTRODUCTION

A variety of factors guide the evaluation and management of donor site raw area wounds. First is the nutrition status of patient. Next is the severity of infection which may be mild, moderate, or severe leading to direct inoculation of microorganisms deep into the wounds. Next is the depth of the wound described as superficial, subcutaneous, or bone deep which leads to the inoculated microorganisms to be residual for a longer time.<sup>1</sup> Finally, other factors include specific



patient characteristics like the age of the patient (< 10 or > 50 years old); other medical or health problems; if there are specialized locations of the wounds such as the ones near joint articulations that might possibly lead to seeding of a joint cavity with microorganisms in near future leading to septic arthritis which may further lead to permanent functional impairment in future.<sup>4,5</sup>

Donor site raw area wound infections can be classified on the basis of the causative organism, the depth of invasion, and the tissue response<sup>2</sup>. Diagnostic procedures and therapy must be based on an understanding of the pathophysiology of these wounds and the pathogenesis of the various forms of infection.<sup>3</sup> The time related changes in the predominant flora of the contaminated donor raw area wounds from gram-negative and anaerobes to several multidrug-resistant hospital-acquired microorganisms recapitulate the history of such wound infections.

## MATERIALS AND METHODS

As pilot research, the investigation was carried out in a higher education facility in August 2023. The research was entirely descriptive; no statistical analysis was carried out. After gaining informed consent, the patient with the donor site raw area was included. The patient was 57 years old and admitted for raw area overlying a fracture site with bone loss. For which a cross leg flap was raised on opposite leg. But the donor raw area (fig. 1) of flap was not healing. Adjuncts such as skin grafting platelet rich plasma, low level laser therapy were

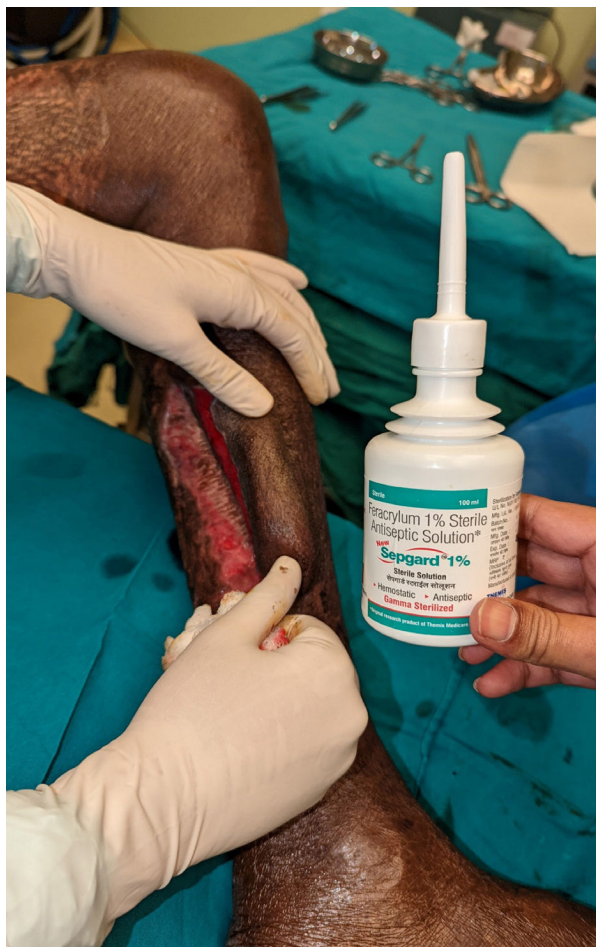

Fig. 2: Application of feracrylum 1% solution

given Feracrylum in solution form was used as an antimicrobial solution (fig. 2). Serial changing of dressings of the wound was done.

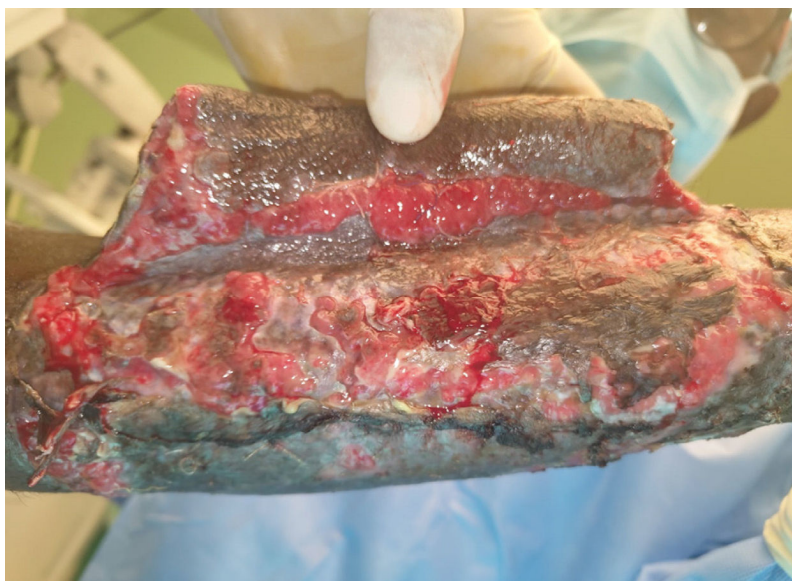


Fig. 1: Donor site raw area after raising crossleg flap

## RESULTS

In this study, we had a patient with donor site raw area wound overlying aon limb from which cross leg flap was raised. The wound at the end of 3 weeks showed a significant reduction in the treated area measured by digital planimetry with a new epithelium development (fig. 3). After treatment, the size of the raw area surface decreased. Due to the application of feracrylum, no additional pain occurred. Minimal soaking of the wound with good hemostasis and eradication of infection was observed.

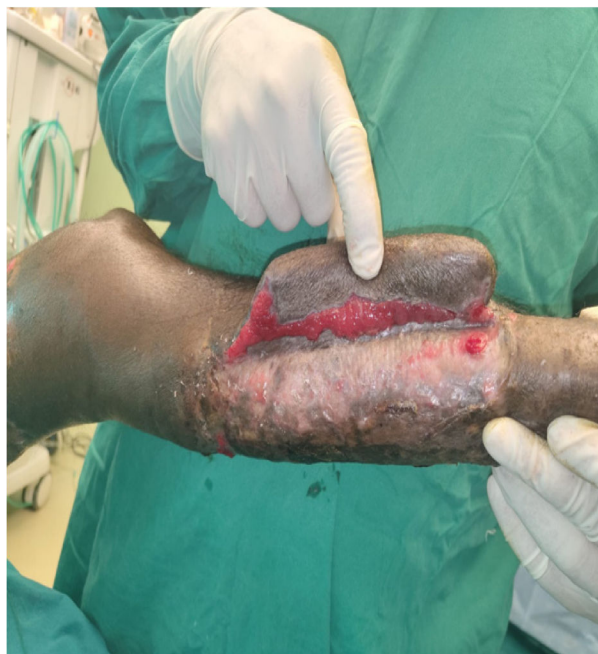

Fig. 3: Healed raw area after 3 weeks of using feracrylum 1%

## DISCUSSION

Feracrylum is a water soluble mixture of incomplete ferrous salt II and III of polyacrylic acid containing 0.05–0.5% of iron. It is biodegradable and hygroscopic.<sup>6</sup> The molecular weight is about 5,00,000–8,00,000 Daltons, due to which there is no systemic absorption. No noted side effects on major organs like liver, kidney, adrenal gland, cardiovascular system and hemopoietic system. It has antimicrobial and wound healing properties.<sup>7</sup>

### *Feracrylum has multiple actions for wound care*

**Antimicrobial action:** Feracrylum is not only haemostatic but also anti-infective against a

number of Gram-positive and Gram-negative pathogenic, bacterial and fungal strains like *Staphylococcus aureus*, *Streptococcus pyogenes*, *Corynebacterium diptheriae*, *Salmonella typhi*, *Shigella dysenteriae*, *Pseudomonas aeruginosa*, *Proteus vulgaris*, *Escherichia coli*, *Trichoderma viridae* and *Candida albicans*.<sup>10</sup>

**It ruptures microbial cell wall causing cell lysis.** Feracrylum is superior to povidone iodine for its antimicrobial properties and its efficacy is comparable to that of povidone iodine.<sup>11</sup>

Feracrylum decreases risk of wound infection which delays wound healing.

**Hygroscopic action:** Feracrylum is hygroscopic in nature and maintains a moist environment at wound site resulting in faster healing and easy dressing removal. It promotes growth of healthy granulation tissue. Feracrylum is available in the form of a solution (1% w/v feracrylum), gel and tubes (1% feracrylum) and tulle (3% feracrylum).

**Haemostatic action:** It causes activation of thrombin (factor IIa) which is a serine protease that converts soluble fibrinogen into insoluble strands of fibrin thus forming clot as well as catalyzing many other coagulation related reactions in blood coagulation.<sup>8</sup>

Also, feracrylum on coming in contact with blood proteins especially albumin, it forms a biodegradable water insoluble synthetic complex creating a large rubbery clot which forms a physical barrier on wound surface and stops capillary bleeding and oozing in 2-3 minutes. It is non allergic with no systemic absorption.<sup>9</sup>

## CONCLUSION

The present study, results may conclude that better size reduction of raw area (high percentage of epithelized area) and lesser incidence of wound infection when Feracrylum was used. Topical feracrylum can be used to manage raw area wounds with satisfactory results. The time taken by the patients to recover from pain, resume their normal activity and also with regard to normal food intake was rapid. It is a good topical agent for prevention of infection of the Post donor site s raw area wounds. Further studies are recommended with large sample size to confirm these findings.

**REFERENCES**

1. Eyvaz K, Kement M, Balin S, Acar H, Kündeş F, Karaoz A, Civil O, Eser M, Kaptanoglu L, Vural S, Bildik N. Clinical evaluation of negative-pressure wound therapy in the management of electrical burns. *UlusTravmaAcilCerrahiDerg.* 2018 Sep;24(5):456-461.
2. Moenadjat Y, Setiabudy R, Astrawinata AWD, Gumay S. The Safety and Efficacy of Feracrylum as Compared to Silver Sulfadiazine in the Management of Deep Partial.
3. Thickness Burn: A Clinical Study Report. *Med J Indones*, 2008; 17: 259-71.
4. Bhagwat AM, Save S, Burlu S, Karki SG. A Study to Evaluate the Antimicrobial Activity of Feracrylum and its Comparison with Povidone Iodine. *Indian J Pathol Microbial*, 2001; 44: 431-433.
5. Lahoti KB, Aggarwal G, Diwaker A, Sharma SS, Laddha A. Hemostasis during Hypospadias Surgery via Topical Application of FeracrylumCitrate: A Randomized Prospective Study. *J Indian Assoc Pediatr Surg*, 2010; 15: 87-89.
6. Chauhan MK, Feracrylum KM. An Effective and safe Topical Haemostatic agent. *World J Pharm Res.* 2017;6(10):319-325. doi: 10.20959/wjpr201710-9372.
7. Laddha AK, Mulla M, Sharma SS, Lahoti BK, Mathur R. A prospective comparison of topical feracrylum citrate versus adrenaline as haemostatic agent in hypospadias surgery in children. *Afr J Paediatr Surg.* 2014;11(3):215. doi: 10.4103/0189-6725.143191.
8. Sathyaki DC, Roy MS, Mohan M, Raghu N, Sheriff RM. Feracrylum versus topical adrenaline for hemostasis in tonsillectomy. *Int J Sci Stud.* 2017;4(10):34-36. doi: 8.17354/ijss/2017/07.
9. Prabhu NT, Munshi AK. Clinical, radiographic and histological observations of the redicular pulp following "feracrylum" pulpotomy. *J Clin Pediatr Dent.* 1997; 21:151-6.