

Original Research Article

Clinicopathological Study of Soft Tissue Tumors: A 2 Year Study in Tertiary Care Hospital

Shailendra B Yadav¹, Goldy M Patle²¹Associate Professor, ²Assistant Professor, Department of Pathology, Government Medical College, Gondia, Maharashtra 441601, India.

Corresponding Author:

Goldy M Patle, Assistant Professor,
Department of Pathology, Government
Medical College, Gondia, Maharashtra 441601,
India.E-mail: goldypatle27@gmail.com

Received on 26.02.2020

Accepted on 20.03.2020

Abstract

Introduction: Soft tissue is a non-epithelial extra skeletal tissue of the body wherein reticuloendothelial system, glia and supporting tissue of parenchymal organs are excluded. It is constituted by voluntary muscles, fat, fibrous tissue and supplying blood vessels. **Aim of the study:** To analyse the histopathological findings in various soft tissue tumors and to study its distribution in relation to age, sex and site. **Materials and Methods:** This is a retrospective observational study carried out in the pathology department at tertiary care academic institute for a period of two years. The specimen was grossed, processed, sectioned, stained with haematoxylin and eosin. It includes 106 cases of soft tissue tumors that were diagnosed at our institute on both clinical and pathological basis. **Results:** Out of 106 cases, 102 cases (96.22%) were benign and three cases (2.83%) were malignant in nature and only one case (0.94%) was of intermediate grade. The commonest age group was 41-50 years and M:F ratio was 2.52:1. Among benign tumours, adipocytic tumours constituted majority of the cases (75.47%), followed by vascular tumours (12.26%). Extremities was the commonest site for soft tissue tumour followed by back region. **Conclusion:** The most common age group is 41-50 years and the incidence is higher in males than females. Most common symptom was painless mass. The benign soft tissue tumors outnumbered malignant tumors. Lipomas were the most common benign tumours.

Keywords: Soft tissue tumors, lipomas, adipocytic tumors.

How to cite this article:

Shailendra B. Yadav, Goldy M. Patle. Clinicopathological Study of Soft Tissue Tumors: A 2 Year Study in Tertiary Care Hospital. Indian J Pathol Res Pract. 2020;9(1 Part II):248-254.

Introduction:

Soft tissue is the complex of non epithelial extraskeletal structures of the body exclusive of the supportive tissue of the various organs and the haematopoietic or lymphoid tissue. It is composed of fibrous tissue, adipose tissue, skeletal muscle,

blood and lymph vessels, and peripheral nervous system.¹

Soft tissue tumors are defined as mesenchymal proliferation of extraskeletal non-epithelial tissues of the body. It excludes viscera, coverings of brain and lymphoreticular system.² The annual incidence of soft tissue tumor is 1.4 per 100000 population.³



This work is licensed under a Creative Commons Attribution-NonCommercial-ShareAlike 4.0.

Soft tissue tumors are the fourth most common malignancy in children, after haematopoietic neoplasm, neural tumor and Wilm's tumor.²

Among childhood cancers, soft tissue sarcomas account for 15%.² Benign tumors outnumber malignant ones in ratio of 100:1.⁴ The most important prognostic factor for all soft tissue sarcomas is histologic grade which is associated with the advent of metastasis and patients survival.^{5,6} The diagnosis of soft tissue tumor is strenuous because of their extremely varied morphology and biological behaviour.⁷

The use of ancillary techniques like immunohistochemistry, electron microscopy, flow cytometry and cytogenetics has increased insight into the tumor biology and has provided tools for greater diagnostic accuracy. But the root of these techniques rests upon the histologic diagnosis and use of special stains. It is critical to recognize immunohistochemistry as an adjunctive technique, which does not supercede or replace the traditional morphological diagnosis.^{8,9}

Soft tissue tumors are a highly heterogeneous group of tumors that are classified on a histogenetic basis according to the adult tissue they resemble. Soft tissue tumors are divided into benign, intermediate and malignant forms.¹⁰

Benign tumours are usually superficial, well-defined, encapsulated masses and grow slowly.¹¹ Soft tissue tumour with rapid increase in size, size >5 cm, present deep inside the fascia or painful represents malignant transformation. Biopsy is an essential preoperative investigations and should be done in every case, especially when malignancy is suspected. This would help in deciding whether surgical excision is adequate, or a multimodal therapeutic approach is warranted.¹³ Most patients with suspected soft tissue neoplasms present with painless mass and one-third of cases presents with pain.⁽¹⁴⁾

Aims and Objectives

1. To study the occurrence of soft tissue tumors in relation to age, sex and anatomical site.
2. To study histopathological features of soft tissue tumors.
3. To study frequency of occurrence of benign and malignant soft tissue tumors.
4. To analyse the various types and subtypes of soft tissue tumours.

Materials and Methods

This was a retrospective observational study conducted in the pathology department at a newly established tertiary health care academic institute from January 2017 to December 2018. Total 106 cases of soft tissue tumors were analysed in the study period. Relevant clinical data including patient's history, clinical examination findings, ultrasonography and other radiological findings were obtained. Gross examination findings of specimens are noted. Formalin fixed paraffin embedded sections were stained with hematoxylin and Eosin and the histopathological diagnosis was given. The cases were further divided into following categories 1) Lipomatous tumors' 2) Vascular Tumors' 3) Myofibroblastic Tumors 4) Fibrohistiocytic tumors 5) Peripheral nerve sheath tumors 6) Chondro-osseous tumors 7) Skeletal muscle tumors 8) Tumors of uncertain malignant potential. In each case, tumours were classified in relation to age, sex, site of distribution of tumors and microscopic features.

Inclusion Criteria

All the cases of soft tissue neoplasms which were diagnosed on both clinical as well as pathological basis.

Exclusion Criteria:

Cases of tumours like lesions of soft tissue (ex. Hamartomas) and tumours arising from supporting tissue of various parenchymal organs such as uterine and gastrointestinal parenchyma (e.g. leiomyoma of uterine myometrium.)

Results

A total number of 106 cases were enrolled in a period of two years. In our study, the commonest age group was 41-50 years with male prepondence in the ratio of 2.52:1 (M:F ratio). The most common presenting symptom was painless mass and the commonest site affected was extremities (35.84%) followed by back region (34.90%). Out of 106 cases, 102 cases (97.84%) were benign and three cases (2.85%) were malignant and one case (0.94%) was of intermediate grade. Among benign tumours, adipocytic tumours constituted majority of the cases (75.47%), followed by vascular tumours (12.26%).

The broad categories of tumours are mentioned in (Table 1) according to WHO classification.

As mentioned in (Table 1), intermediate and malignant categories are uncommon compared to

benign counterparts. Among benign, Adipocytic tumours are quite commonly seen followed by vascular tumours.

Table 1: Broad Categories of Soft tissue tumours

Histopathological Group	Benign	Intermediate	Malignant
Adipocytic Tumors	79	00	01
Vascular Tumors	12	01	00
Myofibroblastic Tumors	03	00	00
Fibrohistiocytic tumors	00	00	00
Peripheral nerve sheath tumour	08	00	01
Chondro-osseous tumor	00	00	00
Skeletal muscle tumor	00	00	0
Tumors of uncertain malignant potential	0	00	01
Total	102	01	03

Morphological spectrum of soft tissue tumours is mentioned in (Table 2):

Among adipocytic tumour (75.47%), there are 71 cases (66.98%) of lipoma, 6 cases of fibrolipoma.

Vascular tumours are second commonest tumour (12.26%) and peripheral nerve sheath tumour is the 3rd commonest consisting of (8.49%) of cases.

Table 2: Morphological spectrum of soft tissue tumours

Histopathological Groups	No. of Cases
Adipocytic Tumors (80 cases) 75.47%	
Lipoma	71
Fibrolipoma	06
Myxolipoma	01
Angiolipoma	01
Pleomorphic Liposarcoma	01
Vascular Tumors (13 cases) 12.26%	
Hemangioma	10
Angiomyoma	02
Hemangioendothelioma	01
Myofibroblastic Tumors (02 cases) 1.8%	
Nodular Fascitis	01
Angiofibroma	01
Smooth Muscle tumors (01 cases) 0.9%	
Leiomyoma	01
Peripheral Nerve Sheath Tumors (09 cases) 8.49%	
Neurofibroma	02
Schwannoma	06
Malignant PNST	01
Tumor of uncertain differentiation (01 cases) 0.9%	
Synovial sarcoma	01
Total	106

Age wise and location wise distribution of tumours are mentioned in (Table 3 and Table 4).

As mentioned in Table 3, adipocytic tumours

can be found in all age groups, while other soft tissue tumours are more or less age specific in their occurrence.

Table 3: Age Wise distribution of tumours

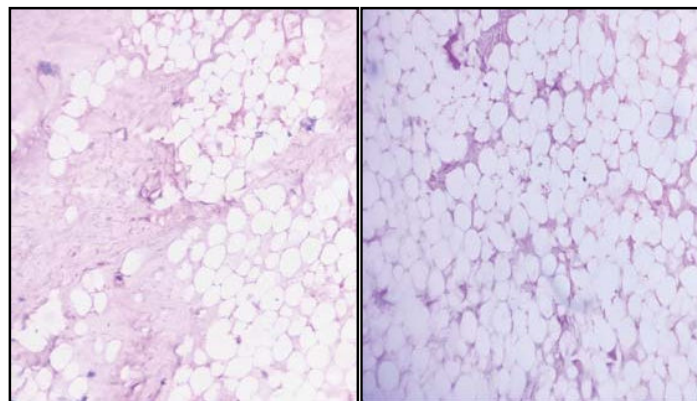
Histopathological Group	Different Age Groups in Years						Total
	20 or less	21-30	31-40	41-50	51-60	>60	
Adipocytic Tumors	07	14	14	23	16	06	80
Vascular tumor	03	00	05	01	02	02	13
Myofibroblastic tumor	00	01	01	00	00	00	02
leiomyoma	00	00	01	00	00	00	01
Peripheral nerve sheath tumor	03	01	02	02	01	00	09
Tumor of uncertain differentiation	00	00	00	01	00	00	01
Total	13	16	23	27	19	08	106

Table 4: Location wise distribution of soft tissue tumour

Histopathological group	Different locations or site of tumours						Total
	Head Neck & face	Thorax	Abdominal Wall & Flanks	Back	Upper limbs & Axilla	Lower Limbs and Groins	
Adipocytic Tumours	07	05	09	35	18	06	80
Vascular tumour	06	00	00	01	03	03	13
Myofibroblastic tumour	00	00	00	00	00	02	02
leiomyoma	00	00	00	00	01	00	01
Peripheral nerve sheath tumour	03	01		01	01	03	09
Tumour of uncertain differentiation	00	00	00	00	00	01	01
Total	16	06	09	37	23	15	106

As mentioned in Table 4, back and upper extremities are commonly involved locations while other sites are rare. Adipocytic tumours are commonly seen on back and upper limb while vascular tumours are frequently seen over head and neck region. Nerve sheath tumours are frequently seen over upper extremities and head and neck region.

In our study, only three cases were malignant tumours. Out of them, one case was 60 year old female presented with progressive soft tissue mass over abdomen. Histopathologically it was diagnosed as pleomorphic liposarcoma. Rest of the two cases were diagnosed as synovial sarcoma and malignant peripheral nerve sheath in a 15 years old male and in 40 years old female respectively.

**Fig. 1:** Fibrolipoma.**Fig. 2:** Conventional lipoma.

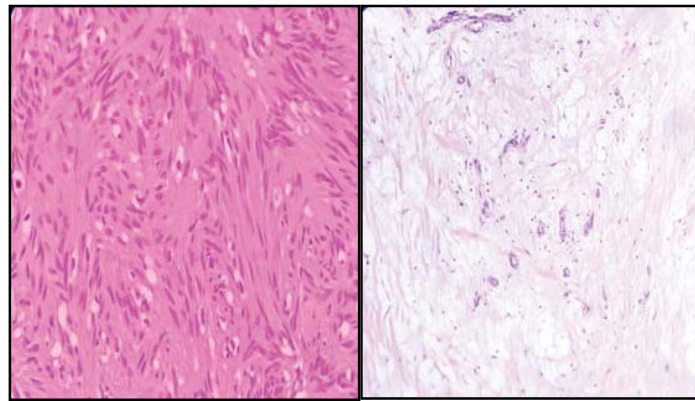


Fig. 3: Schwannoma.

Fig. 4: Angiolipoma.

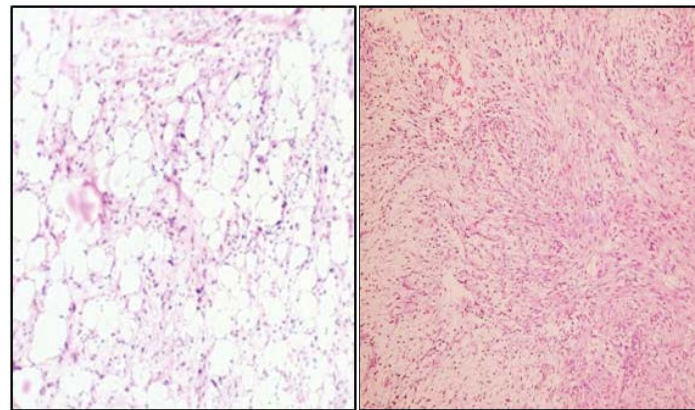


Fig. 5: Liposarcoma.

Fig. 6: Nodular Fasciitis.

Discussion

The present study includes 106 cases of various soft tissues and they are classified into 3 categories

as benign, intermediate and malignant. Benign tumours outnumbered intermediate and malignant ones and comparison of this relative frequencies of various studies is demonstrated in (Table 5).

Table 6: Comparison of present study with other similar studies

Points to be compared	Present study	Naik V et al. ¹⁵	Zope RD et al. ¹⁶	Navya Narayan O et al. ¹⁷	Umarani M.k. et al. ¹⁸
Common age group	41-50	31-40	41-50	31-40	31-40
Gender ratio (M:F)	2.52:1	1.13:1	1.01:1	1.7:1	1.1:1
Common site	Extremities	Extremities	Extremities	Extremities	Extremities
Most common tumour	Adipocytic	Adipocytic	Adipocytic	Adipocytic	Adipocytic
Second most common	vascular	vascular	vascular	vascular	Nerve sheath tumour
Adipocytic tumour incidence (%)	75.47	58.33	59.35	65.20	65.68

Table 6 shows the comparison of present study with other studies. The most common age group in this study was 41-50 years which

is comparable to the study of Zope RD et al.¹⁶ In other studies like Naik V et al.,¹⁵ Navya Narayan O et al.¹⁷ and Umarani M.k. et al.¹⁸ the commonest

age group for soft tissue tumours is 31-40 years. In present study intermediate grade malignancy, hemangioendothelioma occurred at the age of 70 years; synovial sarcoma, malignant peripheral nerve sheath tumour and pleomorphic liposarcoma occur at the age of 15 yr, 40 yr and 60 yr respectively. Soft tissue tumours are seen in both genders with a

male prepondence. In this study, the gender ratio (M:F ratio) is 2.52:1. The studies done by Naik V et al.,¹⁵ Zope RD et al.,¹⁶ Navya Narayan O et al.¹⁷ and by Umarani M.k. et al.,¹⁸ the gender ratios were 1.13:1, 1.01:1, 1.7:1 and 1.1:1 respectively. We can conclude that the soft tissue tumours are more commonly seen among males than females.

Table 6: Comparison of present study with other similar studies

Points to be compared	Present study	Naik V et al. ¹⁵	Zope RD et al. ¹⁶	Navya Narayan O et al. ¹⁷	Umarani M.k. et al. ¹⁸
Common age group	41-50	31-40	41-50	31-40	31-40
Gender ratio (M:F)	2.52:1	1.13:1	1.01:1	1.7:1	1.1:1
Common site	Extremities	Extremities	Extremities	Extremities	Extremities
Most common tumour	Adipocytic	Adipocytic	Adipocytic	Adipocytic	Adipocytic
Second most common	vascular	vascular	vascular	vascular	Nerve sheath tumour
Adipocytic tumour incidence (%)	75.47	58.33	59.35	65.20	65.68

Both upper and lower extremities are the most common location for soft tissue tumours. In our study total 38 cases (35.84% cases) belong to soft tissue tumors over extremities. Next common location was back (34.90% cases). Next common location was head, neck and face, abdominal walls and flanks and thorax in decreasing order. In the studies conducted by Naik V et al.,¹⁵ Zope RD et al.,¹⁶ Navya Narayan O et al.¹⁷ and by Umarani M.k. et al.¹⁸ the commonest site was extremities which is similar to our study.

Among all soft tissue tumours, lipoma and its variants constitute majority of cases (total 80 out of 106, 75.47% cases) followed by cases of vascular tumours (total 13 out of 106 cases 12.26% cases). The incidence of adipocytic tumours in studies done by Naik V et al.,¹⁵ Zope RD et al.,¹⁶ Navya Narayan O et al.¹⁷ and by Umarani M.k. et al.¹⁸ are 58.33%, 59.35%, 65.20% and 65.68% respectively which is comparable with our study. Vascular tumours are the second most common tumour in the present study and results are same in study done by Naik V et al.,¹⁵ Zope RD et al.¹⁶ and Navya Narayan O et al.¹⁷ In a study done by Umarani M.K. et al.,¹⁸ nerve sheath tumours constitute second most common group following adipocytic tumours.

Conclusion

- The salient findings observed in the present study are as follows

- Painless mass is the most common presenting symptom in our study.
- Most common age group is 41-50 years.
- The most common site is extremities followed by back region.
- Benign soft tissue tumors outnumbered malignant tumor.
- In our study male to female ratio is 2.52:1
- The most common soft tissue tumors are lipomatous tumor.

References

- Rosai J. Soft tissues. Chapter-25 In: Rosai and Ackerman's Surgical Pathology, Vol. 2, 9th Edition, Mosby 2004. pp.2237-72.
- Rosenberg AE. Bones, Joints and Soft Tissue Tumors. Chapter-26 In: Robbins and Cotran Pathologic Basis of Disease by Kumar, Abbas and Fausto, 7th Edition, Saunders: Elsevier 2004. pp.1273-24.
- Rydholm A, Berg NO. Epidemiology of Soft tissue sarcoma in locomoter system. A retrospective population based study of interrelationships between clinical and morphological variables. Acta Pathol Microbiol Immunol Scand 1984;92A:363.
- Weiss SW, Goldblum JR. General Considerations. Chapter-1 In: Enzinger and Weiss's Soft Tissue Tumors. 4th Edition, St. Louis: Mosby 2001. pp.1-19.
- Kransdorf MJ. Benign soft tissue tumors in a largerefferral population: Distribution of specific

- diagnosis by age, sex and location. *Am J Roentgenol.* 1995;164:395.
6. Poissonnet CM, Burdi AR, Garn SM: The chronology of adipose tissue appearance and distribution in the human fetus. *Early Hum Dev* 1984;10:1.
 7. JL, Goldblum JR, Dobrow DA, et al. Giant bilateral extra-adrenal myelolipoma. *Arch Pathol Lab Med* 1995;119:283.
 8. Casadei GP, Scheithauer BW, Hirose T, et al. Cellular schwannoma: A clinicopathologic DNA flow cytometric and proliferation marker study of 71 cases. *Cancer* 1995;75:1109.
 9. Gonzalez Campora R. Fine needle aspiration cytology of soft tissue tumors. *Acta Cytol.* 2000 May-June 44(3):337-43.
 10. John R Goldblum, Andrew L Folpe, et al. (2014) *Enzinger & Weiss's Soft Tissue Tumours*. 6th edition Philadelphia. Elsevier 1.
 11. Iyer VK. Cytology of soft tissue tumors: Benign soft tissue tumors including reactive, nonneoplastic lesions. *J Cytol* 2008;25(3):81-86.
 12. Johnson CJD, Pynsent PB, Grimer RJ. Clinical features of soft tissue sarcomas. *Annals of the Royal College of Surgeons of England* 2001;83(3):203-05.
 13. Katenkamp K, Katenkamp D. Soft tissue tumors: new perspectives on classification and diagnosis. *Dtsch Arztebl Int.* 2009;106(39):632-6.
 14. Poissonnet CM, LaVelle M, Burdi AR. Growth and development of adipose tissue. *J Pediatr* 1988;113:1-9.
 15. Naik V, Hoogar M.B, Sahu S, et al. Histomorphological Profile and Clinicopathological Correlation of Soft Tissue Tumours: A Study at a Tertiary Care Teaching Hospital. *International J Health Sci Res* 2018;8(9):35-42.
 16. Zope RD, Janice Jaison, Joshi SR. Histopathological spectrum of soft tissue tumors in a rural Tertiary Care teaching hospital. *J Med Sci Clin Res* 2017;5(7):25492-5.
 17. Navya Narayan O, Sapna M, Sumangala B. Spectrum of soft tissue tumors in a tertiary care centre. A 5 year study. *Nath J Med Dent Res* 2016;4(2):83-8.
 18. Umarani MK, Prime Suchita Lakra, Bharathi M. Histopathological Spectrum of Soft Tissue Tumors in a Teaching Hospital. *IOSR I Dent Med Sci* 2015;14(4):74-80.

