

Retrospective Study to Evaluate The Importance of Histopathological Examination of Appendectomy Specimens

Anusha N

Author's Affiliation: Associate Professor, Deptment of Pathology, Vinayaka Missions Medical College and Hospital Karaikal, Puducherry 609609, India.

Corresponding Author: Anusha N, Associate Professor, Deptment of Pathology, Vinayaka Missions Medical College and Hospital Karaikal, Puducherry 609609, India.

E-mail: drgrwife@yahoo.com

How to cite this article:

Anusha N. Retrospective Study to Evaluate The Importance of Histopathological Examination of Appendectomy Specimens. Indian J Pathol Res Pract 2020;9(3):247-252.

Abstract

Introduction: The appendix though a vestigial organ in humans, appendectomy is one of the most commonly performed surgical procedures on emergency basis. Pathologic evaluation of these specimens may reveal unexpected findings occasionally.

Aim: A retrospectively study was done to determine histological diagnosis of acute appendicitis and its complications, negative appendectomy rate and unusual histopathological findings.

Materials and Methods: Histopathological records of 240 patients (Male: Female: - 152:88) who underwent appendectomy for acute appendicitis between April 2017 to March 2020 at a rural center in Puducherry. The patient's age, sex, macroscopic and histopathological examination findings were noted.

The specimens with unusual histopathological findings were re-evaluated in detail regarding patient's demography and its clinicopathological implications.

Results: Out of 240 cases the peak age of incidence of appendicitis was between 16 to 30 years in both sexes. Histological data showed acute appendicitis in 228(95%) which includes acute phlegmonous 148(65%), lymphoid hyperplasia 46(20%), gangrenous appendicitis 18(8%), perforated 9 (4%) and with unusual histopathological findings in 7 (3%).

Negative appendectomy rate was 5% and it was seen in females between age group of 16 to 30 years.

Conclusion: Our study shows higher number of appendicitis in young adults and negative appendectomy rate in females of reproductive age group. So we recommend all appendectomy specimens even having normal gross appearance should undergo routine histopathological examination to avoid any clinically important and treatable conditions.

Keywords: Acute appendicitis; Histopathology; Appendectomy.

Introduction

Appendicitis is the most common acute condition of the abdomen and most frequently treated with emergency appendectomy.¹ If treated early, it reduces the complications such as perforation, peritonitis and mortality. But how ever early diagnosis and emergency surgery had led to increase in the number of negative appendectomy.²

The life time risk in every person for appendicitis

is 7%, commonly occurring in adolescents and young adults.³ Various etiologies for this condition have been identified. But luminal obstruction is considered the most important factor as it triggers the inflammatory process. Obstruction of the lumen is mostly due to fecolith, lymphoid hyperplasia or fibrosis, other unusual factors have rarely been associated with the condition. Which includes mucocele, helminths, tuberculosis, adenovirus and rarely by appendiceal malignancies and lymphoma.



Aberrant findings which occur in small percentage of these patients can have major consequences.⁴

Despite advances in imaging modalities and laboratory investigations, there are difficulties in clinical diagnosis of acute appendicitis.⁵ Histopathological examination still remains gold standard for confirmation, but practice of sending resected specimens for histopathological study varies among hospitals as there are no proper guidelines to whether all appendix to be sent as a matter of routine, as it is justified by the rarity of aberrant findings and cost of specimen processing. Though intraoperative normal appendix may have abnormal incident finding at cytology which may impact on patient management.^{6,7}

This retrospective study was performed to study the various histological diagnosis (non-neoplastic and neoplastic) of all appendectomy specimens and to find out age and sex correlated to appendicitis. And we also attempted to find the rate of negative appendectomy in our hospital.

Materials and Methods

This retrospective study was carried out at Vinayaka Missions Medical College and Hospital, Karaikal over a period of three years between April 2017 to March 2020. Karaikal is a rural coastal center with approximate population of two lakhs. Medical records of 240 patients (Male: Female: - 152:88) who underwent appendectomy (either open or laparoscopic) for acute appendicitis including age, sex, brief clinical history, physical examination, operative findings, available relevant investigations and histopathological findings were evaluated.

We had an inclusion and exclusion criteria for our study.

Inclusion Criteria

- All patients above 16 to 70 years of both sex.
- All patients with only Acute appendicitis.

Exclusion Criteria

- Appendectomy incidental to other surgeries.
- Appendectomy due to chronic appendicitis.

Based on histopathological findings specimens were classified either positive or negative for acute appendicitis features. Positive specimens showed some pathology due to obstruction with features of inflammation.

Negative appendectomy was defined as one which appeared macroscopically and histopathologically normal with no clue of inflammation. The specimens with unusual histopathological findings were re-evaluated in detail. The case notes of these patients were further examined for subsequent investigations, follow-ups and outcomes. Data were statistically evaluated with IBM SPSS statistics for windows, version 20, IBM corp, Chicago, Illinois.

Results

Total of 240 specimens which was received for histopathological examination all went emergency appendectomy. Most cases underwent open surgery 186 (77.7%) and the remaining laparoscopic procedure. There were 158 males (65%) and 88 females (35%), the male female ratio was 1.8:1. The mean age of male was 29 years, female was 24.5 years both ranging from 16 to 70 years. Most number of cases were in the age group between 16 to 30 years with 51.2% in males and 61.3% in females. The distribution of acute appendicitis according to age group is shown in Table 1.

Table 1: Distribution of acute appendicitis according to age group.

Age group	Male 158(65%)	Female 88(35%)
16-30	81	54
31-40	36	16
41-50	23	11
51-60	11	5
61-70	6	2

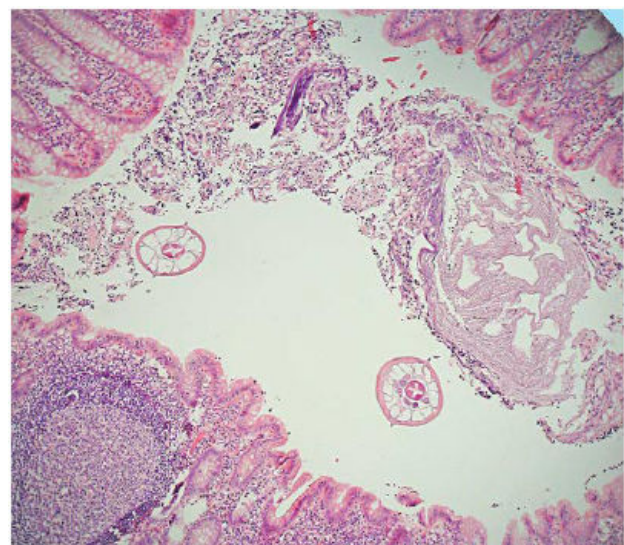


Fig. 1: Photomicrograph of *Enterobius vermicularis* infiltration in appendix (H&E stain, 100x).

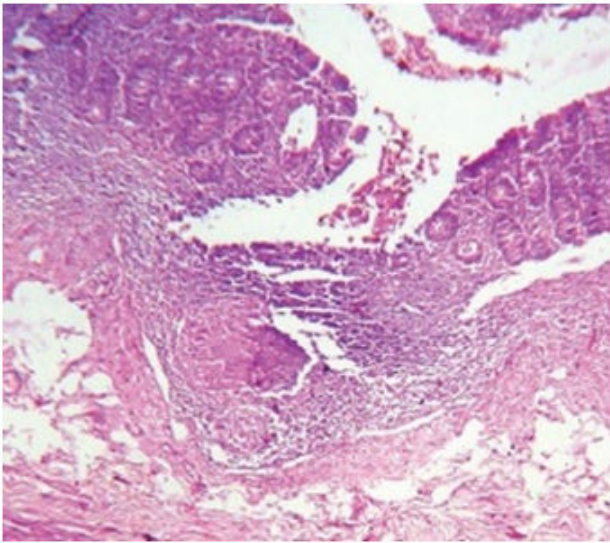


Fig. 2: Photomicrograph of Granulomatous infiltration of appendix with secondary Tubercular infection (H&E stain, 100x).

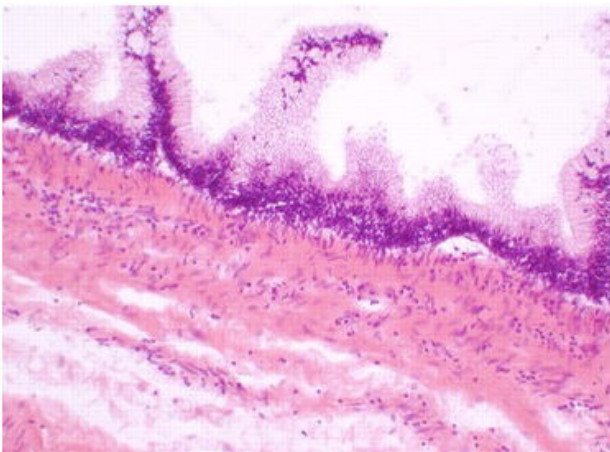


Fig. 3: Photomicrograph of Mucinous cyst adenoma of appendix (H&E stain, 100x).

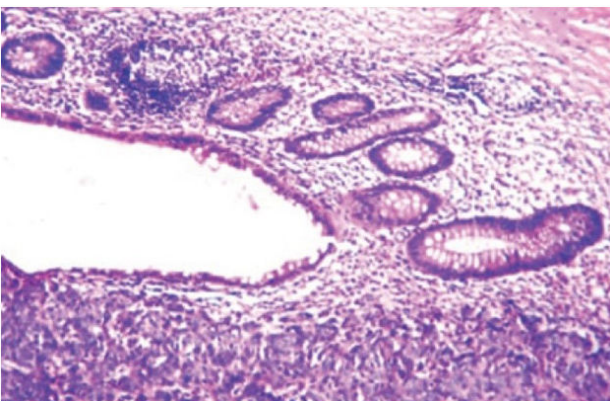


Fig. 4: Photomicrograph showing solid nests, cords and islands of tumor cells in mucosa and submucosa in carcinoid appendix (H&E stain, 100x).

According to clinical history and examination findings recorded in case sheets has shown most patients presented with pain in the right iliac

fossa in 192 (80%), followed by fever 149 (62%) and generalized abdominal pain 29 (12%). The other associated symptoms reported were nausea, vomiting, anorexia and paralytic ileus.

Investigating blood reports showed increase in total leukocyte count (>11,000) was found in 200 (83%) and neutrophilia (neutrophils >75%) was seen in 226 (94%) of the patients. Other findings such as increase in body temperature, fall in hematocrit and urine pus cells had no significant association with acute appendicitis.

Most case records did not mention the position of appendix, any associated inflammatory findings with or without perforation. Of 192 case records had recorded the intraoperative position of appendix of which showed retrocaecal in 154 (80%), pelvic in 29 (15%), pre-ileal in seven (3%), post-ileal and subcaecal one each.

The patients were divided in to two groups on the basis of histopathological findings.

1. Positive appendectomy rate.
2. Negative appendectomy rate.

In our study 228 (95%) patients had a positive appendectomy rate, which was further subclassified into, acute phlegmonous, gangrenous, perforated, suppurate, lymphoid hyperplasia and unusual histopathological findings. As illustrated in Table 2.

Table 2: Histopathological classification of 228 specimens with acute appendicitis.

Type of appendicitis	No. of patients	Percentage
Acute phlegmonous	148	65
Lymphoid hyperplasia	46	20
Gangrenous	18	8
Perforated	9	4
Unusual histopathological findings	7	3

We had seven cases with unusual pathological findings, Enterobius vermicularis in three cases, granulomatous inflammation secondary to tuberculosis in two cases, mucinous cyst adenoma and carcinoid tumor with one case each.

Negative appendectomy rate was 5% (12 cases) and all cases were in females between age group of 16 to 30 years.

Discussion

Acute appendicitis is the most common general surgical emergency and appendectomy is the

most frequently performed abdominal procedure. In developing countries the incidence is on increase due to the adaption of western diet and lifestyle.³ The incidence varies by country, race, socioeconomic status, dietary habits, geographic region, hygiene, age and sex. In western world acute appendicitis accounts for 40% of all surgical emergency.⁸ The incidence of appendicitis roughly parallels the lymphoid development with peak incidence occurring between the age of 10 and 30 years. The sex ratio is equal before puberty, the ratio gradually doubles in male by the age of 25 years.^{9,10} In our study the overall ratio was 1.8:1.

The patients usually presents with pain in right iliac fossa, its necessary to rule out other possible surgical and non-surgical causes of pain. The signs and symptoms associated with acute appendicitis have sensitivity of 16 to 100 % and specificity of 36 to 95%.¹¹ In our study the most common presentation was right iliac fossa pain followed by fever. Other diagnostic modalities and imaging may be useful but none had a definitive advantage over a careful examination and clinical history. Increased neutrophils and total leukocyte count aided in the diagnosis of acute appendicitis with right iliac fossa pain.¹² In our study more than 83% of cases had both neutrophilia and increase in leukocytes, similar to other studies.^{12,13}

The histopathological examination of appendix has two purpose, first to diagnose acute appendicitis in a intra operatively normal appendix, second additional histopathological findings that are not evident on gross examination intra operatively and helps in the subsequent clinical management of the patient.¹⁴

In our study 228 (95%) patients had a positive appendectomy rate, which was further sub classified into, acute phlegmonous (65%), gangrenous (8%), perforated (4%), lymphoid hyperplasia (20%) and unusual histopathological findings (3%). The findings of appendix with gangrene and perforation shows delay in seeking medical help. As our center is rural and patients with low literacy rate have presented for treatment very late hence, so we had a perforation rate of 4% which is higher than observed in other studies. Fecoliths were found to be common cause of obstruction of the lumen in all cases of gangrenous appendicitis with perforation leading to peritonitis which is a grave abdominal emergency hence timely diagnosis and treatment of appendicitis is necessary. Children less than five years, HIV positive patients and elderly more than 65 years of age have highest rate of perforation.¹⁵

In our study, seven patients (3%) with

acute appendicitis presented with unusual histopathological findings as similar to other studies. Parasitic infestation is one of the causes of obstruction of the lumen of appendix leading to appendicitis, profuse infiltration with eosinophils warrants a search for intra luminal parasite, and we had two cases of enterobius vermicularis (Fig. 1). Parasite infection of the intestinal system often present with generalized symptoms, such as perianal irritation, tenesmus, flatulence, loss of appetite and inability to gain weight. Worldwide the incidence of enterobius infestation presenting with symptoms of appendicitis ranges from 0.2 to 41.8%. These patients can be treated by anti-helminthic therapy hence surgery could be avoided.^{4,16}

Granulomatous appendicitis may rarely present as acute appendicitis, it can be caused by infectious and noninfectious factors. Crohns disease and Sarcoidosis most commonly present in western world. As tuberculosis is endemic in our country we had two case of secondary tuberculosis mimicking appendicitis (Fig. 2). In our study the incidence was 0.8%, the incidence of this rare condition has been reported as 0.14% to 0.3% in western world and as 1.3% to 2.3% in underdeveloped countries.^{17,18}

We had two cases of malignancy, mucinous cyst adenoma and carcinoid one each, disguised as appendicitis.^{19,20} Mucinous cyst adenoma are premalignant may be associated with synchronous large bowel lesions, hence our patient was advised for colonoscopy and oncology follow up (Fig. 3). Carcinoids are typically small, firm, circumscribed yellowish lesions and can produce appendicitis either by luminal obstruction by releasing vasoactive inflammatory mediators such as five hydroxytryptamine, histamine, and kinin. In our study the tumor was found at the tip of the appendix with less than 1cm hence appendectomy alone was sufficient, patient did not have any features of Carcinoid syndrome (Fig. 4).

Our study did not have a spectrum of unusual pathological findings as our sample size was very small, since our center was a rural costal center, with only three years of retrospective study period and our study included only cases of acute appendicitis.

Negative appendectomy rate was 5% (12 cases), which falls within the acceptable range of 3 to 20 % and in our study all cases were females between age group of 16 to 30 years. Therefore especially in females with appendicitis other causes of abdominal pain should be searched out if the appendix appears normal during surgery and a more focused utilization of preoperative imaging is necessary in females of reproductive age group.^{21,22}

Conclusion

Our study highlights the importance of histopathological examination of every single resected appendix, as it remains gold standard method for confirming acute appendicitis. As intraoperative detection of abnormal appendix by the surgeon is mostly unreliable. So we recommend all appendectomy specimens to be examined by histopathological analysis routinely. We recommend long term follow up should be offered in patients with granulomatous and neoplastic lesions.

References

1. Marudanayagam R, Williams GT, Rees BI. Review of the pathological results of 2660 appendicectomy specimens. *J gastroentrol* 2006;41:745-9. <https://pubmed.ncbi.nlm.nih.gov/16988762>
2. Lee Jh, Park YS, Choi JS. The epidemiology of appendicitis and appendectomy in South Korea: National Registry Data. *J Epidemioln*2010;m20:97-105 <https://www.ncbi.nlm.nih.gov/pmc/articles/PMC3900807>.
3. Chandrasegaram MD, RothwellLA, An EI, Miller RJ. Pathologies of appendix: a 10-year review of 4670 appendectomy specimens. *ANZ J Surg* 2012; 82:844-847. <https://pubmed.ncbi.nlm.nih.gov/22924871>.
4. Akbulut S, Tas M, Sogutcu N, Arikanoglu Z, and Basbug M, Ulku A. Unusual histopathological findings in appendicectomy specimens: a retrospective analysis and literature review. *World J gastroenterol.* 2011; 17(15):1961-1970. <https://pubmed.ncbi.nlm.nih.gov/21528073>.
5. Nemeth L, Reen DJ, O Briain D, Mc Dermott M, PuiP. Evidence of an inflammatory pathologic condition in normal appendices following emergency appendectomy. *Arch Path Lab Med.* 2001 Jun;125(6):759-64. <https://pubmed.ncbi.nlm.nih.gov/11371227>.
6. Menon I, Moorpani K, Rehman S. Unusual histopathological findings of appendicectomy specimens. *Pak J Med Dent* 2014;3(3):3-7. <https://www.ncbi.nlm.nih.gov/pmc/articles/PMC3082748>.
7. Unusual histopathological findings in appendectomy specimens from patients with suspected acute appendicitis PMID: PMC3703189. *World J Gastroenterol* 2013 Jul 7;19(25):4015-22. <https://pubmed.ncbi.nlm.nih.gov/23840147>.
8. Edino ST, Mohammed AZ, Ochicha O, Anumah M. Appendicitis in Kano. Nigeria: A 5 year review of pattern, morbidity and mortality. *Ann Afr Med.* 2004;3(1):38-41. <https://www.ncbi.nlm.nih.gov/pmc/articles/PMC4445528>.
9. Khairy G. Acute appendicitis: is removal of a normal appendix still existing and we can reduce its rate? *Saudi J Gastroenterol.* 2009;15(3):167-170. <https://www.ncbi.nlm.nih.gov/pmc/articles/PMC2841415>.
10. Seetahal SA, Bolorunduro OB, Sookdeo TC, Oyetunji TA, Greene WR, Fredrick W. Negative appendectomy: a 10 year review of nationally representative sample. *Am J Surg.* 2011;201(4):433-437. <https://pubmed.ncbi.nlm.nih.gov/21421095>.
11. Henna E, Sammalkorpi, PanuMentula, Ari Leppanemi. A new adult appendicitis score improves diagnostic accuracy of acute appendicitis-a prospective study. *BMC Gastroenterol.*2014;14:114. <https://www.ncbi.nlm.nih.gov/pmc/articles/PMC4087125>.
12. R. Williams, K. Mackway-Jones. White cell count and diagnosing appendicitis in adults. *Emerg Med J.* 2002 Sep; 19(5): 429-430. <https://www.ncbi.nlm.nih.gov/pmc/articles/PMC1725968>.
13. Yasemin Ustundag Budak, Murat Polat, Kagan Huysal. The use of platelet indices, plateletcrit, mean platelet volume and platelet distribution width in emergency non-traumatic abdominal surgery: a systematic review. *Biochem Med (Zagreb)* 2016 Jun 10; 26(2): 178-193. <https://www.ncbi.nlm.nih.gov/pmc/articles/PMC4910273>.
14. Alun E Jones, Alexander W Phillips, Kevin Sargen. The value of routine histopathological examination of appendicectomy specimens. *BMC Surg.* 2007; 7: 17. <https://www.ncbi.nlm.nih.gov/pmc/articles/PMC1976308>.
15. O'Connell PR. The vermiform appendix. In: Russell RC, Williams NS, Bulstrode CJ, editor. *Bailey and Love's 26th ed.* London: Arnold Hodder; 2010. p. 1203-18.
16. Ali Taghipour, Meysam Olfatifar, Ehsan Javanmard, Mojtaba Norouzi, Hamed Mirjalali, Mohammad Reza Zali. The neglected role of *Enterobius vermicularis* in appendicitis: A systematic review and meta-analysis. *PLoS One.* 2020; 15(4). <https://www.ncbi.nlm.nih.gov/pmc/articles/PMC7179856>.
17. Abdul Gaffar B. Granulomatous disease and granulomas of the appendix. *Int J Surg Pathol.*2010;18(1):14-20. <https://pubmed.ncbi.nlm.nih.gov/20106828>.
18. Arif Emre, Sami Akbulut, Zehra Bozdog, Mehmet Yilmaz, Murat Kanlioz, Rabia Emre, Nurhan Sahin. Routine histopathologic examination of appendectomy specimens: retrospective analysis of 1255 patients. *Int Surg oct-dec*2013;98(4):354-362. <https://pubmed.ncbi.nlm.nih.gov/24229023>.
19. Komm M, Kronawitter-fesl M, Kremer M, Lutz

- L, Holinski-Feder E, Kopp R. Primary mucinous adenocarcinoma of the vermiform appendix with high grade microsatellite instability. *J Cancer*. 2011; 2: 302-306 <https://www.ncbi.nlm.nih.gov/pmc/articles/PMC3119391>.
20. Yuqing Gu, Naichao Wang, Hongxing Xu. Carcinoid tumor of the appendix: A case report. *Oncol Lett*. 2015 May; 9(5): 2401-2403. <https://www.ncbi.nlm.nih.gov/pmc/articles/PMC4467319>.
21. Korner H, Sondenna K, Soreide J. Incidence of acute non-perforated and perforated appendicitis; Age specific and sex specific analysis. *World J Surg*. 1997; 21(3): 313-317. <https://pubmed.ncbi.nlm.nih.gov/9015177>.
22. Mohammad Ayub Jat, Farhan Khashim Al-Swailmi, Yasir Mehmood, Majid Alrowaili, Shehab Alanazi. Histopathological examination of appendicectomy specimens at a district hospital of Saudi Arabia. *Pak J Med Sci*. 2015 Jul-Aug; 31(4): 891-894. <https://pubmed.ncbi.nlm.nih.gov/26430424>.

