

## A Cadaveric Study on Variations in Origin of Profunda Femoris Artery in Haryana Population

Meetu Agarwal<sup>1</sup>, BK Mishra<sup>2</sup>, Devesh Kumar Sharma<sup>3</sup>

### How to cite this article:

Meetu Agarwal, BK Mishra, Devesh Kumar Sharma/A Cadaveric Study on Variations in Origin of Profunda Femoris Artery in Haryana Population/Indian J Anat. 2021;10(1):19-22.

**Author's Affiliation:** <sup>1</sup>Assistant Professor, <sup>2</sup>Professor & Head, <sup>3</sup>Tutor, Department of Anatomy, Al Falah School of Medical Science & Research centre, Dhauj, Faridabad 121004, Haryana, India.

**Corresponding Author:** Devesh Sharma, Tutor, Department of Anatomy, Al Falah School of Medical Science & Research centre, Dhauj, Faridabad 121004, Haryana, India.

**E-mail:** sharmadevesh306@gmail.com

### Abstract

**Introduction:** The femoral artery is the continuation of external iliac artery and it enters the femoral triangle behind the inguinal ligament at mid-inguinal point (mid-Point between the anterior superior iliac spine and pubic symphysis). The profunda femoris artery usually arises from the lateral aspect of the femoral artery. The anatomical knowledge of the profunda femoris artery is very important to prevent inadvertent damage to it during clinical procedures.

**Aim and Objectives:** Aim of the present study was to discuss the variations in origin of the profunda femoris artery and their clinical significance.

**Materials and Methods:** The study was conducted on 40 lower limbs in 20 embalmed human cadavers of unknown age, from the Department of Anatomy of Al-Falah School of Medical Science and Research Center, Dhauj, Faridabad.

**Results:** The most common site of origin of PFA is lateral aspect of FA. In the present study done on 40 lower limbs we found lateral, posterolateral, posterior and medial origins of profunda femoris artery. The most common range of the distance of origin of PFA from midinguinal point was 21 - 30 mm.

**Conclusion:** This study will be very helpful to the surgeons, radiologist and plastic surgeons to understand possible variations in Profunda femoris artery while performing procedures on FA.

**Key Words:** Femoral Artery; Profunda Femoris Artery (PFA); Inguinal Point.

### Introduction

The femoral artery is the continuation of external iliac artery and it enters the femoral triangle behind the inguinal ligament at mid-inguinal point (mid-Point between the anterior superior iliac spine and pubic symphysis). The profunda femoris artery usually arises from the lateral aspect of the femoral artery (3.5 cm below the mid-inguinal point). Near its origin the medial and lateral circumflex femoral arteries arise from the profunda femoris artery.<sup>1</sup> The femoral artery is commonly used for arterial catheterization (second choice for cannulation) as it is easily accessible.

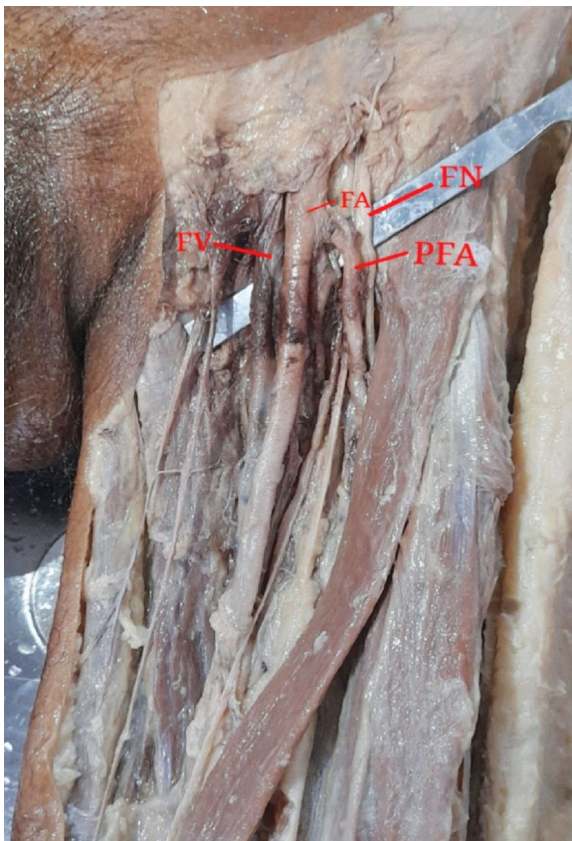
It is used for investigating the arterial system anywhere in the body and for various clinical procedures, like coronary angioplasty. For femoral embolectomy, in case of lower limb arterial thromboembolism, the femoral artery in the femoral triangle is directly opened at the origin of the profunda femoris artery. In all these cases the anatomical knowledge of the profunda femoris artery is very important to prevent inadvertent damage to it during clinical procedures.<sup>2</sup> The course of femoral vessels and origin of profunda femoris artery have long received attention from both anatomists and surgeons.

**Materials and Methods**

The study was conducted on 40 lower limbs in 20 embalmed human cadavers of unknown age from the Department of Anatomy of Al-Falah School Of Medical Science And Research Center, Dhauj, Faridabad. The Femoral triangle of the lower limbs were dissected in embalmed cadavers and exposed according to Cunningham’s Manual of Practical Anatomy by the help of dissecting instruments (scalpel, scalpel blade, blunt scissors, pointed scissors, blunt forceps, and pointed forceps).

**Results**

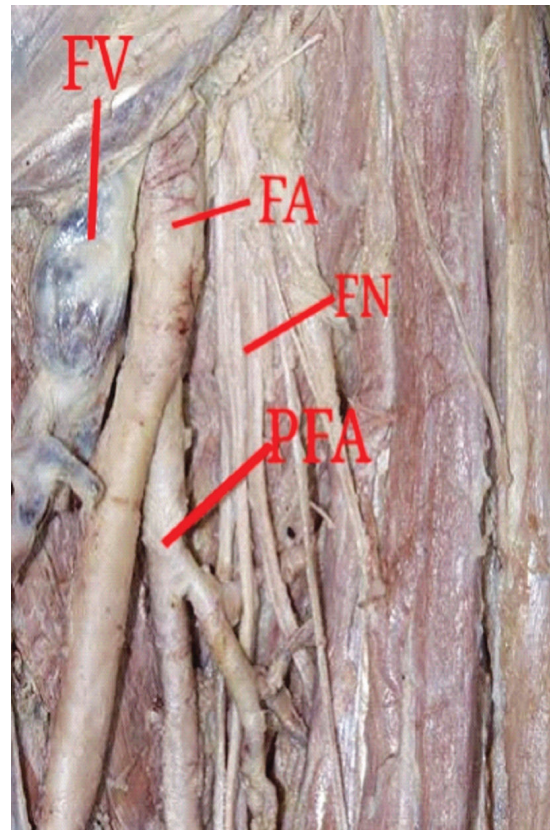
The most common site of origin of PFA is lateral aspect of FA. In present study done on 40 limbs we found that in 32/40 limbs PFA originated from lateral aspect of FA (Figure-1). In 5/40 limbs PFA originated from posterior aspect of FA (Figure-2) and in 2/40 limbs PFA originated from posterolateral aspect of FA (Figure-3). In 1/40 limbs PFA originated from medial aspect of FA (Figure-4). [Table no. 1]



**Fig.1:** PFA originating from lateral aspect of FA.

In present study the distance from mid-inguinal point to the origin of PFA was between 10 - 20 mm in 2 limbs of the right side and 4 limbs of the left side. The range of 21 - 30 mm was found in 9 limbs

of the right side and 7 limbs of the left side. This distance of 31-40 mm was found in 4 limbs of the right side and 3 limbs of the left side and 41-50 mm was found in 3 limbs of the right side and 3 limbs of the left side. This distance is 51 - 60 mm was found in 1 limbs of the right side and 2 limbs of the left side and the distance is 61-70 mm was found in 1 limbs of the right side and 1 limbs of the left side. [Table no. 2]



**Fig. 2:** PFA originating from posterior aspect of FA.

**Table 1 :** Position of origin of PFA.

Position	Right	Left
Posterior	3	2
Posterolateral	0	2
Lateral	16	16
Medial	1	0

**Table 2 :** Distance From Midinguinal point to origin of PFA.

Range (mm)	Right	Left
10-20	2	4
21-30	9	7
31-40	4	3
41-50	3	3
51-60	1	2
61-70	1	1

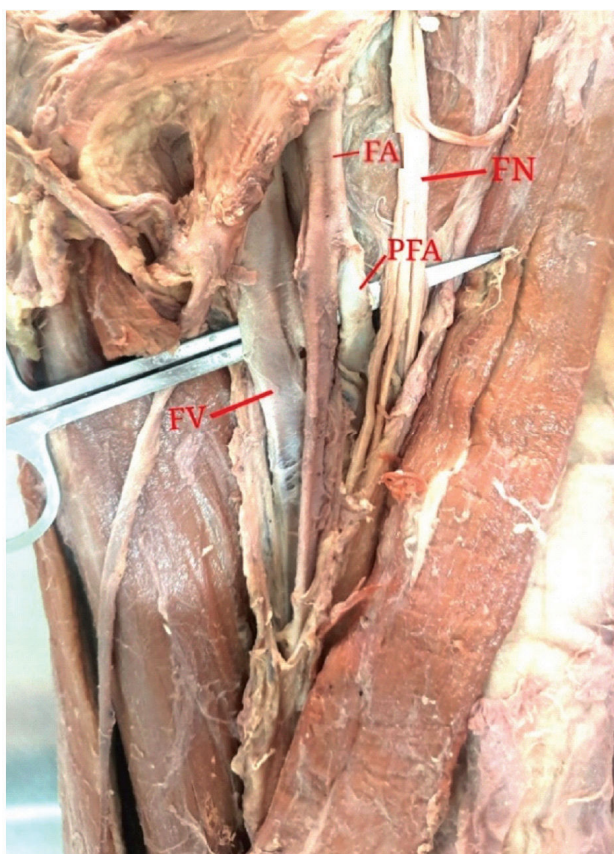

Fig. 3: PFA originating from posterolateral aspect of FA.

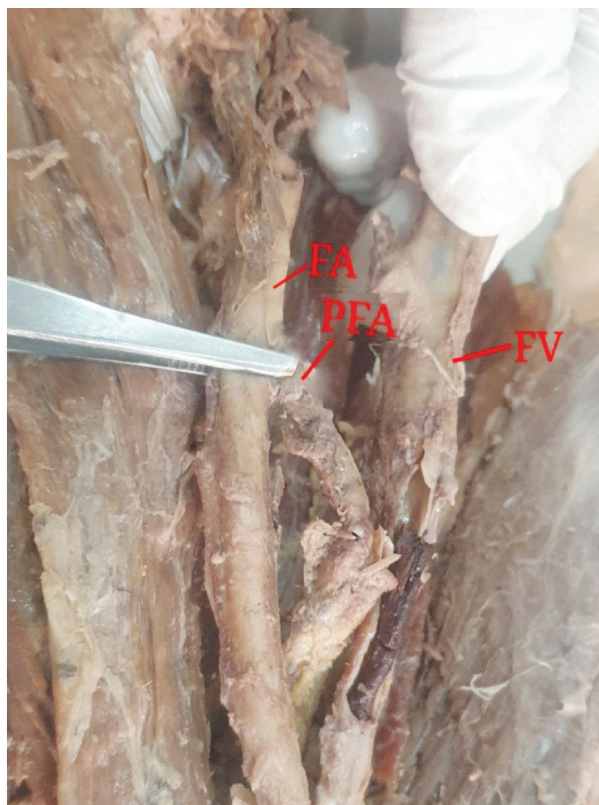

Fig. 4: PFA originating from medial aspect of FA.

## Discussion

Profunda femoris artery is a branch of the internal iliac artery in the lower animals. As a result of evolution, the origin shifted distally from the internal iliac artery to the femoral artery. 'Ontogeny repeats phylogeny'. Arrest at different stages of development may lead to anatomical variations related to the division of the femoral artery. VAAS F<sup>3</sup> and Siddharth P<sup>4</sup> reported that the profunda femoris artery acts as a collateral vessel in the occlusion of the femoral artery and for this important function, it has to have a large caliber, which can be explained based on the aforementioned comparative anatomy. To avoid the iatrogenic femoral arteriovenous fistula formed during puncture of femoral artery the anatomical knowledge of the level of origin is important. The different anatomical relationships and lack of knowledge of variations of these vessels make the haemostasis difficult to manage.<sup>5</sup>

The anatomical knowledge of variations of femoral artery and its branches is important as these arteries are frequently accessed in the present modern era by surgeons and radiologists for number of procedures like coronary angiography, balloon valvuloplasty, percutaneous valves, hip joint replacement etc.<sup>6</sup>

The various variations in the origin of profunda femoris and its branches are described in the literature. Anatomical variations regarding the level of the division of the femoral artery have been reported and explained by studies done by different authors. Dixit et al.<sup>7</sup> observed distance 31-40 mm on right side and between 41-50 mm on the left side. Prakash et al.<sup>6</sup> noted this distance to be 4.2 cm. Siddharth P et al observed as 4.4 cm<sup>4</sup>. Vedat Sabancıogulları et al.<sup>8</sup> recorded the distance of the origin point of PF to the midpoint of the inguinal ligament was found to be 5.6 cm in the right and 2.2 cm in the left. This distance is very important in order to locate the PF while performing cannulation of femoral artery.

In present study the distance from mid-inguinal point to the origin of PFA was between 10 - 20 mm in 2 limbs of the right side and 4 limbs of the left side. The range of 21 - 30 mm was found in 9 limbs of the right side and 7 limbs of the left side. This distance of 31-40 mm was found in 4 limbs of the right side and 3 limbs of the left side and 41-50 mm was found in 3 limbs of the right side and 3 limbs of the left side. This distance is 51 - 60 mm was found in 1 limbs of the right side and 2 limbs of the left side and the distance is 61-70 mm was found in 1 limbs of the right side and 1 limbs of the left side.)

The most common site of origin of PFA is lateral aspect of FA. In present study done on 40 limbs we found that in 32/40 limbs PFA originated from lateral aspect of FA. In 5/40 limbs PFA originated from posterior aspect of FA and in 2/40 limbs PFA originated from posterolateral aspect of FA. In 1/40 limbs PFA originated from medial aspect of FA. (Table no. 1) But few authors consider posterolateral and lateral side origin is the most common pattern.

The medial origin of PF carries a risk of damage to this large and unexpected arterial channel while collecting blood in infants from FV and during exposure of saphanous veins for ligation its junction with the FV.<sup>9</sup>

### Conclusion

According to the present study the most common site of origin of PFA was from lateral side of FA. A rare variation was also found where the PFA was arising from medial side of FA. To avoid the iatrogenic femoral arteriovenous fistula formed during puncture of femoral artery, the anatomical knowledge of the level of origin is important. The different anatomical relationships and lack of knowledge of variations of these vessels make the haemostasis difficult to manage during procedures.

The anatomical knowledge of variations of femoral artery and profunda femoris artery is important as these arteries are frequently accessed in the present modern era by surgeons and radiologists for number of procedures like coronary angiography, balloon valvuloplasty, percutaneous valves, hip joint replacement etc.

### Reference

1. AK Datta, Superior and inferior extremities, Essential of human anatomy. Ed 4th (2009), p;167.
2. MB Samarawickrama, BG Nanayakkara et al, Branching pattern of the femoral artery at the femoral triangle: a cadaver study, galle medical journal. 2009;14(1):31-34.
3. VAAS F, Some considerations concerning the deep femoral artery, Arch ChirNeerl, 1975;27(1):25-34.
4. Siddharth P, Smith NL, Mason RA, Giron F. Variational anatomy of the deep femoral artery. AnatRec. 1985; 212(2):206-09.
5. M Baptist, F Sultana, T Hussain. The origin of profunda femoris artery, its branches and diameter of the femoral artery. Professional Med J.2007;14:523-27.
6. Prakash, Kumari J., Bhardwaj AK, Jose BA, Yadav SK, Singh G. Variations in the origins of the profundafemoris, medial and lateral femoral circumflex arteries: a cadaver study in the Indian population. Romanian Journal of Morphology and Embryology. 2010; 51(1):16770.
7. Dixit Daksha, Kubavat Dharati, Rathod Sureshbhai, PateldMital, SingelTulsibhai. A Study of Variations in the Origin of Profunda Femoris Artery and Its Circumflex Branches. Int J Biol Med Res. 2011; 2(4):1084-9.
8. VedatSabanciogullari, Kosar MI, EkremOlcu, Mehmet Cimen. The deep femoral artery and branching variations: a case report. Cumhuriyet Med J. 2009; 31: 279-82.
9. Daksha Dixit, Dharati M Kubavat, Suresh Bhai P Rathod, Mittal M Patel, Tulsi Bhai C Singel. A study of variation in origin of profundafemoris artery and its circumflex branches. Int J Biol Med Res. 2011;2(4):1084-89.