

## Original Research Article

## A Clinicopathological Study of Nasopharyngeal Angiofibroma and C-Kit Expression

M Sandhya Rani

Professor, Department of Pathology, Mamatha Medical College, Bachupally, Hyderabad, Telangana 500090, India.

**Corresponding Author:**

**M Sandhya Rani**, Professor, Department of Pathology, Mamatha Medical College, Bachupally, Hyderabad, Telangana 500090, India.

**E-mail:** [drsandhyarani12@gmail.com](mailto:drsandhyarani12@gmail.com)

**How to cite this article:**

M. Sandhya Rani. A Clinicopathological Study of Nasopharyngeal Angiofibroma and C-Kit Expression. Indian J Pathol Res Pract 2020;9(2 Part II):181-188.

**Abstract**

**Aims:** To analyze clinical parameters, histomorphological features of Nasopharyngeal angiofibroma.

**Materials and Methods:** The present study is a retrospective and prospective study conducted for 6 ½ yrs. duration in a total of 7222 head and neck cases operated, out of which 78 cases were diagnosed as juvenile nasopharyngeal angiofibroma. All patients were evaluated with routine lab investigations and all clinical features noted. The patients were investigated with x-ray and CT head and neck.

**Results:** Incidence of juvenile nasopharyngeal angiofibroma was 1.08% of head and neck tumours. In all the cases were male incidence was high in second decade. The tumour tissue was lined by pseudostratified epithelium in 52 cases (66.66%) followed by squamous (metaplastic) in 14 cases (17.94%). Remaining 12 cases showed ulceration and granulation tissue. The calibre of vascular channels was studied in detail showed 36 cases (48.71%) with small thin nonmacular followed by 29 cases which showed large thin nonmuscular vessels. Stroma was composed of plump cells, edematous and fibrous components. Out of 78 cases, 45 cases (57.69%) were composed of mixed pattern with any of the two or all three components. Secondary changes like thrombus, hemorrhage and necrosis were observed in 17 cases. 25 sections rich in stromal cells were selected and subjected to immunohistochemistry-C-kit. Out of 25 cases 23(92%) showed high to moderate immunoexpression and 2 cases (8%) showed weak positivity. C-kit expression was seen in all cases of nasopharyngeal angiofibroma with 92% of high expression.

**Conclusions:** Study showed new hope and promise of application of C-kit expression in nasopharyngeal angiofibromas to evaluate the response to imatinib therapy.

**Keywords:** Nasopharyngeal; Angiofibroma and C-Kit.

**Introduction**

Juvenile nasopharyngeal angiofibroma is one of the most common benign nasal cavity tumors of adolescence. Though malignant neoplasms represent a large proportion, the reported incidence of nasopharyngeal fibroma is 14% of all nasopharyngeal growth and 0.5% of all head and neck tumor. The nasopharyngeal angiofibroma is a benign yet biologically aggressive tumor. It originates

almost exclusively from the posterior nasal and nasopharyngeal region in adolescent males. Thus, it has been known as juvenile Angiofibroma. The term Angiofibroma denotes a vascular swelling presenting in the nasopharynx of pre-pubertal and adolescent males and exhibiting tendency to bleed. Much of the literature concerning etiology and treatment was speculative and controversial.

There is now general agreement that this is exclusively a disease of males and that the mean



age at presentation is around 14 years. The range however is wide and varies between 7 and 19 years with isolated cases presenting earlier or later.<sup>1</sup>

The usual clinical behavior of the tumor is one of the expensive growths with a potential for intracranial extension. Histologically Angiofibroma is composed of fibrous connective tissue interspersed with variable proportions of endothelium lined spaces. A preponderance of fibroma stroma may indeed allow surgical removal with relative ease in some cases. However, even with advances in surgical and arterial embolization techniques. The intraoperative blood loss is still major concern. The capacity for spontaneous regression of angiofibroma at sexual maturity is doubtful. The suggestion that the total regression in the late teens or early twenties has never been convincingly demonstrated. Although most authorities concede that some shrinkage hardening and lesions of vascularity of the swelling occur with age.

Treatment of this tumor is matter of interest. Rare occurrence of this tumor is probably the reason for such varying experiences and opinion regarding the best method of therapy earlier, surgical treatment used to be more hazardous with a high recurrence rate. Radiation and hormonal therapy were tried to reduce the size and vascularity of the tumor. Dangers of surgery led to search for other modalities of treatment.

## Material and Methods

The present study is Retrospective and Prospective study was conducted on 78 patients. Material included was cases diagnosed as nasopharyngeal angiofibroma. Clinical parameters were retrieved from medical records. Resected specimens were sent to pathology department where Gross examination of the specimens was done and representative sections 3-5 per case was chosen. Specimens were fixed in 10% buffered formalin and processed by automatic tissue processor. Routine paraffin embedding was done and 4U sections were stained with Haematoxylin and eosin and the tissue sections were examined microscopically. Critical analyses of growth patterns according to Stiller and Kuttner was done. Sections rich in stromal cells were chosen for immunohistochemistry, for expression of C-KIT

Representative paraffin blocks were selected from each and immunohistochemistry was performed. 6 cases of inflammatory nasal polyps were also subjected to Immunohistochemistry for C-kit.

## Staining Pattern: Cytoplasmic.

Avidin/Biotin Blocking may be needed to block endogenous biotin activity for certain tissues such as kidney, liver, prostate, colon and gut, which may contain endogenous biotin.

As standard IHC was performed using the polyclonal anti CD 117 antibody in 1:200 dilution. A standard technique was performed using polymer HRP detection system. A Case of C-kit positive GIST was used as positive control and a case of Schwannoma and Leomyoma were used as negative control. Cells displaying distinct cytoplasmic immunoreactivity were considered positive and semiquantitative scoring of C-kit expression in stromal cells was done.

Semiquantitative scoring system (Zhang et al) was adopted for C-kit expression in Nasopharyngeal angiofibroma

-ve: Negative (none of the cells express positivity)

+ve: Weak reactivity (irrespective of % of cells < 25% of positive cells)

++ ve: Moderate reactivity < 75% or > 25% of positive cells

+++ve: Strong reactivity > 75% of positive cells

C-kit expression in stromal cells of nasal polyps were compared with C-kit expression in stromal cells of NPA. Statistical analysis was done and 'p' value was calculated.

## Results

The present study Neck tumors during the period were 7222 and total number of juvenile nasopharyngeal angiofibroma cases analysed were 78. All the cases were males, and age ranged from 7-25yrs. The average age was 16yrs. The incidence of Nasopharyngeal Angiofibroma was higher in second decade.

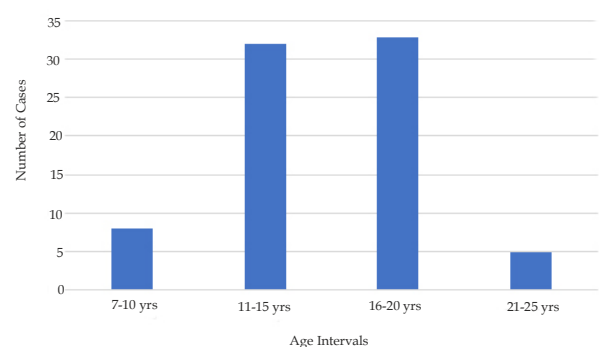


Fig. 1: Age Incidence in Present Study.

Age ranged from 7-25yrs average age was 16yrs. Incidence was high in seconddecade. (Fig. 1)

**Table 1:** Analysis of Symptoms and Signs at Presentation.

Presenting symptoms	No of cases	Percentage
Nasal obstruction	70	90%
Epistaxis	62	80%
Headache and facial swelling	35	45%
Other symptoms (Anosmia, Deafness, Nasal Discharge)	31	40%
Presenting Signs	—	—
Nasal Mass	62	79%
Proptosis	16	21%
Facial Swelling	14	18%

The symptoms at presentation of all the cases were analysed. Signs and Symptoms were present for an average of 6 months prior to the diagnosis. Nasal obstruction was the presenting symptoms in 70 cases (90%), especially in initial stages. Epistaxis was seen in 62 cases (80%). Headache and facial swelling were encountered in 35 cases (45%).

Other symptoms like Anosmia, deafness, nasal discharge, otalgia were the presenting symptoms in 31 cases (40%).

Nasal mass was the predominant sign seen in 62 cases (79%) followed by proptosis seen in 16 cases (21%) facial Deformity was seen in 14 cases (18%).

On Clinical gross examination the juvenile nasopharyngeal angiofibroma was a lobulated, non-encapsulated mass, usually pink -grey or purple-red. (Table 1)

Recurrence was observed in 16 cases (21%)

#### X Ray Findings

Nasopharyngeal soft tissue mass, widening of the pterygopalatine fissure, enlargement of the superior orbital tissue in patient with proptosis. Distortion of the nasal septum erosion and opacification of the paranasal sinuses.

Holman Miller Sign: Anterior bowing of posterior wall of the maxillary sinus.

CT Scan findings confirmed the presence of the tumour and extension of the tumour- intracranial extension was recorded in 3 cases (4%) of Nasopharyngeal Angiofibroma.

#### Microscopic Examination

78 cases of Nasopharyngeal Angiofibroma were examined by Histopathological examination by

light microscopy of Haematoxylin and eosin stained sections. The tumour is composed of angiomatous and fibromatous elements, the angiomatous elements composed of gaping vascular channels differing in calibre and are lined by a single layer of epithelium and surrounded single or mostly an incomplete rim of smooth muscle cells. The stromal component was composed of plump cells. Oedematous and fibrous tissue. The tumour showed a characteristic zonal organization. Apart from the superficial epithelium the lesions can be subdivided into a subepithelial myxoid-fibrous zone followed by a proliferative capillary fibroblastic cambium layer. In the latter, either the capillary component for the fibroblasts can prevailed. The main part is composed of sinus the vascular channels and a fibrous component. The gaping vascular channels differing a calibre are lined by a single layer of epithelium and surround by single or mostly a complete rim of smooth muscle cells. The fibrous component exhibits a changing cellularity and fibre content. Myxoid foci were encountered, often associated with a pleomorphic cell pattern. In older lesions the fibrous tissue was prevailing in 16 cases of relapse, same structural features were observed.

**Table 2:** Cell Morphology in the Nasopharyngeal tumours

Changes in surface epithelium	No of cases	Percentage
Pseudostratified	52	(67%)
Squamous (metaplastic)	14	(18%)
Ulcerated/granulation tissue	12	(15%)
Blood vessels morphology	—	—
Small thin non-muscular	35	(45%)
Large thin non-muscular	24	(31%)
Large thin muscular	4	(5%)
Large thick muscular	3	(4%)
Small thin muscular	7	(9%)
Small thick muscular	5	(6%)
Stromal morphology	—	—
Mixed Pattern	45	58%
Predominant Plump Cells	20	26%
Predominant Fibrous	8	10%
Predominant Oedematous	5	6%

The surface epithelium was pseudostratified epithelium, squamous (metaplastic) and few cases showed only ulceration and granulation tissue.

52 cases (67%) showed pseudostratified epithelium and minority of the cases showed Ulceration/granulation tissue and 14 cases (18%) showed squamous (metaplastic) and the remaining 12 cases (15%) showed ulceration and granulation tissue.

Small thin muscular blood vessels were the predominant vascular lining seen in 35 cases (45%) followed by large vessels with thin non-muscular lining observed in 24 cases (31%). Small thin muscular lining was seen in 7 cases (9%) followed by large thin muscular seen in 4 cases (5%).

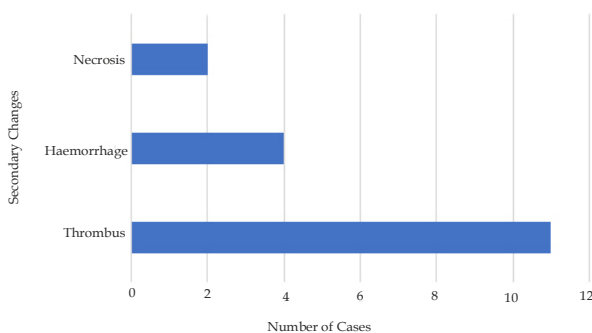
Thick muscular lining is rare finding seen predominantly in sections from the case of the tumour. Small thick muscular in 5 cases (6%) and Large thick muscular lining was seen in 3 cases (4%). The above vascular growth pattern was accompanied by characteristic staghorn type of vessels.

45 Cases (58%) showed mixed pattern . Predominant pattern was plump cells in 20 (26%) cases and 8 Cases (10%) were with predominant fibrous component only 5 cases(6%) showed predominant oedematous component. (Table 2)

*Inflammatory Infiltrate*

Chronic inflammatory infiltrate was seen in very few cases but majority of the cases were with insignificant inflammation.

Chronic inflammatory infiltrate was observed in 23 cases (30%) with focal to extensive ulceration with space infiltrate in 7 cases (9%) and diffuse infiltrate in 16 cases (21%) and the remaining 55 cases did not show any significant inflammatory infiltrate.



**Fig. 2:** Secondary Changes i n Present Study.

Out of 17 cases which showed secondary changes, 11 cases (14%) showed thrombus and 4 cases (5%) showed haemorrhage and rest of the 2 cases (3%) showed necrosis. (Fig 2)

*Immunoexpression of C-Kit in Nasopharyngeal Angiofibroma*

Paraffin blocks of 25 cases, rich in stromal cells were selected and subjected to systematic

Immunohistochemical study with C-kit. Only cytoplasmic positivity in stromal cells was considered. Semi-quantitative scoring was done in 25 cases according to Zhang et. al.

**Table 3:** C-Kit Expression in Nasopharyngeal Angiofibroma.

Intensity	Strong	Moderate	Weak	Negative	Total
No of cases	19	4	2	Nil	25
Percentage	76%	16%	8%	Nil	100%

Out of 25 cases, 19 cases (76%) showed strong positivity, 4 cases (16%) showed moderate positivity and 2 cases ( 8%) showed weak positivity. Total percentage positivity was 100%. (Table 3)

In the present study C-kit reactivity was seen in all 25 cases of nasopharyngeal angiofibroma with 92% of cases showing high to moderate expression of C-kit. 8 % of cases had weak positivity. All cases of Nasopharyngeal Angiofibroma expressed C-kit expression. Immunoexpression was good in stroma rich areas that in fibrous areas. 6 cases of nasal polyps were also subjected to immunohistochemistry C-kit for comparison with cases of Nasopharyngeal Angiofibroma.

**Table 4:** C-Kit Expression in Nasal Polyp.

Intensity	Strong	Moderate	Weak	Negative
No of cases	-	-	1	5
Percentage	-	-	16.6%	83.33%

Out of 6 cases of nasal polyps subjected to immunohistochemistry C-kit, one case showed weak positivity and remaining 5 cases showed no immunoexpression.

**Table 5:** Statistical Significance in Present Study.

	Total no of cases	Positive	Negative
Test	25(ab)	23(a)	2(b)
Control	6(cd)	1(c)	5(d)

$$\chi^2 = \frac{(ad-bc)^2 * N}{(a+b) (c+d) (a+c) (b+d)}$$

$$= \frac{(23 * 5 - 2)^2 * 31}{25 * 6 * 24 * 7} = 17.830 = <0.001$$

P value= <0.001 the statistical analysis revealed that ( value of significance-‘p’) was < 0.001 which is highly significant, showing expression of C-kit in nasopharyngeal angiofibroma is strong. (Table 5)

**Table 6:** Comparison of Present Study with Other Authors.

Author	Period of study	No of cases	Incidence
Misra and mishra et al <sup>2</sup>	26yrs	93	1 in 1,108 cases
Tapia et al <sup>3</sup>	6yrs	70	
Reddy KA et al <sup>4</sup>	21yrs	15	
James D et al <sup>5</sup>	31yrs	40	
Nong D et al <sup>6</sup>	21yrs	45	
Present study	6 1/2 yrs	78	1 in 398 cases

**Table 7:** Comparison of Immunohistochemistry-C kit expression of present study with other studies.

Studies	Strong	Moderate	Weak	Negative	No of cases
Zhang et al <sup>8</sup>	75%	25%	0%	0%	15
Present study	76%	16%	8%	0%	25

## Discussion

Juvenile nasopharyngeal angiofibroma (JNA) is a rare nasopharyngeal fibrovascular tumour that occurs exclusively in the nasopharynx of adolescent boys. Histologically, it is composed of poorly defined but bland stromal cells and an irregular vascular proliferation.<sup>69</sup> Despite its bland histologic features, JNA typically behaves as a locally aggressive tumour.

Misra and Mishra et al<sup>2</sup> who studied 93 cases reported incidence as 1 in 1,108 admitted patients. Reported incidence of nasopharyngeal fibroma varies from 1 in 6000 to 16,000 patients attending ear, Nose and throat clinics as reported by Patterson et al.<sup>7</sup> In Mexico, Tapia et al<sup>3</sup> found 70 cases in 6 yrs. In recent literature the Incidence is 0.5% of head and neck tumors. In the present study we encountered 7222 cases of head and neck tumors out of which 78 cases were Juvenile nasopharyngeal angiofibroma. The incidence in our study is 1.08% of head and neck tumors. In the present study age ranged from 7-25 yrs, average age was 16yrs at the time of surgery. Incidence is high in the 2<sup>nd</sup> decade. According to Zhang et al<sup>8</sup> all patients with juvenile nasopharyngeal angiofibroma were male and ranged in age from 11 to 23 years old (average age, 17 years) at the time of the surgery. All the patients were males. The age ranged from 13 to 24 years with mean of 16.3 years. According to Sao Paulo et al.<sup>9</sup> all the juvenile nasopharyngeal angiofibroma patients were males and the age at the time of operation ranged from 11 to 23 years (25). (Table 6)

The site of origin of juvenile nasopharyngeal angiofibroma is usually broad-based, on the posterolateral wall of the nasal cavity. From its origin, tumor spreads into the nasal cavity and nasopharynx, displacing the soft palate inferiorly and sometimes becoming visible through the mouth. At the same time, the tumor extends laterally through the sphenopalatine foramen into the pterygomaxillary fossa. From there the juvenile nasopharyngeal angiofibroma exerts pressure on the surrounding bony walls. Anteriorly it pushes forward the posterior wall of the maxillary sinus, creating the classic 'antral bowing sign' visible by x-ray. Posteriorly, it disrupts the root at the pterygoid plates. Superiorly, tumor expands into the orbit via the inferior orbital fissure continuing eventually into the superior fissure, it widens the fissure's lower lateral margin, another sign commonly seen radiographically. With further lateral expansion, the tumor will pass through the pterygomaxillary fissure into the infratemporal fossa, often creating a bulging of the cheek. If it reaches the temporal fossa, the tumor can create a bulge above the zygoma. The ultimate danger of unchecked by juvenile nasopharyngeal angiofibroma is intracranial extension. The tumor reaches the cranial vault through three paths. The two lateral paths are through the superior orbital fissure and directly through the greater wing of the sphenoid bone from the pterygomaxillary and infratemporal fossae. These paths bring juvenile nasopharyngeal angiofibroma up lateral to the carotid artery and cavernous sinus. The medial path, which can bring tumor into contact with the pituitary and optic chiasm, leads directly through the sphenoid sinus and Sella turcica, medial to the carotid and cavernous sinus.

Denker et al<sup>10</sup> observed one case where intracranial extensions took place through the foramen ovale. Patient died during the operation for tumor removal. The growth was found to indent the temporal lobe. Goldsmith et al<sup>11</sup> described a similar growth eroding the case of the skull. Patient died due to circulatory failure.

In India 4 cases of nasopharyngeal fibroma with evidence of intracranial extensions have been recorded by Misra and Bhatia. Two cases had widened foramina laceram. On X-ray examinations. This case was a doctor, who was operated 20 years back in Govt. E.N.T Hospital, Hyderabad.

Symptoms are present for an average of 6 months prior to the diagnosis, commonly with extension beyond the nasopharynx. The patients present with frequent epistaxis or blood tinged nasal discharge, nasal obstruction and rhinorrhoea, conductive

hearing loss from Eustachian-tube obstruction. Diplopia, which occurs secondary to erosion into the cranial cavity and pressure on the optic chiasm, rarely anosmia, recurrent otitis media, and eye pain.

In the present study 70 cases (90%) presented with nasal obstruction followed by epistaxis in 62 cases (80%). Headache and facial swelling was the presenting symptom in 35 cases (45%), other symptoms like anosmia, deafness and nasal discharge in 31 cases (40%)

Witt TR, shah JP, Sternberg SS.et.al<sup>12</sup> reviewed, thirty-one patients. In his study all the patients were male adolescents whose presentations were characterized by epistaxis (73 percent) and nasal obstruction (60 percent).

Excessive bleeding can occur. With improvement in diagnostic imaging techniques and preoperative embolization, the need for blood transfusion has been greatly reduced. Low-grade consumption coagulopathy may complicate small juvenile nasopharyngeal angiofibroma and implies that preoperative coagulation screening may have a role in perioperative haemostasis. Transient blindness has been reported as a result of embolization, but it is a rare occurrence. Osteoradionecrosis and/or blindness due to optic nerve damage may occur with radiotherapy. Fistula of the palate at the junction of the soft and hard palate may occur with the trans palatal approach but is prevented by preservation of the greater palatine vessels during flap elevation. Anaesthesia of the cheek is a frequent occurrence with the Weber Ferguson incision.

Hill et al<sup>13</sup> mentioned the case in a boy who developed pneumocephalus during radiotherapy for nasopharyngeal fibroma. X-ray skull showed a stalk like shadow running upwards and forward from the tumour to the pneumocele, indicating the tract of the tumour extending from the nasopharynx to the pneumocephalus. Patient recovered with conservative treatment. Hunter et al<sup>14</sup> also reported a case of nasopharyngeal fibroma surviving for 10 years with intracranial extension which showed destruction of the basisphenoid on X-ray examination. Reddy K.et.al<sup>4</sup> analyzed 15 patients treated with radiation therapy for juvenile nasopharyngeal angiofibroma (JNA). Two patients had local recurrences and both were salvaged with surgery for an ultimate local control rate 100%. Late complications included cataracts in 3 patients, delayed transient central nervous system (CNS) syndrome in 1 patient, and a basal cell carcinoma of the skin in 1 patient of 15 patients, 13 (85%) had a complete response (CR) on physical

examination following radiation therapy. Chen KT et al<sup>15</sup> studied a case of fibrosarcoma arising in a recurrent nasopharyngeal angiofibroma 18 yrs after radiation therapy. Makek MS et al<sup>16</sup> reported fibrosarcoma in a nasopharyngeal patient over 20 year period after 4 surgical procedures and 2 courses of radiation therapy.

In the present study, the recurrence in NPA was observed in 16 cases (21%). Lloyd G,et. al<sup>17</sup> postulated that the principal determinant of recurrence is a high tumor growth rate at the time of surgery coupled with incomplete surgical excision. The ability to remove the tumour in toto is principally due to deep invasion of the sphenoid. He feels that the fibroblastic growth factor influences the angiogenesis. Mature type tumors have no recurrence after excision and reveal more collagenization and believes that the autocrine and pericrine influence of interferon-alpha, Prostaglandin and Heparin. According to him invasion of the skull base affected two-thirds of the patients, and the rate of recurrence was 27.5%. Mistry Rajesh et al<sup>18</sup> did retrospective observation study of patients with juvenile nasopharyngeal angiofibroma who presented at the Tata Memorial Hospital. The reported recurrence rate following treatment of juvenile nasopharyngeal angiofibroma was 12.5%.

Brunner et al<sup>19</sup> suggested and origin and from the conjoined pharyngo basilar and buccopharyngeal fascia. Recent documentation of androgen receptors, in these tumor has but some support to hormone dependent theory due to oestrogen-androgen imbalance. Recent studies demonstrate oestrogen and progesterone receptors in juvenile nasopharyngeal angiofibroma but gonadotrophin levels were normal.

In the present study, on gross clinical examination the juvenile nasopharyngeal angiofibroma was a lobulated, firm, non-encapsulated mass, usually pink or purple red.

On microscopic examination the tumour is composed of angiomatous and fibromatous elements. The angiomatous elements composed of gaping vascular channels differing in calibre are lined by a single layer of epithelium and surrounded by single or mostly an incomplete rim of smooth muscle cells. The stromal component was composed of plump cells, oedematous and fibrous tissue.

78 tumours of patients 7 to 25 years of age were investigated. The tumour showed a characteristic zonal organization. Apart from the superficial

epithelium the lesions can be divided into a subepithelial myxoid-fibrous zone followed by a proliferative capillary fibroblastic cambium layer. In the latter, either the capillary component for the fibroblasts prevailed. The main part is composed of sinus-like vascular channels and a fibrous component. The gaping vascular channels differing in calibre are lined by a single layer of epithelium and surround by single or mostly an incomplete rim of smooth muscle cells. The fibrous component exhibits a changing cellularity and fibre content. Myxoid foci can be encountered, often associated with a pleomorphic cell pattern. In older lesions the fibrous tissue was prevailing. In 16 cases of relapses same structural features were observed.

The surface epithelium was pseudostratified epithelium, squamous (metaplastic) and few cases showed only ulceration and minority of the cases showed ulceration/granulation tissue and 14 cases (18%) showed squamous (metaplastic) and the remaining 12 cases (15%) showed ulceration and granulation tissue.

The calibre of vascular channels was studied and categorized in detail which was Small thin muscular blood vessels was the predominant vascular lining seen in 35 cases (45%) followed by large vessels with thin non-muscular lining observed in 24 cases (31%). Small thin muscular lining was seen in 7 cases (9%) followed by large thin muscular seen in 4 cases (5%). Thick muscular lining is a rare finding seen predominantly in sections from the base of the tumour. Small thick muscular in 5 cases (6%) and Large thick muscular lining was seen in 3 cases (4%). The above vascular growth pattern was accompanied by characteristic staghorn type of vessels.

Stroma was composed of plump, edematous and fibrous components out of which majority of the tumours were composed of mixed pattern with all the three components or any of the two components. 45 cases (58%) showed mixed pattern predominant pattern was plump cells in 20 (32%) cases and 8 cases (11%) were with predominant fibrous component. Only 5 cases (7%) showed predominant oedematous component.

Chronic inflammatory infiltrate was seen in very few cases but majority of the cases were with insignificant inflammation. Chronic inflammatory infiltrate was observed in 23 cases (30%) with focal to extensive ulceration with sparse infiltrate in 7 cases (9%) and diffuse infiltrate in 16 cases (21%) and the remaining 55 cases did not show any significant inflammatory infiltrate.

In the present study secondary changes like thrombus, haemorrhage and necrosis were observed in 17 cases. Out of 17 cases which showed secondary changes. 11 cases (14%) showed thrombus and 14 cases (5%) showed haemorrhage and rest of the 2 cases (3%) showed necrosis.

Beham.et.al.<sup>20</sup> Studied thirty -two cases of nasopharyngeal angiofibroma including 2 recurrences, According to him most of the tumour vessels. Which lacked elastic laminae, were characterized by vascular walls of irregular thickness and variable muscle content. All cells of the vessel wall showed immunoreactivity for vimentin and smooth muscle actin, whereas desmin-positive cells were present only in small numbers in some vessels. Lack of elastic laminae and elastic stromal fibres, can be held responsible for the typical pronounced tendency for haemorrhage in these lesions. Beham A et.al<sup>20</sup> studied vascular architectural features which showed discontinuous vascular basal lamina, focal lack of pericytes, and pronounced irregularities of the smooth muscle layers. He also studied the immunohistochemical and electron microscopical characterization of stromal cells in nasopharyngeal angiofibroma's. According to him the typical stromal cells in nasopharyngeal angiofibroma's were fibroblasts and not myofibroblasts. In recurrent tumours there is greater cellularity. Clumps of endothelial cells, extravascular red blood corpuscles, plump fibroblasts, mast cells and pericytes than in non-recurrent tumours.

In the present study 25 cases/paraffin blocks, rich in stromal cells were selected and subjected to systematic immunohistochemical study with C-kit. Classical tissue pattern rich in stromal cells formed the study material. Only cytoplasmic positivity in stromal cells was considered. C-kit a biological marker was expressed in stromal cells was assessed by semiquantitative method.

## Conclusion

Nasopharyngeal angiofibroma is a tumour which occurs in young males associated with bleeding nose known to be recurrent in spite of extensive surgery, radiotherapy and hormonal therapy with a possibility of intracranial involvement and its sequelae, needs alternate therapy.

In the present study we have observed overexpression of C-kit in nasopharyngeal angiofibroma. This finding should be further evaluated with molecular methods and its strong

expression in juvenile nasopharyngeal angiofibroma might be potentially important in offering Imatinib mesylate as an alternate treatment for patients with juvenile nasopharyngeal angiofibroma.

## References

1. Wang H, Seow A, Lee HP. Trends in cancer incidence among Singapore Malays: a low-risk population. *Ann Acad Med Singapore* 2004; 33: 57-62
2. Mishra S, Praveena NM, Panigrahi RG, Gupta YM. Imaging in the diagnosis of juvenile nasopharyngeal angiofibroma. *J Clin Imaging Sci.* 2013;3(Suppl 1):1.
3. Tapia, J.L., Goldberg, L.J. The Challenges of Defining Oral Cancer: Analysis of an Ontological Approach. *Head and Neck Pathol* 5, 376-384 (2011).
4. Shair, K.H.Y.; Reddy, A.; Cooper, V.S. New Insights from Elucidating the Role of LMP1 in Nasopharyngeal Carcinoma. *Cancers* 2018, 10, 86.
5. Yong SK, Ha TC, Yeo MC, Gaborieau V, McKay JD, Wee J. Associations of lifestyle and diet with the risk of nasopharyngeal carcinoma in Singapore: a case-control study. *Chin J Cancer.* 2017;36(1):3. Published 2017 Jan 7. doi:10.1186/s40880-016-0174-3
6. Nong LG, Luo B, Zhang L, Nong HB. Interleukin-18 gene promoter polymorphism and the risk of nasopharyngeal carcinoma in a Chinese population. *DNA Cell Biol.* 2009;28:507-513.
7. Hwang HC, Mills SE, Patterson K, Gown AM. Expression of androgen receptors in nasopharyngeal angiofibroma: an immunohistochemical study of 24 cases. *Modern Pathology.* 1998;11(11):1122-1126.
8. Zhang M, Sun X, Yu H, Hu L, Wang D. Biological distinctions between juvenile nasopharyngeal angiofibroma and vascular malformation: an immunohistochemical study. *Acta Histochem.* 2011;113:626-630.
9. São Paulo: Sociedade Brasileira de Otorrinolaringologia. *Tratado de otorrinolaringologia* 2 Ed.: Roca Biomedicina; 2003. p.701
10. Denker et al. Juvenile nasopharyngeal angiofibroma. *European Archives of otorhinolaryngology* : April: 1984, vo1239 Number 3.
11. Goldsmith BJ, Wara WM, Wilson CB, Larson DA. Postoperative irradiation for subtotally resected meningiomas. A retrospective analysis of 140 patients treated from 1967 to 1990. *J Neurosurg.* 1994;80(2):195-201.
12. Witt TR, Shah JP, Sternberg SS. Juvenile nasopharyngeal angiofibroma: a 30 year clinical review. *Am J Surg.* 1983;146:521-525.
13. Alun-Jones T, Hill J, Leighton SE, Morrissey MS. Is routine histological examination of nasal polyps justified? *Clin Otolaryngol Allied Sci.* 1990 Jun;15(3):217-219.
14. Hunter B, Silva S, Youngs R, Saeed A, Varadarajan V. Long-term stenting for chronic frontal sinus disease: case series and literature review. *J Laryngol Otol.* 2010 Nov;124(11):1216-1222.
15. Chen PG, Bassiouni A, Wormald PJ. Incidence of middle turbinate lateralization after axillary flap approach to the frontal recess. *Int Forum Allergy Rhinol.* 2014 Apr;4(4):333-338.
16. Makek MS, Andrews JC, Fisch U. Malignant transformation of a nasopharyngeal angiofibroma. *Laryngoscope.* 1989;99(10 Pt 1):1088-1092.
17. Lloyd G, Howard D, Lund VJ, Savy L. Imaging for juvenile angiofibroma. *Journal of Laryngology and Otology.* 2000;114(9):727-730.
18. Mistry, Rajesh and Qureshi, Sajid and Gupta, Shaikat and Gupta, Sameer. (2005). Original Article - Juvenile nasopharyngeal angiofibroma: A single institution study. *Indian journal of cancer.* 42. 35-9.
19. Brunner C, Urbschat S, Jung V, Praetorius M, Schick B, Plinkert PK. Chromosomal alterations in juvenile angiofibromas. *HNO.* 2003;51(12):981-985.
20. Beham A, Kainz J, Stammberger H, et al: Immunohistochemical and electron microscopical characterization of stromal cells in nasopharyngeal angiofibromas. *Eur Arch Otorhinolaryngol* 1997: 254(4): 196-9

