

## Cutaneous Manifestations In Relation to All Malignancies: A Retrospective and Prospective Study

Jayant P S Yadav<sup>1</sup>, Vividha Dubey<sup>2</sup>, Yusuf Malik<sup>3</sup>, Kailash Bhatia<sup>4</sup>, Saurabh Karnawat<sup>5</sup>,  
Virendra Bhandari<sup>6</sup>

**Author's Affiliation:** <sup>1,2,3</sup>Registrar, <sup>5</sup>Assistant Professor, <sup>6</sup>Professor & Head, Department of Radiation Oncology, <sup>4</sup>Professor & Head, Department of Skin & Venereal Diseases, Sri Aurobindo Medical College & PG Institute, Indore, Madhya Pradesh 452001, India.

**Corresponding Author:** Virendra Bhandari, Professor & Head, Department of Radiation Oncology, Sri Aurobindo Medical College & PG Institute, Indore, Madhya Pradesh, 452001

**E-mail:** [virencancer@yahoo.co.in](mailto:virencancer@yahoo.co.in)

### How to cite this article:

Jayant P.S. Yadav, Vividha Dubey et al./Cutaneous manifestations in relation to all malignancies: a retrospective and prospective study/ Indian J Canc Educ Res 2020;9(1):17-23.

### Abstract

**Introduction:** Cutaneous manifestations may be primary to a hidden primary condition or it can also be secondary to an underlying malignancy. An association between systemic malignancy and cutaneous manifestations has long been recognized. Metastasis to the skin is easily visible and can be detected by the physician with relative ease which enhances and emphasizes the role of the clinician in appreciating various appearance of these lesions. With increase in the incidence of cancer in India in the past few decades, it is essential to recognize neoplasms at early stages

**Materials and Methods:** Retrospective and prospective study was performed on 60 confirmed cases of all malignancies with cutaneous manifestations. Data regarding skin manifestation and malignancies were recorded from duration January 2017 to December 2019.

**Results:** Most of the patients were above 60 years with no sex discrimination. Most common cutaneous marker was paraneoplastic dermatoses (82%) followed by nonspecific manifestations in (18%). Most common cutaneous presentation were generalized pruritus (42%) followed by infections (22%), seborrheic keratosis (20%), xeroderma pigmentosum (8%) and generalized xerosis (8%). In males respiratory tract malignancies (42%), Gastro intestinal malignancies (30%), lymphomas (22%) and leukemias (6%) were main malignancies with skin manifestations and in females reproductive tract malignancies (48%), Carcinoma breast (30%) and oral cavity cancer (22%) were common.

**Conclusion:** Cutaneous manifestation from all malignancies is a relatively uncommon phenomenon but at times, they may be the only presenting feature. Cutaneous paraneoplastic syndromes are important clinical markers that may precede or occur simultaneously or after the diagnosis of a given neoplasm and recognizing them may lead to a higher chance of cure and better prognosis for the patient.

**Keywords:** Cutaneous Manifestation; Cancer; Paraneoplastic Syndromes

### Introduction

The skin often reflects internal processes. Some skin lesions are linked to cancers and may serve as "signposts" indicating the presence of a less visible internal cancer. Awareness of such skin changes may thus result in earlier diagnosis and treatment

of cancers. These skin lesions associated with cancers can be divided into 2 groups: Skin diseases linked to internal cancer and skin diseases due to the direct spread of internal cancers to the skin.

These skin diseases are often not intrinsically cancerous but may occur in individuals with internal



This work is licensed under a Creative Commons Attribution-NonCommercial-ShareAlike 4.0.

cancers. Some of them occur at the same time as the cancers. Some of these skin diseases disappear after the cancer has been surgically removed and reappear when the cancer recurs. Cutaneous manifestations of internal malignancies include metastases to the skin, malignancy-associated genodermatoses, dermatoses induced by environmental carcinogens, and paraneoplastic dermatoses<sup>1</sup>.

Metastases, genetic cutaneous malignancy syndromes, and carcinogen-induced skin conditions are conceptually more straightforward to understand. In contrast, less is known about paraneoplastic dermatoses, a broad group of clinical syndromes of coexistent internal malignancy and cutaneous inflammatory reaction that presents as a skin disorder<sup>2</sup>.

Pathogenesis of paraneoplastic syndromes is poorly understood, but such disorders may be caused by tumor production or depletion of biologically active hormones or growth factors. Alternatively, tumor-induced host immunologic response—for example, antigen cross-reactivity between tumor and skin—may cause skin changes.<sup>3</sup>

Paraneoplastic dermatoses generally become apparent at approximately the same time as the internal malignancies do, and they follow a parallel course<sup>4</sup>. In some cases, however, because cancer may be asymptomatic for years, skin changes may be recognized long before cancer is diagnosed<sup>5</sup>. When cutaneous changes herald a new or recurrent cancer, recognition of these conditions can lead to earlier detection and treatment of the underlying malignancy<sup>6</sup>. The skin lesions can occur as secondaries or as paraneoplastic syndromes or as a part of certain genetic syndromes<sup>7</sup>.

Curth proposed criteria by which a causal relationship between a dermatosis and a malignant internal disease might be evaluated. These requirements include the following: (a) Both conditions start at the same time, (b) both conditions follow a parallel course, (c) the condition is not recognized as a part of a genetic syndrome, (d) a specific tumor occurs with a certain dermatosis, (e) the dermatosis is not common, and (f) a high percentage of the association is noted<sup>2</sup>.

In a recent Indian study, skin changes were found in 27% of patients with internal malignancies. Cutaneous metastasis was seen in 6% and other skin lesions in 25%. Secondaries in the skin usually present as papules, plaques, and nodules, common site being the anterior abdominal wall. The skin is an infrequent site for metastasis and is only the eighteenth most common site. Cutaneous

metastases can arise at any age. However, in keeping with the increased incidence of malignant disease in later life, most cutaneous metastases occurred during or after the fifth decade<sup>8</sup>.

The anterior chest wall is reported as the most common site for cutaneous metastatic lesions, and it held good for this study as well wherein 32% of the lesions were in the chest wall. The morphological patterns of cutaneous metastases corresponded with the primary tumours and their evaluation helped localize unknown primary malignancies. In cases with known primaries, cutaneous metastases upstaged the malignancy and affected the prognosis<sup>4</sup>.

Direct tumor spread can occasionally arise after diagnostic or therapeutic interventions such as needle aspiration of a tumour, pleural biopsy, drainage of malignant ascites, or placement of other drains in the vicinity of a tumour. "Tumour spillage," direct contamination of wounds with tumor cells during a laparoscopy or surgical procedure, was once a problem in nearly 20% of cases but is now uncommon; laparoscopic port site metastasis rates and laparotomy wound metastasis rates due to direct tumour inoculation are both in the order of 0.8%<sup>9</sup>.

### Clinical Types of Cutaneous Disorders in all Malignancies

**Inherited Syndromes:** Many familial cancer syndromes have prominent dermatologic features. Often, the potential for internal malignancy is first suspected when the skin disease is recognized<sup>10</sup>.

**Various Inherited Syndromes Cutaneous syndromes:** Cowden syndrome, Gardner syndrome, Peutz-Jeghers syndrome, Muir-Torre syndrome, Howel-Evans syndrome, Birt-Hogg-Dubé syndrome, Hereditary leiomyomatosis/renal cell cancer syndrome, Melanoma/pancreatic cancer syndrome, Multiple mucosal neuromas syndrome, Neurofibromatosis type 1 and Inherited immunodeficiency syndromes.

**Hormone-Secreting Tumors:** Neoplastic proliferation of cells that can secrete a variety of biologically active amines and polypeptide hormones may result in characteristic symptom complexes associated with specific cutaneous changes. These conditions have been described as ectopic humoral syndromes<sup>11</sup>.

**Various hormone-secreting tumors cutaneous syndromes:** Ectopic ACTH syndrome, Carcinoid syndrome, Multiple endocrine neoplasia syndrome, Glucagonoma syndrome.

**Proliferative and Inflammatory Dermatoses:** Many of the conditions to be discussed in this section are nonspecific and have been reported both in association with and in the absence of underlying malignant disease. Thus, a diagnosis of any of these conditions mandates a complete physical examination but in no way guarantees that a tumor will be found. Malignancy is most often only one of several possible provoking factors.<sup>11</sup>

**Various proliferative and inflammatory dermatoses cutaneous syndromes:** Acquired hypertrichosis lanuginosa, Acanthosis nigricans, Sign of Leser-Trelat, Tripe palms, Bazex syndrome, Primary systemic amyloidosis, Scleromyxedema, Sweet's syndrome, Pyoderma gangrenosum, Blistering disorders, Dermatomyositis, Clubbing and related disorders, Cutaneous leukocytoclastic vasculitis, Coagulopathies, Figurate erythemas, Extramammary Paget disease, Infectious disorders, Generalized pruritus, ichthyosis, and exfoliative dermatitis, Pigmentary disorders, Miscellaneous skin, hair, and nail disorders. Cutaneous manifestations provide a challenge to the clinicians and dentists for treatment. A proper diagnosis of such cutaneous manifestations in a body is essential to treat the diseases early and betterment of the patients. The present study aimed to study the cutaneous manifestations of all malignancies in the central Indian population, as very few such studies have been done in this part of the country.

## Material & Methods

**Study design:** Prospective and retrospective type of study.

**Duration of Study:** January 2017 to December 2019.

The study included of 60 cases which were consecutive of histopathologically confirmed malignancy (excluding those of primary cutaneous malignancies and cases with cutaneous complications of treatment and HIV seropositivity) attending the indoor and outdoor facilities. All cases of dermatoses influenced by malignancy or antineoplastic therapy were also included in the study. An informed consent were obtained from all the patients after explaining the whole procedure and the aim behind conducting the study. Age, gender, carcinoma, cutaneous markers, cutaneous manifestations, carcinomas and cutaneous dermatoses were considered as the outcome variable. All the data analysis was performed using SPSS ver. 20 software. Frequency

distribution was performed to prepare the tables. Data is expressed as number and percentage.

## Results

Present study was performed to evaluate skin manifestations in relation to various malignancies. It was a retrospective study performed on 60 confirmed cases of internal malignancy with skin manifestations at our institute. Data regarding skin manifestation and malignancies were recorded from duration January 2017 to December 2019. Total registered patient were 6620 during January 2017 to December 2019. On follow up 60 case of either sex were included as per the inclusion and exclusion criteria. Based on the data analysis following observations were made;

The incidence of cutaneous manifestation in present study was 0.91 %. Majority of the patients were in the age group of >60 years of age [21 (35%)] followed by 21-30 years [12 (20%)] and 41-50 years [10 (16.7%)]. There were patients who had age between 51-60 years [7 (11.6%)] and 31-40 years [6 (10%)]. Four (6.7%) patients were very young ( $\leq 20$  years).

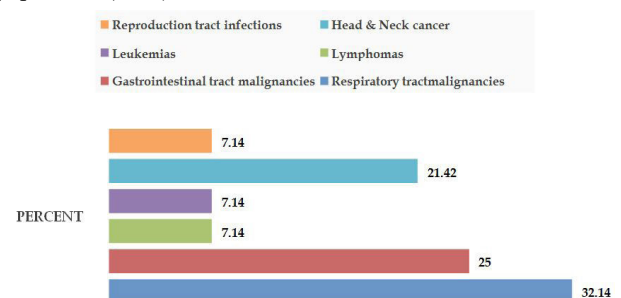
**Table 1:** Distribution of patients according to gender

Gender	No of patients	Percentage
Male	28	46.7
Female	32	53.3
Total	60	100

Majority of the patients were females [32 (53.3%)] followed by males [28 (46.7%)]. (Table 1)

It was found that most common carcinoma in male was respiratory tract malignancies [9 (32.14%)] followed by gastrointestinal tract malignancies [7 (25%)] and head & neck cancer [6 (21.42%)]. Out of 28 males, 2 (7.14%) patients each had lymphomas, leukemias and reproduction tract infections respectively. (Graph 1)

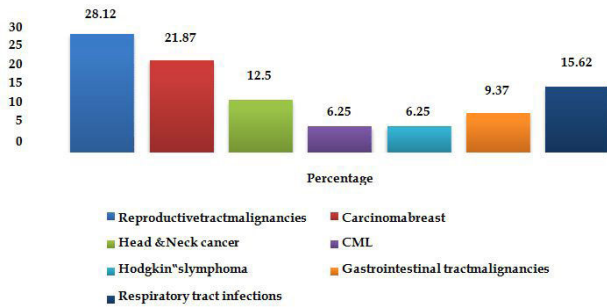
**Graph 1:** Descriptive analysis of carcinoma in the male population (n=28)



Majority of the females had reproductive tract malignancies [9 (28.12%)] followed by carcinoma of breast [7 (21.87%)] and Respiratory tract infections

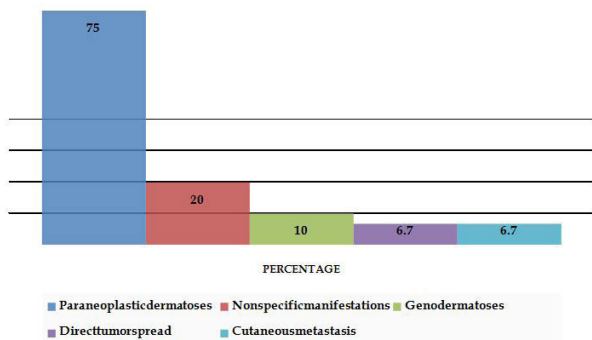
[5 (15.62%)]. There were 4 (12.5%), 3 (9.37%), 2 (6.25%) and 2 (6.25%) females who had head & neck cancer, gastrointestinal tract malignancies, CML and hodgkin's lymphoma respectively. (Graph 2)

**Graph 2:** Descriptive analysis of carcinoma in the female population (n=32)



In present study most common cutaneous marker was paraneoplastic dermatoses which was reported in 45 (75%) patients. Second most common cutaneous marker was nonspecific manifestations which were seen in 12 (20%) patients. Genodermatoses [6 (10%)], direct tumor spread [4 (6.7%)] and cutaneous metastasis [4 (6.7%)] were the 3<sup>rd</sup> and 4<sup>th</sup> most common cutaneous markers reported in present study. In present study some of the subjects presented with multiple markers. (Graph 3)

**Graph 3:** Descriptive analysis of cutaneous markers in the study population (n=60)

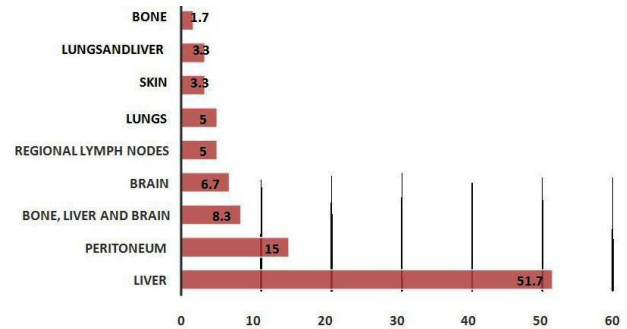


Majority of patients were the one receiving chemotherapy [46 (76.7%)] out of 60 patients with internal malignancies. Most common chemotherapeutic agents used in present study was 5- Fluorouracil [56 (93.3%)] followed by cisplatin [34 (56.7%)], oxaliplatin [32 (53.3%)], carboplatin [28 (46.7%)], epirubicin [26 (43.3%)], doxorubicin [23 (38.3%)], docetaxel [20 (33.3%)], cyclophosphamide [19 (31.7%)] and paclitaxel [17 (28.3%)]. Other least common chemotherapeutic agents were capecitabine [11 (18.3%)], sorafenib [5 (8.33%)], bleomycin [2 (3.3%)] and vincristine [2 (3.3%)].

In our study it was found that most common organ involved was liver [31 (51.7%) alone, however, in 5

(8.3%) patients had brain and bone affected along with the liver whereas 2 patients (3.3%) had liver and lung affected with malignancy. Other Second most common organ affected was Peritoneum [9 (15%)] followed by Brain [4 (6.7%)]. Least common affected organs were lungs [3 (5%)], Regional lymph nodes [3 (5%)], skin [2 (3.3%) and bone [1 (1.7%)].

**Graph 4:** Showing different organ involved



**Discussion**

Skin often mirrors changes in the internal milieu. The single most basic biologic process that characterizes a malignant tumor is the ability to produce secondary deposits (metastases) at distant sites. The skin is an infrequent site for metastasis. But malignancies which affect internal organs may display cutaneous manifestations and may also be the presenting symptom or sign of underlying malignancy. Cutaneous metastasis from an internal malignancy is usually rare and may be an indication of disease at the later stage<sup>12</sup>. In present retrospective and prospective study 60 confirmed cases of internal malignancy with skin manifestations were evaluated. Data regarding skin manifestation and malignancies were recorded from duration January 2017 to December 2019. In this duration a total 6620 patients were registered. On follow up 60 case of either sex were included as per the inclusion and exclusion criteria.

Skin is a rare site for metastases even though it is the largest organ of the human body<sup>13,14</sup>. The prevalence of cutaneous manifestation in present study was 0.91%.

In a study by Hassan et al the findings were consistent with our study, in it only two patients with cutaneous metastases (0.8%) were seen out of 250 population<sup>15</sup>.

Majority of the patients in our study were in the age group of >60 years of age [21 (35%)] followed by 21-30 years [12 (20%)] and 41-50 years [10 (16.7%)]. There were patients who had age between 51-60 years [7 (11.6%)] and 31-40 years [6 (10%)]. Four (6.7%) patients were very young (≤20 years).

This highlight that majority of the patients with skin manifestation were old having age >60 years highlighting the higher prevalence in this age group. In agreement to present study findings more than 50% of female patients belonged to the group of 50-60 years in the study performed by Rajagopal et al<sup>16</sup>.

Most common carcinoma in male was respiratory tract malignancies [9 (32.14%)] followed by gastrointestinal tract malignancies [7 (25%)] and head & neck cancer [6 (21.42%)]. Out of 28 males, 2 (7.14%) patients each had lymphomas, leukaemia and reproduction tract infections respectively. Increased incidence of carcinoma lung in males in our study may be due to the widely prevailing smoking habits. Majority of the females had reproductive tract malignancies [9 (28.12%)] followed by carcinoma of breast [7 (21.87%)] and Respiratory tract infections [5 (15.62%)]. There were 4 (12.5%), 3 (9.37%), 2 (6.25%) and 2 (6.25%) females who had head & neck cancer, gastrointestinal tract malignancies, CML and hodgkin's lymphoma respectively. Which means most common malignancy in female population were reproductive tract malignancies. The higher rate of reproductive tract malignancies in our study might be due to the early age at marriage and parity of the females in this part of the country. In line with present study findings Kilaru et al also found that majority of the females had reproductive tract malignancies which accounted for 20% of all carcinomas<sup>17</sup>. Fitz et al reported that carcinoma breast was the commonest neoplasm causing direct extension to the skin which also corroborates with the literature followed by carcinoma buccal mucosa and amelanotic melanoma<sup>18</sup>. In India, the five most common cancers in both sexes were cancers of the breast (14.3%), cervix uteri (12.1%), head and neck (7.6%), lung (6.9%) and colorectum (6.3%), comprising 47.2% of the 28 cancers reported<sup>19</sup>. Most common cutaneous marker was paraneoplastic dermatoses which were reported in 45 (75%) patients. Second most common cutaneous marker was nonspecific manifestations which were seen in 12 (20%) patients. Genodermatoses [6 (10%)], direct tumor spread [4 (6.7%)] and cutaneous metastasis [4 (6.7%)] were the 3<sup>rd</sup> and 4<sup>th</sup> most common cutaneous markers reported in present study. All malignancies lead to cutaneous manifestations through immunological, metabolic and metastatic consequences. These manifestations can be either specific malignant infiltrates or non-specific lesions. Specific infiltrates that show characteristic malignant cells on histopathological examination can occur due to contiguous or non-

contiguous spread. Non-specific lesions can be due to infections, non-infective conditions and changes due to chemotherapy.

In present study most common cutaneous manifestation was Generalized pruritus present in 15 (25%) followed by Infections [11 (18.3%)] and Seborrheic keratosis [9 (15%)]. Generalized pruritus was observed in various neoplasms like acute myeloid leukaemia, Hodgkin's lymphoma, non-Hodgkin's lymphoma, hepatocellular carcinoma, carcinoma of the gallbladder, cutaneous T cell lymphoma, lung carcinoma, carcinoma urinary bladder, carcinoma cervix and carcinoma ovary. In line with present study a study by Kilaru et al also reported generalized pruritus as the major presenting cutaneous manifestation accounting for 22% of the subjects.

In a study by Kilic et al reported that generalized pruritus was associated with hematological malignancies and also reported generalized pruritus to be the most frequent manifestation<sup>20</sup>. Similar to our study, Ayyamperumal et al reported pruritus associated with hepatocellular carcinoma, polycythemia vera, and carcinoma stomach while Rajagopal et al reported pruritus with Hodgkin's lymphoma and Non-Hodgkin's lymphoma<sup>12,16</sup>. In present study 18.3% had seborrheic keratosis in line with that Kilaru et al also reported seborrheic keratosis as the second most common cutaneous manifestations which was revealed in 16% of the patients<sup>17</sup>. In present study most common cutaneous manifestation was Generalized pruritus present in 15 (25%) followed by Infections [11 (18.3%)] and Seborrheic keratosis [9 (15%)]. Generalized pruritus was observed in various neoplasms like acute myeloid leukaemia, Hodgkin's lymphoma, non-Hodgkin's lymphoma, hepatocellular carcinoma, carcinoma of the gallbladder, cutaneous T cell lymphoma, lung carcinoma, carcinoma urinary bladder, carcinoma cervix and carcinoma ovary. In line with present study a study by Kilaru et al also reported generalized pruritus as the major presenting cutaneous manifestation accounting for 22% of the subjects.

In present study 18.3% had seborrheic keratosis in line with that Kilaru et al also reported seborrheic keratosis as the second most common cutaneous manifestations which was revealed in 16% of the patients<sup>17</sup>. Seborrheic keratoses are extremely common in normal population also. It was found that most common organ involved was liver [31 (51.7%)] alone, however, in 5 (8.3%) patients had brain and bone affected along with the liver whereas 2 patients (3.3%) had liver and lung affected with malignancy. Other Second most common organ

affected was Peritoneum [9 (15%)] followed by Brain [4 (6.7%)]. Least common affected organs were lungs [3 (5%)], Regional lymph nodes [3 (5%)], skin [2 (3.3%) and bone [1 (1.7%)]. According to the previous literature, the most common all malignancies to give rise to cutaneous metastases are carcinomas of the lung and colon in males and carcinoma of the colon and ovary in females. Overall, melanomas are the commonest followed by carcinoma breast, carcinomas of oral cavity, lungs, colon and ovary 18. Skin involvement in cancer patients may be biologically unrelated to the tumor occasionally, and instead may only be a part of a well-defined inherited syndrome featuring an increased incidence of internal cancer. There is need of a range randomized clinical trial to provide strength to present study findings.

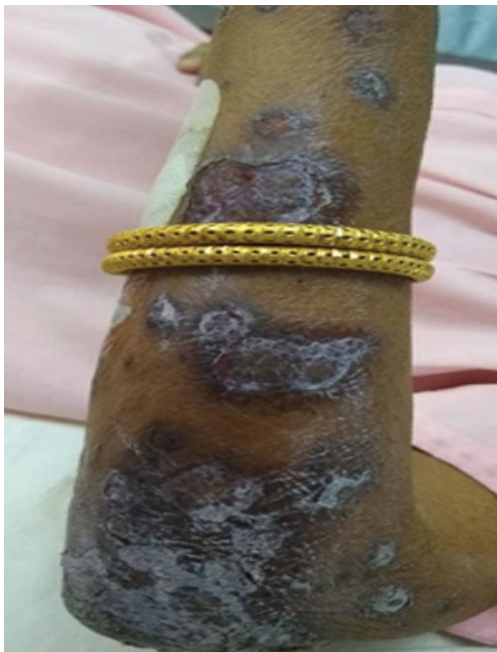

Fig. 1: Patient showing Methotrexate poisoning psoriasis

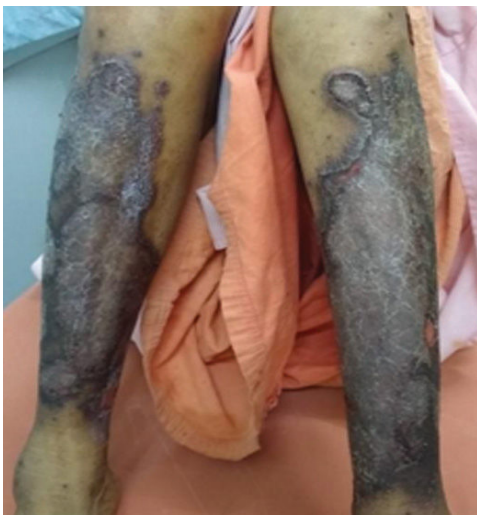

Fig. 2: Patient showing Methotrexate poisoning psoriasis

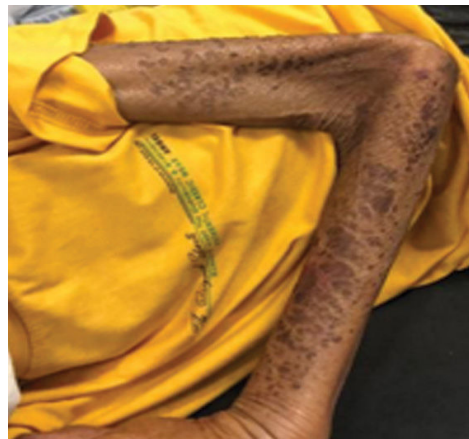

Fig. 3: Patient showing Acquired eczema

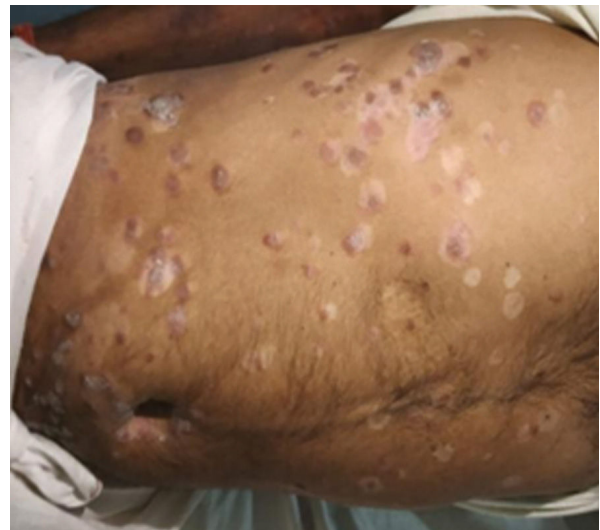

Fig. 4: Patient showing Halo phenomena

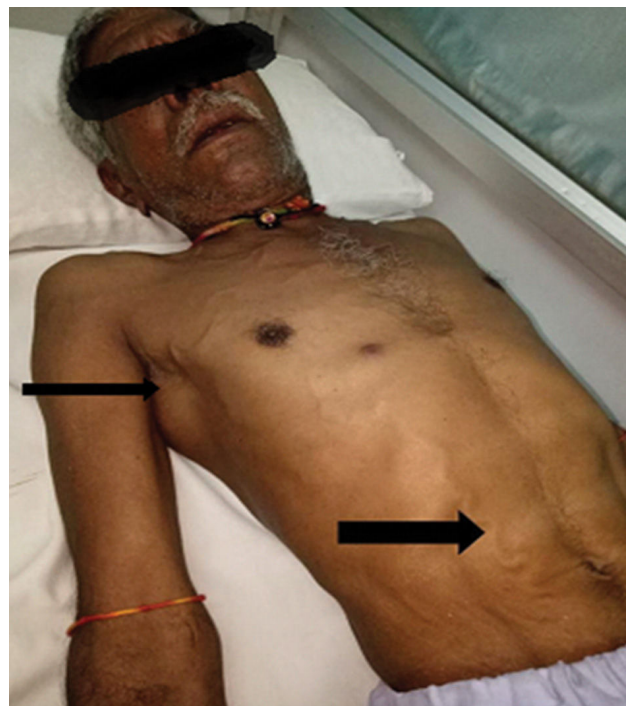

Fig. 5: Patient showing Mondor sign

## Conclusion

Based on the present study it can be concluded that skin is an infrequent site of metastasis and skin that is damaged allows for the malignant cells to lodge and proliferate locally. Sometimes, cutaneous metastasis may be the only presenting feature. The type of histological pattern seen can be a clue to the organ of origin giving rise to the cutaneous metastasis. Hence lesions that do not fit into any disease specifically should be biopsied for histological confirmation and the probability of an underlying malignancy should be kept in mind. Whatever the association, inspection of the skin remains an essential part of the complete physical examination and may also be useful for monitoring the activity and response to treatment of malignant disease.

## Limitations

Present study is not devoid of the limitation. The follow up period of the present study was shorter for a full evaluation and follow up. Present study was a descriptive study and hence the causality or temporal association could not be proved. Skin involvement in cancer patients may be biologically unrelated to the tumor occasionally, and instead may only be a part of a well-defined inherited syndrome featuring an increased incidence of internal cancer. There is need of a range randomized clinical trial to provide strength to present study findings

## References

1. Poole S, Fenske NA. Cutaneous markers of internal malignancy. II. Paraneoplastic dermatoses and environmental carcinogens [comment]. *J Am Acad Dermatol* 1993;28:147-64
2. Curth HO. Skin lesions and internal carcinoma. In: Andrade R, editor. *Cancer of the Skin: Biology, Diagnosis, Management*. Philadelphia: Saunders; 1976.
3. Robinson ND, Hashimoto T, Amagai M, Chan LS. The new pemphigus variants [comment]. *J Am Acad Dermatol* 1999; 40:649-71; quiz 672-3
4. Chopra R, Chhabra S, Samra SG, Thami GP, Punia RP, Mohan H. Cutaneous metastases of internal malignancies: A clinicopathologic study. *Indian J Dermatol Venereol Leprol* 2010;76:125-31.
5. Hildenbrand C, Burgdorf WH, Lautenschlager S. Cowden syndrome-diagnostic skin signs [review]. *Dermatology*. 2001;202: 362-366.
6. Cohen PR, Kurzrock R. Mucocutaneous paraneoplastic syndromes. *Semin Oncol* 1997;24:334-59.
7. Nair PS, Nanda KG, Jayapalan S. The "sign of groove", a new cutaneous sign of internal malignancy. *Indian J Dermatol Venereol Leprol* 2007;73:141.
8. Rosen T. Cutaneous metastases. *Med Clin North Am* 1980;64:885-900.
9. Shoup M, Brennan MF, Karpeh MS, Gillern SM, McMahon RL, Conlon KC. Port site metastasis after diagnostic laparoscopy for upper gastrointestinal tract malignancies: An uncommon entity. *Ann Surg Oncol* 2002;9:632-6.
10. Hildenbrand C, Burgdorf WH, Lautenschlager S. Cowden syndrome-diagnostic skin signs [review]. *Dermatology*. 2001;202: 362-366.
11. Bruce H. Thiers, Rachel E. Sahn, Jeffrey P. Callen. Cutaneous Manifestations of Internal Malignancy. *CA Cancer J Clin* 2009;59:73-98.
12. Ayyamperumal A, Tharini G, Ravindran V, Parveen B. Cutaneous manifestations of internal malignancy. *Indian J Dermatol*. 2012;57(4):260-4.
13. Brenner S, Tamir E, Maharshak N, Shapira J. Cutaneous manifestations of internal malignancies. *Clin Dermatol* 2001;19:290 7.
14. Lookingbill DP, Spangler N, Sexton FM. Skin involvement as the presenting sign of internal carcinoma. A retrospective study of 7316 cancer patients. *J Am Acad Dermatol* 1990;22:19 26
15. Hassan I, Zeerak S, Kuchay S, Bashir S, Bhat YJ, Mubashir S, et al. Cutaneous changes in internal malignancy: Study from a tertiary care center. *Indian J Dermatol Venereol Leprol* 2017;83:276.
16. Rajagopal R, Arora PN, Ramasastry CV, Kar PK. Skin changes in internal malignancy. *Indian J Dermatol Venereol Leprol* 2004;70: 221-5.
17. Kilaru KR, Kaja K, Garimella VR. Cutaneous manifestations of underlying malignancies presenting to a tertiary care teaching hospital. *Int J Res Dermatol* 2019;5:57-62.
18. Fitz Patrick's *Dermatology in General Medicine*, sixth edition, Vol.2, p1783-1796, 2003
19. Saranath D, Khanna A. Current status of cancer burden: Global and Indian scenario. *Biomed Res J* 2014;1:1 5.
20. Kilic A, Gul U, Soylu S. Skin findings in internal malignant diseases. *Int J Dermatol*. 2007;46(10):1055-60.