

# Assessment of Serum Chemerin in Oral Submucous Fibrosis with and without Associated Oral Squamous Cell Carcinoma and Oral Squamous Cell Carcinoma

Madhura Andhale<sup>1</sup>, Jyoti D. Bhavtankar<sup>2</sup>, Mandakini S. Mandale<sup>3</sup>, Jayanti Humbe<sup>4</sup>,  
Vaishali Nandhedkar<sup>5</sup>, Savita Dhage<sup>6</sup>, Riya Jain<sup>7</sup>

## How to cite this article:

Madhura Andhale, Jyoti D. Bhavtankar, Mandakini S. Mandale et al./Assessment of Serum Chemerin in Oral Submucous Fibrosis with and without Associated Oral Squamous Cell Carcinoma and Oral Squamous Cell Carcinoma/Indian J Dent Educ. 2023;16(1):17-22.

## Abstract

Oral cancer may arise de-novo or may be preceded by Oral Potentially Malignant Disorders (OPMDs). Chemerin is multifunctional adipokine with important role in regulating angiogenesis, cell proliferation and inflammation. Chemerin expression could be helpful for evaluating the progressive risk of OPMDs like OSMF and also help in evaluating prognosis of OSCC. In the present study total 80 subjects were assessed for serum chemerin levels. Among these 20 were healthy controls and 20 cases each of OSMF, OSMF associated OSCC and OSCC. The values of serum chemerin were compared between controls and cases and also amongst the clinical stages of the study groups. Our study demonstrated a progressively statistically significant increase in mean serum chemerin levels in OSMF cases, OSMF associated OSCC cases and OSCC cases than the controls. Thus serum chemerin level can be used as an adjunctive serum biomarker for predicting the malignant potential of OSMF and diagnosis of OSMF associated OSCC and OSCC.

**Keywords:** Serum Chemerin; Oral Submucous Fibrosis; Oral Squamous Cell Carcinoma.

## Introduction

Oral Squamous Cell Carcinoma (OSCC) ranks 11<sup>th</sup> as the common most malignancy in the world. A shift in the trend towards more oral cancer cases in the young population has been noted over the

past decade.<sup>1</sup> OSCC is preceded by clinical lesions known as Oral Potentially Malignant disorders (OPMDs). This makes the pathogenesis of OSCC more complex than malignancies in other parts of the body.<sup>2</sup> The common OPMDs with high malignant transformation rates are leukoplakia (0.13-34%) erythroplakia (14-50%) and Oral Submucous Fibrosis (OSMF) (3-19%).<sup>3</sup>

OSMF is an insidious, chronic, complex, crippling, debilitating, irreversible, progressive, scarring, potentially malignant and collagen metabolic disorder, induced by a known carcinogen areca nut.<sup>4</sup> The malignant potential of OSMF was first described by Paymaster in 1956. Various theories of OSMF transforming into malignancy include hypoxia, areca nut as a carcinogen, or epithelial-

**Author's Affiliation:** <sup>1,5-7</sup>Assistant professor, <sup>2</sup>Professor and HOD, <sup>3,4</sup>Associate professor, Department of Oral Pathology, Government Dental College and Hospital, Nagpur, Maharashtra 440003, India.

**Corresponding Author:** Riya Jain, Assistant professor, Department of Oral Pathology, Government Dental College and Hospital, Nagpur, Maharashtra 440003, India.

E-mail: [riyasjain25@gmail.com](mailto:riyasjain25@gmail.com)

Received on: 13-01-2023

Accepted on: 12-02-2023



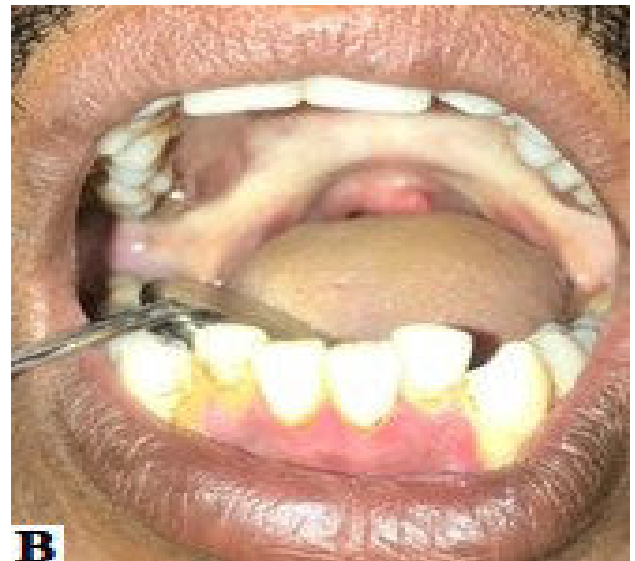## Introduction

Oral Squamous Cell Carcinoma (OSCC) ranks 11<sup>th</sup> as the common most malignancy in the world. A shift in the trend towards more oral cancer cases in the young population has been noted over the past decade.<sup>1</sup> OSCC is preceded by clinical lesions known as Oral Potentially Malignant disorders (OPMDs). This makes the pathogenesis of OSCC more complex than malignancies in other parts of the body.<sup>2</sup> The common OPMDs with high malignant transformation rates are leukoplakia (0.13-34%) erythroplakia (14-50%) and Oral Submucous Fibrosis (OSMF) (3-19%).<sup>3</sup>

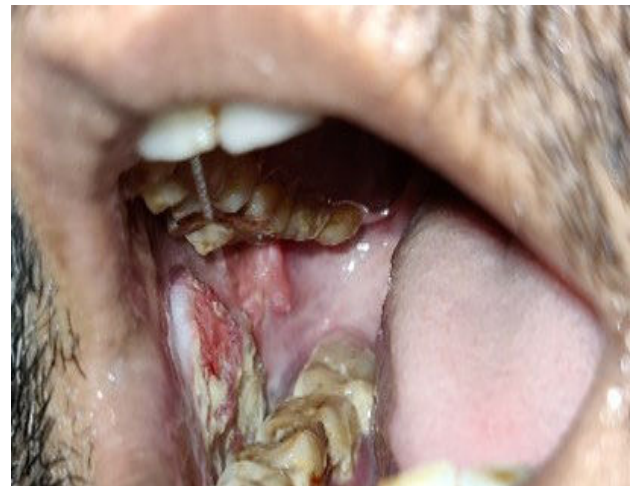OSMF is an insidious, chronic, complex, crippling, debilitating, irreversible, progressive, scarring, potentially malignant and collagen metabolic disorder, induced by a known carcinogen areca nut.<sup>4</sup> The malignant potential of OSMF was first described by Paymaster in 1956. Various theories of OSMF transforming into malignancy include hypoxia, areca nut as a carcinogen, or epithelial-mesenchymal transitions.<sup>5</sup>

Current demographic trends show a steady rise in the incidence of OSMF undergoing malignant transformation. Thus, prompting clinicians and scientists to understand the underlying molecular interactions mediating these catastrophic changes.<sup>6,7</sup>

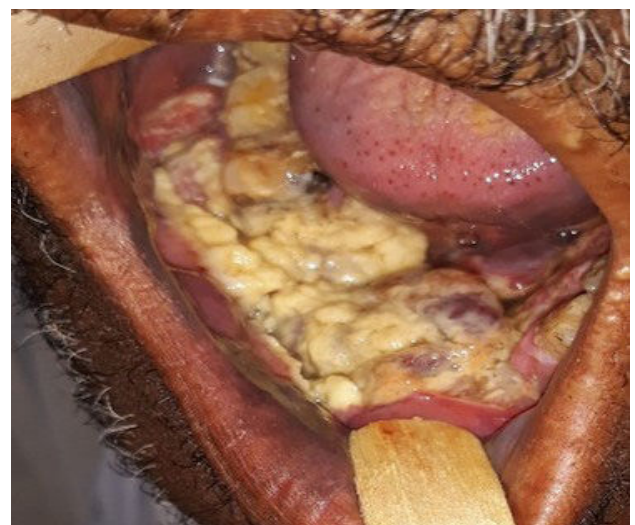
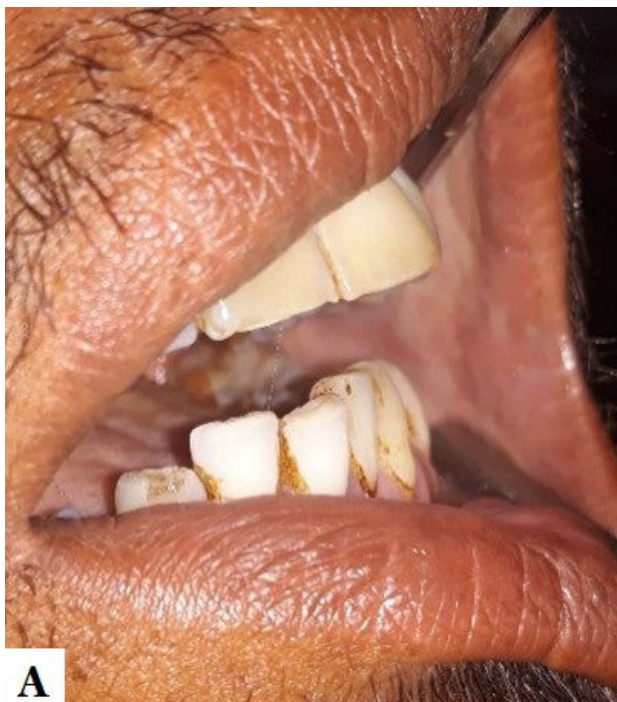Inflammation is considered as the 7<sup>th</sup> hallmark of cancer. Recent studies have unfolded the molecular pathways involving cancer and inflammation. With evolution in the field of biomarkers, use of



**Fig. 1A:** Case of OSMF with reduced mouth opening and blanched buccal mucosa, **Fig. 1B:** Case of OSMF showing hockey stick shaped uvula



**Fig. 2:** Case of OSMF with OSCC



**Fig. 3:** Case of OSCC

inflammatory biomarkers like or like IL-6, IL-8, TNF $\alpha$ , CXCL13 have become commonplace in carcinogenesis research.<sup>8</sup> Chemerin expression is associated with enhanced production of pro-inflammatory cytokines like IL-1beta, TNF $\alpha$ , IL-6, IL-8.<sup>9</sup>

Chemerin is multifunctional adipokine with important role in regulating angiogenesis, cell proliferation and inflammation with an overexpression in a number of malignancies.<sup>10</sup> Hence the study of chemerin levels in OSMF, OSMF with associated OSCC and OSCC may help in understanding its malignant transformation as well as in their prognostication.

### Material and methods

This was a case control study with study groups comprising of 20 healthy individuals, 20 patients with oral sub mucous fibrosis (Fig. 1), 20 Patients of OSMF with OSCC (Fig. 2) and 20 patients with oral squamous cell carcinoma (Fig. 3).

#### Inclusion criteria:

- Healthy individuals.
- Patients with oral submucous fibrosis.
- Cases of OSCC with clinical manifestations of OSMF.
- Patients with oral squamous cell carcinoma.

#### Exclusion criteria:

- Patients with any other soft tissue or bony lesion.
- Patients with any other systemic disease.

Under all aseptic precautions, 5 ml of venous blood was drawn from the cubital fossa and was allowed to clot at room temperature. It was then centrifuged at 3000 rpm for 10 minutes. The separated serum was stored at -20°C for estimation of chemerin by ELISA method.

The microtitre plate provided in the kit is pre-coated with polyclonal anti-human chemerin antibody. Samples are added to the appropriate microtiter plate wells. After 60 min incubation followed by washing, biotin label led polyclonal antihuman chemerin antibody is added and incubated with the captured chemerin for 60 min. After another washing streptavidin-HRP conjugate is added. After 30 min incubation and the last washing step the remaining conjugate reaction is stopped by addition of acidic solution and absorbance of the resulting yellow product is measured. The absorbance is proportional to the concentration of chemerin A standard curve is constructed. The concentration of samples is then determined by comparing the optical density (OD) of the samples to the standard curve in the ELISA reader. In order to make the calculation easier, the OD value of the chemerin (x-axis) against the known concentration of the standard (Y-axis) was calculated. The serum chemerin value is obtained in pg/ml by the ELISA reader. The data on demographic parameters like age, gender,

**Table 1:** Comparison of mean serum chemerin levels in various clinical stages of OSMF, OSMF associated OSCC and OSCC cases

Groups	Stage 1	Stage 1	Stage 2	Stage 2	Stage 3	Stage 3	Stage 4
	N (%)	Mean serum chemerin levels (pg/ml)	N (%)	Mean serum chemerin levels (pg/ml)	N (%)	Mean serum chemerin levels (pg/ml)	
Group 2 (OSMF)	3 (15%)	0.476	13 (65%)	0.539±0.134	4(20%)	0.554±0.124	-
Group 3 (OSMF associated OSCC)	2 (10%)	0.678±0.22	12 (60%)	0.824	6(30%)	0.829	-
Group 4 (OSCC)	3 (15%)	1.104	16 (80%)	1.31	1 (5%)	1.396	-

Two way ANOVA Statistically significant

(F value between rows = 7.0953; between columns = 8.0056; P value between rows = 0.0002; between columns = 0.04)

anatomical site, oral habits, clinical staging was obtained and was subjected to statistical analysis.

Descriptive statistics like frequency and percentage of subjects as per groups has been



depicted. Intergroup comparison was done using one-way ANOVA.

**Observation & Results**

A total of 80 samples categorized in four groups were included in the present study. Group I consisted of 20 healthy individuals, Group II consisted of 20 OSMF patients, Group III consisted

Group	N	Minimum serum chemerin pg/ml	Maximum serum chemerin pg/ml	Mean serum chemerin pg/ml
Group 1 (controls)	20 (25%)	0.021	0.699	0.36(±0.210)
Group 2 (OSMF)	20 (25%)	0.589	0.976	0.78(±0.100)
Group 3 (OSMF associated OSCC)	20 (25%)	0.132	1.43	0.78(±0.231)
Group 4 (OSCC)	20 (25%)	1.23	1.396	1.31 (±0.032)

(*p*<0.001)(One way ANOVA test) Statistically significant

of 20 cases of OSCC and Group IV consisted of OSCC with OSMF. From all the subjects 5ml blood was collected, centrifuged and serum was separated. Serum chemerin was estimated using ELISA.

The OSMF patients mainly belonged to the 3rd decade, OSMF associated with OSCC in 6th decade and OSCC cases also belonged in the 6th decade. (Table 1)

In all three study groups, male predominance was observed. In Group I & Group II, buccal mucosa was the most common site and in Group III, Tongue was the most common site. Group II vases had habit of areca nut chewing, Group II & III had habit of tobacco chewing.

In present study mean serum chemerin levels in controls, OSMF, OSMF associated OSCC and OSCC cases were 0.36±0.210pg/ml, 0.78±0.100pg/ml, 78±0.231pg/ml and 1.31±0.032pg/ml respectively. There was high statistically significant difference amongst the groups.(Table. 2)

**Discussion**

Approximately 40500 cases of oral cancer are

detected worldwide every year. OSCC still remains to be the most common reason for morbidity and mortality in these patients.<sup>11</sup> OPMDs comprise of various pathologies that arise in the oral cavity. Early detection and prompt treatment can prevent the progression of OPMDs to Oral cancer. Most common OPMDs are leukoplakia, erythroplakia, lichen planus, Oral Submucous Fibrosis, etc.<sup>12</sup> OSMF is an outcome of arecanut chewing and is characterized by fibroelastic changes in lamina propria and juxta inflammatopry reaction. Hypoxia caused in OSMF results in upregulation of VEGF which leads to angiogenesis which plays a pivotal role in malignant transformation of OSMF.<sup>13</sup>

Derranged angiogenesis is an important hallmark of cancer. VEGF, TGF, PDGF are well known angiogenic factors.<sup>14</sup> Chemerin is one such key angiogenic molecule and cascades like mitogen activated protein kinase (MAPK).<sup>15</sup>

Chemerin in oral premalignant lesions can be a marker for progression to malignancy. It has a role in malignancy as a diagnostic marker and also predicting progression. Chemerin levels were found to be strongly associated with single nucleotide polymorphism in EIDL3 gene which has known role in angiogenesis. Chemerin modulates chemotaxis and activation of macrophages, dendritic and natural killer cells to the site of inflammation. Chemerin is multifunctional adipokine with important role in regulating angiogenesis, cell proliferation and inflammation.<sup>16-18</sup> The present study was aimed to compare serum chemerin levels in OSMF, OSMF associated with OSCC and OSCC cases with the normal healthy subjects as controls.

The study comprised of 20 healthy individuals which acted as control and Group I: 20 patients with oral sub mucous fibrosis, Group II: 20 Patients of OSMF with OSCC and Group III: 20 patients with oral squamous cell carcinoma.

All groups were evaluated for serum chemerin levels using ELISA and found progressive increase from controls (0.36 ± 0.210pg/ml) to OSMF (0.78 ± 0.1pg/ml) to OSMF associated with OSCC (0.78 ± 0.232pg/ml) to OSCC (1.31± 0.032pg/ml) with statistically significant difference in the groups. Our results were in consensus with Wang et al. who found increased chemerin levels in tongue SCC tissues.<sup>19</sup> In another study by Ghallab et al., salivary chemerin levels were elevated in OSCC cases than in OPMD cases and mentioned that chemerin serves as an early diagnostic marker for OPMD s NAD OSCC.<sup>20</sup>

In our study, a novel finding was that cehemrin

levels were compared with clinical stages of OSMF. It was found that chemerin levels were elevated with increasing clinical stages of OSMF.

Siriwardhana et al discussed that chemerin levels were found to be heritable in association of single nucleotide polymorphism in EIDL 3 which has a role in angiogenesis.<sup>21</sup>

In the present study, pairwise comparison of serum chemerin levels were done in various groups and was found to be statistically highly significant ( $p < 0.05$ ). (Table. 2)

The mean serum chemerin level was least in controls ( $0.360 \pm 0.210$ pg/ml) with a significant rise in OSMF cases ( $0.78 \pm 0.1$  pg/ml) followed by OSMF associated with OSCC cases ( $0.78 \pm 0.231$ ) and OSCC cases ( $1.31 \pm 0.032$ pg/ml) respectively. This statistically significant rise in serum chemerin levels in OSMF cases to OSMF associated with OSCC and OSCC cases point towards the promising role of serum chemerin as a diagnostic and prognostic marker for OSMF, OSMF associated with OSCC and OSCC cases. It can be used as a tool for monitoring disease activity and outcome of treatment in OSMF as well as in OSCC cases.

Results of these studies have suggested that serum chemerin can have an important role during the malignant transformation of OSMF and may provide an indicator to early diagnosis and in the malignant progression of OSMF cases. Serum chemerin can also be correlated with associated phenotype in OSMF associated OSCC and OSCC cases.

The limitation to this study is that it did not have follow up and treatment outcomes. This leads to new research opportunities.

**Ethical Approval:** An ethical clearance was obtained from the Institutional Ethics Committee and Maharashtra University of Health and Sciences.

## References

- Ghantous Y, Elnaaj A. Global incidence and risk factors of oral cancer. Harefuah. 2017 Oct 1;156(10):645-9.
- Soares AB, Perschbacher K, Perez-Ordóñez B. Oral potentially malignant disorders. Diagnostic histopathology. 2018 May 1;24(5):161-5.
- Choudhari SK, Chaudhary M, Gadbail AR, Sharma A, Tekade S. Oxidative and antioxidative mechanisms in oral cancer and precancer: a review. Oral oncology. 2014 Jan 1;50(1):10-8.
- More CB, Rao NR. Proposed clinical definition for oral submucous fibrosis. Journal of oral biology and craniofacial research. 2019 Oct 1;9(4):311-4.
- Phulari RG, Dave EJ. A systematic review on the mechanisms of malignant transformation of oral submucous fibrosis. European Journal of Cancer Prevention. 2020 May 22;29(5):470-3.
- Chourasia NR, Borle RM, Vastani A. Concomitant association of oral submucous fibrosis and oral squamous cell carcinoma and incidence of malignant transformation of oral submucous fibrosis in a population of central India: A retrospective study. Journal of maxillofacial and oral surgery. 2015 Dec;14(4):902-6.
- Ray JG, Ranganathan K, Chattopadhyay A. Malignant transformation of oral submucous fibrosis: Overview of histopathological aspects. Oral surgery, oral medicine, oral pathology and oral radiology. 2016 Aug 1;122(2):200-9.
- Grivennikov SI, Karin M. Inflammatory cytokines in cancer: tumour necrosis factor and interleukin 6 take the stage. Annals of the rheumatic diseases. 2011 Mar 1;70(Suppl 1):i104-8.
- Fatima SS, Rehman R, Baig M, Khan TA. New roles of the multidimensional adipokine: chemerin. Peptides. 2014 Dec 1;62:15-20.
- Wang N, Wang QJ, Feng YY, Shang W, Cai M. Overexpression of chemerin was associated with tumor angiogenesis and poor clinical outcome in squamous cell carcinoma of the oral tongue. Clinical oral investigations. 2014 Apr;18(3):997-1004.
- Marsh D, Suchak K, Moutasim KA, Vallath S, Hopper C, Jerjes W, Upile T, Kalavrezos N, Violette SM, Weinreb PH, Chester KA. Stromal features are predictive of disease mortality in oral cancer patients. The Journal of pathology. 2011 Mar;223(4):470-81.
- Kansara S, Sivam S. Premalignant lesions of the oral mucosa.
- Zhou S, Li L, Jian X, Ou X, Jiang H, Yao Z, Xu C, Peng J. The phosphorylation of survivin Thr34 by p34cdc2 in carcinogenesis of oral submucous fibrosis. Oncology reports. 2008 Nov 1;20(5):1085-91.
- Fujimoto J, Sakaguchi H, Aoki I, Tamaya T. Clinical implications of expression of interleukin 8 related to angiogenesis in uterine cervical cancers. Cancer research. 2000 May 15;60(10):2632-5.
- Bozaoglu K, Curran JE, Stocker CJ, Zaibi MS, Segal D, Konstantopoulos N, Morrison S, Carless M, Dyer TD, Cole SA, Goring HH. Chemerin, a novel adipokine in the regulation of angiogenesis. The Journal of Clinical Endocrinology & Metabolism. 2010 May 1;95(5):2476-85.
- Nishida N, Yano H, Nishida T, Kamura T, Kojiro M. Angiogenesis in cancer. Vascular health and risk management. 2006 Sep;2(3):213.
- Kaur J, Adya R, Tan BK, Chen J, Randeve HS. Identification of chemerin receptor (ChemR23)

- 22 Madhura Andhale, Jyoti D. Bhavtankar, Mandakini S. Mandale et al./Assessment of Serum Chemerin in Oral Submucous Fibrosis with and without Associated Oral Squamous Cell Carcinoma and Oral Squamous Cell Carcinoma

in human endothelial cells: chemerin-induced endothelial angiogenesis. *Biochemical and biophysical research communications*. 2010 Jan 22;391(4):1762-8.

18. Ferland DJ, Watts SW. Chemerin: a comprehensive review elucidating the need for cardiovascular research. *Pharmacological research*. 2015 Sep 1;99:351-61.
19. Ekanayaka RP, Tilakaratne WM. Oral submucous fibrosis: Review on mechanisms of pathogenesis and malignant transformation. *J Carcinog Mutagen*. 2013.
20. Ghallab NA, Shaker OG. Serum and salivary levels of chemerin and MMP-9 in oral squamous cell carcinoma and oral premalignant lesions. *Clinical oral investigations*. 2017 Apr;21(3):937-47.
21. Reichart PA, Philipsen HP. Oral erythroplakia—a review. *Oral oncology*. 2005 Jul 1;41(6):551-61.

