

## Spectrum of Gastrointestinal Lesions in A Tertiary Care Hospital

Chethan Sagar S.<sup>1</sup>, Pradeep Kumar L.<sup>2</sup>, Ramesh Babu K.<sup>3</sup>

<sup>1</sup>Dept. of Pathology <sup>2</sup>Assistant Professor <sup>3</sup>Professor, Dept. of Pathology, Shivamogga Institute of Medical Sciences, Shimoga, Karnataka 577201, India.

### Abstract

*Introduction:* Cancer is the major health issue now days with a burden accounting for almost one in every four deaths. Gastrointestinal tract (GIT) is the most commonly involved system in the human body. Adenocarcinomas are more common among intestinal tumors. However benign tumors are more common than the malignant tumors. Gastrointestinal (GI) cancers constitutes 20% of estimated new carcinoma cases and about 15% of estimated death worldwide.

*Aim:* To study the histomorphology of various gastrointestinal lesions.

*Materials and methods:* It was a retrospective study for 4 years. All the biopsies submitted to Department of pathology, SIMS, Shivamogga for histological evaluation during the study period. Altogether 89 GI specimens were fixed in 10% formalin and processed in semi automatic tissue processor. Routine hematoxylin and eosin stain and special stains were done.

*Results:* Total number of cases were 11,000. Among which 89 cases (0.8%) were GIT specimens, both neoplastic and non-neoplastic. Neoplastic lesions constituted 45 cases (50.6%). Non neoplastic lesions constituted 44 cases (49.4%) which includes both inflammatory and non inflammatory lesions.

*Conclusion:* GI lesions constitutes about 0.8% of all the lesions. Most common neoplastic lesion of oesophagus was squamous cell carcinoma where as adenocarcinoma was most common gastric and intestinal neoplastic lesion.

**Keywords:** Squamous Cell Carcinoma; Gastrointestinal Lesions; Adenocarcinoma.

### Corresponding Author:

**Pradeep Kumar L**, Assistant Professor of Pathology, Shivamogga Institute of Medical Sciences, Shimoga, Karnataka 577201, India

E-mail: Pradeepnaik.l@gmail.com

Received on 16.01.2019,

Accepted on 04.02.2019

### How to cite this article:

Chethan Sagar S., Pradeep Kumar L., Ramesh Babu K. Spectrum of Gastrointestinal Lesions in A Tertiary Care Hospital. Indian J Pathol Res Pract. 2019;8(2):166-168.



## Introduction

Cancer is the major health issue now days with a burden accounting for almost one in every four deaths. 1 Gastrointestinal tract (GIT) is the most commonly involved system in the human body. Adenocarcinomas are more common among intestinal tumors. However benign tumors are more common than the malignant tumors. Gastrointestinal (GI) cancers constitutes 20% of estimated new carcinoma cases and about 15% of estimated death worldwide. 2345 Oesophageal cancer is the 8th most commonest malignant neoplasm in the world which is also a major cause of cancer related mortality. Carcinoma of esophagus accounts for 5.5% of all malignant tumors of the GI tract with a male preponderance [6].

### Aim

- To study the histomorphology of various gastrointestinal lesions.

## Materials and Methods

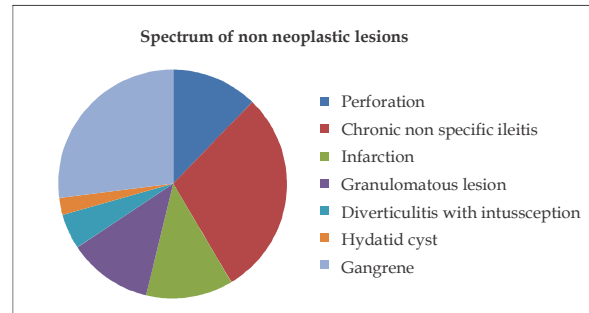
- Source of data:*  
All the biopsies submitted to Department of pathology, SIMS, Shivamogga for histological evaluation during the study period.  
Altogether 89 GI specimens were fixed in 10% Formalin and processed in semi automatic tissue processor. Routine Hematoxylin and Eosin stain and special stains were done.
- Study type:* Retrospective, descriptive study.
- Study period:* Jan 2014 to June 2017
- Study duration:* Four years

## Results

Total number of cases were 11,000. Among which 89 cases (0.8%) were GIT specimens, both neoplastic and non-neoplastic. Neoplastic lesions constituted 45 cases (50.6%). Malignant lesions includes 36 cases (80%) out of which 12 cases (33.4%), 17 cases (47.2%) and 7 cases (19.4%) were Oesophageal, gastric and intestinal lesions. Benign lesions include 2 cases (22.2) of carcinoid tumor, one case each of lipoma (2.6%), enteric cyst (2.6%) and neurofibroma (2.6%) 4 cases (8.8%) were classified as undeterminate lesions which includes 3 cases of dysplasia and one case of suspicious for malignancy .

**Table 1:** Distribution of gastrointestinal lesions according to location.

Location	Neoplastic	Non neoplastic
Oesophagus	16	-
Stomach	17	1
Intestine	12	43
Total= 89	45	44



**Fig. 1:** Spectrum of non neoplastic lesions

Non neoplastic lesions constituted 44 cases (49.4%) which includes both inflammatory and non inflammatory lesions. Inflammatory lesions include 11 cases (28.9%) of perforation, 10 cases (26.3%) of non specific ileocolitis, 5 cases (13.1%) of granulomatous lesion, 2 cases (5.2%) of diverticulitis with intussusception and one case (2.6%) of hydatid cyst. Non inflammatory lesions includes 5 cases (83.3%) of infarction and one case (16.7%) of crohn's disease.

All the cases of oesophagus were squamous cell carcinoma with few cases showing dysplastic changes. One case was reported as suspicious for malignancy and 3 cases as dysplasia.

Adenocarcinoma was the commonest amongst gastric lesions (16 cases) followed by a case of malignant gastrointestinal stromal tumors.

Adenocarcinoma was also the commonest malignant lesion in intestine constituting 7 cases. Benign lesions included one case each of lipoma, enteric cyst and neurofibroma. Non neoplastic lesions included perforation, non specific ileocolitis, granulomatous lesion, diverticulitis with intussusception, hadatid cyst, infarction and crohn's disease.

## Discussion

Among the total no of 11000 specimens received in our hospital during four year study period, 0.8% were gastrointestinal tract lesions.

Among the 16 cases in oesophagus majority 12 (75%) were diagnosed as squamous cell carcinoma which was in concordance with similar study done by d chhanda et al 6 and James M Crawford et al. Most common age group ranged from 35 to 80 years with a male preponderance.

Among the 17 cases in stomach majority were diagnosed as adenocarcinoma with one case of malignant gastrointestinal tumor. Stomach was the most common site among the malignancy followed by oesophagus and colon in our study where as James M Crawford et al. also had similar results with majority (95%) of cases diagnosed as adenocarcinoma. 7 Malignant gastrointestinal stromal tumor (GIST) constituted 5.9% of the gastric lesions in our study where as M. Miettinen found 2.2% malignant GIST. 8,9

Among the intestinal lesions non neoplastic lesions (43 cases) were more common than the neoplastic lesions (12 cases). Chronic non specific ileocolitis was the most common non neoplastic lesion where as adenocarcinoma was the commonest neoplastic lesion in our study which was in concordance with study done by Domizio P et al. [9] and Dr Chhanda Das et al. [6].

### Conclusion

GI lesions constitutes about 0.8% of all the lesions which includes various neoplastic and non neoplastic lesions. Most common lesion of oesophagus was squamous cell carcinoma where as most common neoplastic lesion in both stomach and intestine was adenocarcinoma. Overall benign lesions were more common than malignant lesions among GI lesions. But in our study it was viceversa probably because of limited availability of benign specimens.

*Source(s) of support:* SIMS, Shimoga

*Presentation at a meeting:* None

*Organisation:* SIMS, Shimoga

*Conflicting Interest (If present, give more details):*  
None

### References

1. László Herszényi, Zsolt Tulassay. European Review for Medical and Pharmacological Sciences. Epidemiology of gastrointestinal and liver tumors. 2010;14:249-58.
2. Jemal A, Siegel R, Ward E, Hao Y, Xu J, Thun Mj. Cancer statistics, 2009. CA Cancer J Clin. 2009;59:225-49.
3. Verdecchia A, Francisci S, Brenner H, Gatta G, Micheli A, Mangone L. et al. Eurocare-4 Working Group. Recent cancer survival in Europe: a 2000-02 period analysis of EURO-CARE-4 data. Lancet Oncol. 2007;8:784-96.
4. P, Quaglia A, Tavilla A, Shack L, Brenner H, Janssenheijnen M, Allemani C et al. Eurocare Working Group. The cancer survival gap between elderly and middle-aged patients in Europe is widening. Eur J Cancer. 2009;45:1006-16.
5. Francisci S, Capocaccia R, Grande E, Santaquilani M, Simonetti A, Allemani C. et al. Eurocare Working Group. The cure of cancer: a European perspective. Eur J Cancer. 2009;45:1067-79.
6. Dr Chhanda Das, Dr Namrata Maity, Dr Madhumita Mukhopadhyay, Dr Bedabrata Mukhopadhyay, Dr Keya Basu, Dr Madhukumari. Histopathological Spectrum of Gastrointestinal Tract Lesions In A Tertiary Care Hospital: An Epidemiological Study For Four Years. IOSR Journal of Dental and Medical sciences. 2016 Feb;15(2):74-7.
7. James M. Crawford MD, Ph.D. The gastrointestinal system. Ramji SC, Vinay K. and Stanley (eds). In Robins Pathologic Basis of Diseases. 5th ed. Banglore-India. W.B Saunders Company, 1944. pp. 755-829.
8. M. Miettinen, J.Y. Blay, H. Sabin. WHO. H.E. Gabbert, T. Shimoda et al. WHO Classification of Tumors. In: Pathology and Genetics of Tumors of the Digestive Systems. IARC Press, Lyon. 2000. pp 11-30.
9. Miettinen M, Lasota J. Gastrointestinal stromal tumors: review on morphology, molecular pathology, prognosis and differential diagnosis. Arch Pathol Lab Med. 2006;130:1466-78.