

## Anaesthetic Management of Gaucher Disease for Splenectomy

Dixsha T P<sup>1</sup>, S. Mohideen Abdul Kadar<sup>2</sup>, Aneesh Rajan<sup>3</sup>, Sasidharan Nair M<sup>4</sup>

### How to cite this article:

Dixsha T P, S. Mohideen Abdul Kadar, Aneesh Rajan *et al.* Anaesthetic Management of Gaucher Disease for Splenectomy. *Ind J Anesth Analg.* 2024; 11(3):165-167.

### Abstract

Gaucher's disease is the most common form of lysosomal storage disorder. It is caused by an inherited deficiency of beta glucocerebrosidase enzyme. It results in accumulation of beta glucocerebroside leading to end organ dysfunction. Gaucher disease is an autosomal recessive inheritance by mutations in the GBA gene on chromosome 1. It affects both sexes. The incidence is estimated to be 1:40000 in Europe. Most commonly, the disease is differentiated into a non-neuronopathic form and a neuronopathic form. Gaucher disease may present a challenge to the anesthesiologist because of abnormal coagulation and multi organ dysfunction. These factors may affect the choice of anaesthesia type. We aim to report the anaesthetic management in a 25 years old male with Gaucher's disease posted for splenectomy.

**Keywords:** Thrombocytopenia Anaemia; Hepatosplenomegaly.

## INTRODUCTION

Gaucher's disease is the most common form of lysosomal storage disorder. It is caused by an inherited deficiency of beta glucocerebrosidase enzyme.<sup>1</sup> It results in accumulation of glucocerebroside, leading to end organ dysfunction.<sup>2</sup> Gaucher disease is a familial disorder of lipid catabolism with autosomal recessive inheritance by mutations in the GBA gene on chromosome 1.

It affects both sexes. The incidence is estimated to be 1:40000 in Europe. This disease is classified into three broad phenotypes based on the presence or absence of neurological involvement and their severity.

### Type I-Non neuronopathic or adult or chronic form

Is the mildest and most common variant. Patients present with hepatomegaly cytopenia, irritability and failure to thrive. It affects 1 in 2500 in the Ashkenazi Jewish population, 1 in 50,000 to 1,00,000 in the general population.

### Type II-Acute neuropathic or infantile form

Is the rarest form and also lead to CNS involvement generally within the first year of life with seizure, developmental delay, opisthotonic posturing and feeding difficulties. Disease progresses very rapidly leading to death by two years of age.

### Type III-Subacute or juvenile or neuronopathic form

Relatively more common in India compared

**Author's Affiliation:** <sup>1</sup>Senior Resident, <sup>2-4</sup>Professor, Department of Anaesthesiology, Dr. Somervell Memorial CSI Medical College, Karakonam, Thiruvananthapuram 695504, Kerala, India.

**Corresponding Author:** Dixsha T P, Department of Anaesthesiology, Dr. Somervell Memorial CSI Medical College, Karakonam, Thiruvananthapuram 695504, Kerala, India.

**E-mail:** dixsha11@gmail.com

**Received on:** 08.04.2024

**Accepted on:** 27.09.2024



to western population. Involves neurological manifestations including oculomotor apraxia bulbar paresis strabismus saccade initiation abnormalities myoclonus and dementia. Multi organ involvement other than nervous system is common to all forms of Gaucher's disease.<sup>3</sup>

The diagnosis of Gaucher disease is suggested by the occurrence of the clinical signs and symptoms and confirmed by determination of enzyme activity.

## CASE REPORT

A 25-years-old male with a known case of Gaucher's disease scheduled for splenectomy. Gaucher's disease had been diagnosed 10 years back by bonemarrow aspiration cytology.

Physical examination of our patient revealed hepatosplenomegaly maelena. Neurological examination revealed developmental delay.

A thorough preanesthetic evaluation was done. Complete haemogram showed haemoglobin level of 10.1 g/dL total leukocyte count 2748 cells/mm<sup>3</sup> and platelet count 64000 cells/mm<sup>3</sup>. Patient was a known case of diabetes mellitus with HbA<sub>1c</sub>-7.1% on regular medication. The rest of parameters including renal function test liver function tests prothrombin time with INR activated partial thromboplastin time were within normal limits. Ultrasound abdomen revealed a massive splenomegaly with a size of 29 centimetres. Prior discussion with the blood bank was established to arrange for blood and blood products.

Endotracheal intubation with controlled ventilation was planned. Pre-operative central venous cannulation was done in view of difficult iv access.

Central venous cannulation was secured under ultrasound guidance using a7Fr triple lumen catheter in the right internal jugular vein. Patient was induced with midazolam 50microgram/kg iv fentanyl 2ug/kg iv propofol 2mg/kg and succinylcholine 2mg/kg. Intubation was done with a 8.0mm cuffed endotracheal tube. After intubation bilateral rectus sheath block was given for perioperative analgesia as neuraxial blockade was avoided because of thrombocytopenia.

Anaesthesia was maintained using oxygen nitrous oxide with sevoflurane and cis-atracurium as muscle relaxant. Transfusion was withheld till the step of splenic artery ligation as the transfused products would be subjected to sequestration as a result of hypersplenism. Packed red blood cells and single donor platelet was transfused

following splenic artery ligation. The patient was haemodynamically stable throughout the surgery. Operation lasted for 150 minutes. Residual paralysis was reversed with 2.5 mg neostigmine and 0.4 mg glycopyrrolate. Patient was extubated and shifted to surgical intensive care unit for further monitoring and management.

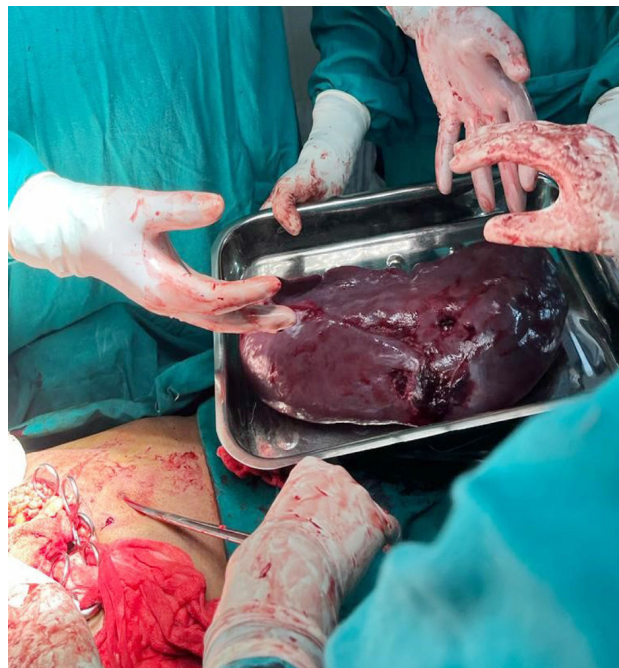


Fig. 1: Massive splenomegaly

## DISCUSSION

Gaucher's disease is still a challenge for anaesthesiologists due to multi organ involvement and coagulation abnormalities. The glycolipids are a major component of cell membrane structures. They are found in high concentrations in the CNS and haematopoietic elements.<sup>2</sup> The enzymatic defect in Gaucher disease involves one of the final steps in glycolipid catabolism, resulting in accumulation of glucosylceramide. Hepatosplenomegaly is the most common sign of visceral involvement. Splenomegaly will produce hypersplenism leading to thrombocytopenia anaemia and leucopenia.<sup>7</sup> The most common system involved is the nervous system due to progressive neurodegenerative diseases in Gaucher's type II and III. Major concern in patients with CNS dysfunction is bulbar paresis leading to aspiration and postoperative pulmonary dysfunction. Respiratory dysfunction may occur due to accumulation of abnormal glycolipids in pulmonary tissue which results in progressive respiratory failure and cor pulmonale. Cardiovascular and pulmonology evaluation

has to be done to rule out the pulmonary hypertension and infiltrative lung disease.<sup>4,5</sup> Preoperative evaluation is carried out to determine the extent of organ involvement the primary concern is of haematological status. Our patient had low platelet count the patosplenomegaly and developmental delay.

## CONCLUSION

Multi organ involvement and haematological abnormalities plays a major role in deciding the mode of anaesthesia. A multidisciplinary approach involving surgeon anaesthesiologist, pulmonologist, haematologist and intensivist is crucial in management of these patients.

**Conflict of Interest:** The authors declare no conflict of interest.

## REFERENCES

1. Praneeth R, Venkatraj K. Anaesthetic implications for splenectomy in a child with Gaucher's disease. *Indian J Clin Anaesth* 2021;8(4):608-610.
2. Tobias JD, Atwood R, Lowe S, Holcomb GW. Anesthetic considerations in the child with Gaucher disease. *J Clin Anesth*.1993;5:150-3.
3. Grabowski GA. Recent clinical progress in Gaucher disease. *Curr Opin Pediatr*. 2005;17(4):519-24.
4. Ioscovich A, Elstein Y, Halpern S, Vatashsky E, Grisaru-Granovsky S, Elstein D. Anesthesia for obstetric patients with Gaucher disease: survey and review. *Int J Obstet Anesth*. 2004;13:244-50.
5. Dell'oste C, Vicenti F. Anesthetic management of children with type II and III Gaucher disease. *Minerva Pediatr*. 1997;49:495-8.
6. Cano Ruiz A, Martin Scarpa A, Montescillo Francia A, Moreno Caparros A. Gaucher's disease type I. an infrequent cause of portal hypertension. *An Med Interna* 1998; 15: 483-4.
7. Gillis S, Hyam E, Abrahamov A, Elstein D, Zimran A. Platelet function abnormalities in Gaucher disease patients. *Am J Hematol* 1999;61: 103-6.
1. Praneeth R, Venkatraj K. Anaesthetic implications for splenectomy in a child with

