

## Original Research Article

## Evaluation of Spectrum of Histopathological Variants in BPH, PIN and Carcinoma Prostate: A Tertiary Care Centre Study

Rajendra Prasad H M<sup>1</sup>, Niranjana Murthy B<sup>2</sup>

<sup>1</sup>Assistant Professor, <sup>2</sup>Professor and Head, Department of Pathology, Sree Siddhartha Medical College, Tumkur, Karnataka 572107, India.

**Corresponding Author:**

**Rajendra Prasad H M**, Assistant Professor, Department of Pathology, Sree Siddhartha Medical College, Tumkur, Karnataka 572107, India.

**E-mail:** hodprasad7@gmail.com

**How to cite this article:**

Rajendra Prasad H M, Niranjana Murthy B. Evaluation of Spectrum of Histopathological Variants in BPH, PIN and Carcinoma Prostate: A Tertiary Care Centre Study. Indian J Pathol Res Pract 2020;9(2 Part II):159-164.

### Abstract

Benign prostatic hyperplasia (BPH) and adenocarcinoma are common diseases that account for considerable morbidity and mortality in the aging population. Prostatic intraepithelial neoplasia (PIN) refers to the preinvasive end of the continuum of cellular proliferations within the lining of the prostatic ducts, ductules and acini, with cytological changes mimicking cancer. Prostate cancer (PCa) is the most prevalent cancer found in men above the age of fifty years. Adenocarcinoma of the prostate range from well-differentiated gland forming cancers to poorly differentiated tumors.

*Aim:* To evaluate the histopathological variants of prostatic lesions in prostatectomy specimens.

*Materials and Methods:* A prospective study was done to evaluate the various histological lesions in prostate specimens received in our institution.

*Statistical Analysis Used:* The data collected was entered in MS Excel spreadsheet and analysed using SPSS version 20.

*Results:* Out of 90 prostate specimens studied, commonest pathology encountered was benign lesions constituting 94.5% and malignant lesions were 5.5%. Out of 84 cases of benign lesions, 51 cases (64.28%) were diagnosed as nodular hyperplasia only and NH was associated with 6 cases of basal cell hyperplasia (7.14%), 5 cases of squamous metaplasias (5.95%), 2 cases of transitional metaplasia (2.38%), and 20 cases (23.80%) of prostatitis. Diagnosis of prostatic carcinoma was made in 5 cases (5.5%).

*Conclusion:* Histologically, all the malignant lesions encountered were adenocarcinoma of prostate. The commonest pattern seen was acinar followed by arrangement of tumor cells in cords, sheets and cribriform pattern.

**Keywords:** Benign prostatic hyperplasia (BPH); Prostatic intraepithelial neoplasia (PIN); Prostatic adenocarcinoma.

### Introduction

Benign prostatic hyperplasia (BPH) is the most common neoplastic condition affecting men<sup>1</sup> and is an age related process with a histologic prevalence of approximately 10% for men in their 30s, 20%

for men in their 40s, 50% to 60% for men in their 60s, and 80% to 90% for men in their 70s and 80s. It is characterized histologically as a progressive enlargement of the prostate gland resulting from a non-malignant proliferative process that includes both epithelial and stromal elements.<sup>2</sup> Clinical



manifestations of BPH include the symptoms, signs and sequelae of urinary obstruction caused by the abnormal growth.<sup>3</sup>

Prostatic intraepithelial neoplasia (PIN) refers to the preinvasive end of the continuum of cellular proliferations within the lining of the prostatic ducts, ductules and acini, with cytological changes mimicking cancer.<sup>4</sup> PIN is currently subcategorized into two grades, low and high grade PIN. High grade PIN (HGPIN) co-exists with cancer in more than 85% of cases.<sup>5</sup>

Adenocarcinoma of the prostate range from well-differentiated gland forming cancers to poorly differentiated tumors.<sup>6</sup>

The present study is undertaken to study the histopathological features of hyperplasia of prostate, PIN and prostatic carcinoma

## Materials and Methods

The present study is a hospital based prospective study, undertaken in the department of pathology, Sri Siddhartha Medical College, Tumkur. This study was conducted on prostate specimens obtained from patients who underwent transurethral resection of prostate (TURP) and biopsy for enlargement of prostate attending the Department of Surgery and Urology, SSMCandH, Tumkur.

Brief clinical data noted from the case records, which included the age, presenting symptoms, DRE findings, serum PSA levels, USG findings and clinical diagnosis.

All types of prostatic specimens including TURP, biopsy and prostatectomy are considered in this study. All the prostatic specimens which were sent in 10% formalin are received, weighed and subjected to a careful detailed gross examination. After fixation, the tissues are given for processing. For the first 20g of tissue, four capsules are filled. If the specimen weighed more than 20g then one additional capsule is filled for each subsequent 10g. 4-6 $\mu$  thick sections were prepared from the paraffin embedded tissue sections and stained routinely with H and E stain.

All the sections were subjected to a detailed microscopic examination and the staining of the histological sections were done using standard procedures.

## Results

The present study deals with various histological evaluation of prostate tissue specimen. During the

period of present study, 90 prostatic specimens were analyzed in the Department of Pathology, Sri Siddhartha Medical College, Tumkur.

Out of 90 prostatic specimens received, 84 (94.5%) cases were benign lesions, one case was low grade intraepithelial neoplasia along with nodular hyperplasia, and prostatic malignancy (5.5%) was diagnosed in 5 cases. (Fig. 1)

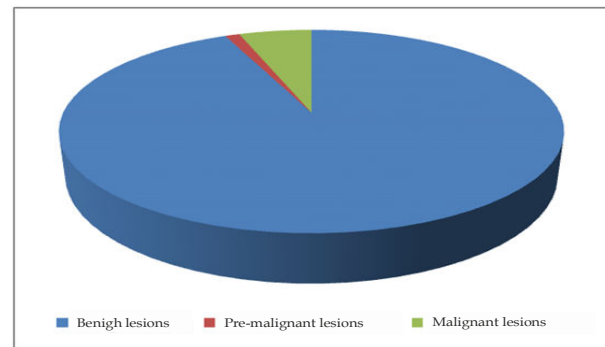


Fig. 1: Incidence of Prostatic Lesions.

## Age

Among 84 Benign lesions, majority of the cases were seen in 7<sup>th</sup> and 8<sup>th</sup> decade. One case was diagnosed as premalignant lesion and the age was 65 years. (Fig. 2)

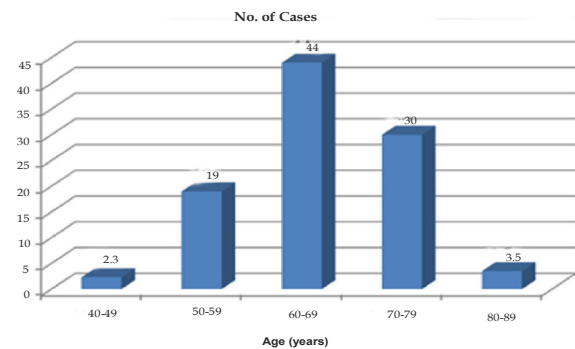


Fig. 2: Age Wise Distribution of Nh Patients.

## Clinical Features

The most common clinical symptoms of benign lesions were frequency in 70 patients, followed by hesitancy, nocturia, and retention of urine in 60, 55 and 10 patients respectively. Frequency was the predominant symptom in prostatic intraepithelial lesion. Malignant lesions had common symptoms of hesitancy in 4 cases followed by nocturia, frequency and the retention of urine in 3, 2, and 2 patients respectively.

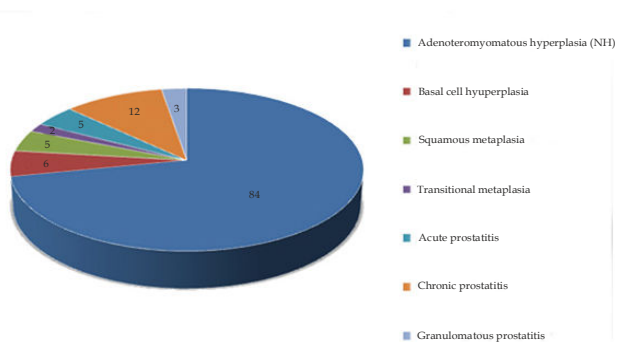
## Microscopic Features in Benign Lesions of Prostate

In the present study, all the 84 benign cases showed

prostatic hyperplasia. Among these 84 cases, other histological features were also seen. (Table 1, Fig. 3)

**Table 1:** Microscopic Findings in Benign Lesions.

No	Microscopic	No of cases
1.	Nodular hyperplasia (NH) only	51
2.	NH and Basal cell hyperplasia	06
3.	NH and Squamous Metaplasia	05
4.	NH and Transitional Metaplasia	02
5.	NS and Acute Prostatitis	05
6.	NS and Chronic Prostatitis	12
7.	NS and Granulomatous Prostatitis	03



**Fig. 3:** Microscopic Findings in Benign Lesions.

*Prostatic Intraepithelial Neoplasia*

NH was associated with low grade PIN in one case, which shows epithelial crowding and stratification, the nuclei were enlarged with anisonucleosis and nuclear chromatin was apparently normal.

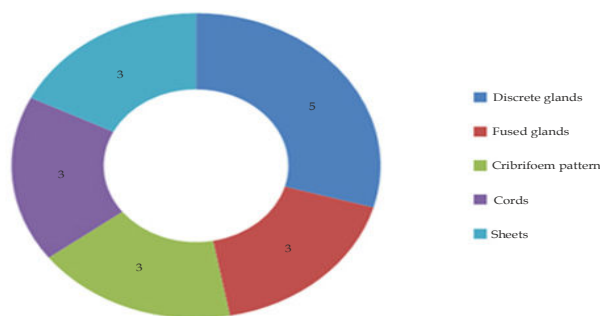
**Carcinoma Prostate**

*Microscopic Features*

Five cases of prostatic carcinoma were identified in the present study. All of them were adenocarcinomas involving the prostate. All of them showed one or more of the different growth patterns and were categorized depending on the predominant growth pattern. (Table 2, Fig. 4)

**Table 2:** Microscopic Findings in Carcinoma Prostate.

Microscopic findings	No of cases
Discrete glands	05
Fused glands	03
Cribriform pattern	03
Cords	03
Sheets	03



**Fig. 4:** Microscopic Findings in Carcinoma Prostate.

Majority of prostatic malignancies were found in the age group of 70-79 years in the present study.

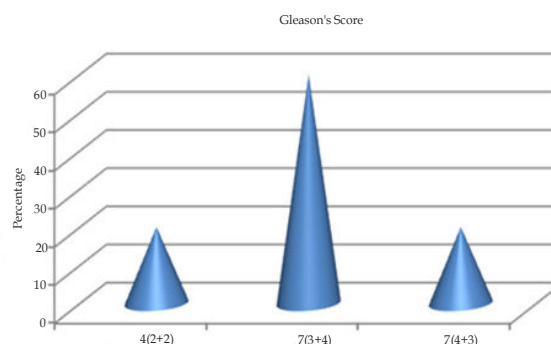
Adjacent tissues in the cases showed NH. No perineural invasion seen in these cases.

*Gleason's Score*

All of the five cases were graded using Gleason's scoring system. (Table 3, Fig. 5) Primary grade is assigned to dominant pattern and the secondary grade to second most prevalent pattern. These numeric grades were added to obtain a Gleason's score or sum. In tumors with one pattern of arrangements, the number is doubled.

**Table 3:** Incidence of Carcinoma with Reference to Gleason's Score and Grade.

Gleason's score	No of cases	Percentage	Gleason's grade
4(2+2)	01	20	Well differentiated
7 (3+4)	03	60	Moderately to poorly differentiated
7 (4+3)	01	20	Moderately to poorly differentiated
Total	05	100	



**Fig. 5:** Incidence of Carcinoma with Reference to Gleason's Score and Grade.

## Discussion

In the present study most of the specimens received were TURP. Out of 90 prostatic specimens received, 84 (94.5%) cases were benign lesions, one case was low grade intraepithelial neoplasia along with nodular hyperplasia, and prostatic malignancy (5.5%) was diagnosed in 5 cases. These findings are similar to other studies.<sup>7,8</sup> Bhatta S and Hirachan S reported 89.58 % of benign cases, 8.34% of HGPIN cases and 2.08 % of malignant cases.<sup>7</sup>

Studies from Saudi Arabia by Mansoor showed a lesser percentage of BHP cases compared to adenocarcinoma as compared to our study.<sup>9</sup>

In our study, among benign lesions, nodular hyperplasia of prostate was the histopathological diagnosis with or without associated prostatitis or metaplasia.

This finding showing a predominance of nodular hyperplasia among benign lesions is similar to other studies. Bhatta S and Hirachan S concluded that among the benign lesions, nodular hyperplasia of prostate was the most frequent histo-pathological diagnosis accounting for 89.58% cases.<sup>7</sup> Jehoram et. al.,<sup>10</sup> Bal et. al.,<sup>11</sup> and Dawam et. al.<sup>12</sup> found 93%, 87%, and 86% cases of BHP in their studies, respectively

In our study, among 84 benign lesions, majority of the cases were seen in 7<sup>th</sup> and 8<sup>th</sup> decade. One case was diagnosed as premalignant lesion and the age was 65 years

Majority of prostatic malignancies were found in the age group of 70-79 years in the present study.

This finding is in agreement with the study by Garg M et al,<sup>13</sup> Bhatta S and Hirachan S.<sup>7</sup> In a study done by Bhat et al, BHP was seen most common affecting age group 70-79 years with 41.17% cases, followed by age group 60-69 years with 40 % cases.<sup>6</sup> Studies done by Deshmukh et. al.<sup>14</sup> and Shakya et al<sup>15</sup> showed similar results, with 80% of BHP cases affecting these two decades of life.

In our study, chronic prostatitis was seen in 12 cases, granulomatous prostatitis in 3 cases and acute prostatitis in 5 cases. These findings are similar to most of the studies on prostatitis, like the study of Bhat et al,<sup>6</sup> Anim et. al.<sup>16</sup>, Bhatta S<sup>7</sup> and Hirachan S,<sup>8</sup> and Mohammed et. al.<sup>17</sup> These studies also reported chronic prostatitis as the most common inflammatory lesion affecting prostate followed by acute and granulomatous prostatitis. Patel SK et al<sup>18</sup> and Josephine A<sup>19</sup> have reported chronic prostatitis associated with nodular hyperplasia of prostate in 26.78% and 25.31% cases respectively. Sharma A

et al<sup>20</sup> found prostatitis in 33.06% cases of nodular hyperplasia of prostate out of which 86.42% cases were chronic non-specific prostatitis, 9.88% were acute prostatitis and 3.7% were granulomatous prostatitis

In our study, NH was associated with low grade PIN in one case showing 1.5% incidence of PIN. This is similar to a study done by Forae GD, Aligbe JU where only 0.9% of HG-PIN was encountered.<sup>8</sup> In the study by Bhatta S and Hirachan S,<sup>7</sup> 2(2.08%) cases showed HGPIN similar to the study by Sharma A et al<sup>20</sup> who have found 2.04% HGPIN in their studies. This is different from reports by Orozco *et. al.*, where prevalence of HG-PIN was 4.1%.<sup>21</sup>

Five cases of prostatic carcinoma were identified in the present study constituting 5.5% of all cases. Study done by Bhatta S and Hirachan S showed 8(8.34%) of prostate carcinoma.<sup>7</sup>

All the cases of prostate carcinoma were histologically adenocarcinoma in the present study. This finding was in agreement with other studies. In study done by Bhat et al,<sup>6</sup> Prostate cancer was found to be affecting 7 (7.6%) cases of all the 92 cases studied and all these 7 cases were of prostatic adenocarcinoma. These findings were in agreement with the studies of Subathra and Sangeetha,<sup>22</sup> Deshmukh et. al.<sup>14</sup> and Jatav et. al.<sup>23</sup> who also found 7.4%, 9% and 9.7% of all prostatic lesions as prostatic adenocarcinoma, respectively. Study done by Forae GD and Aligbe JU has shown that prostate cancer accounted for 23.6% of all prostatic tumor histologically diagnosed.<sup>8</sup>

All the studies also found adenocarcinoma as the principal variant of prostatic cancer, constituting more than 90% of all prostatic cancer cases. Study done by Forae GD and Aligbe JU also shows prostatic adenocarcinoma as the first majority constituting 96.7% of the malignant cases.<sup>18</sup>

Majority of prostatic malignancies were found in the age group of 70-79 years in the present study which was in close concordance with the studies of Bhat et al,<sup>16</sup> Forae GD and Aligbe JU.<sup>8</sup>

In our study 80% of cases were of Gleason score 7. Angurana in her studies found 64.3% cases with Gleasons score 6-10 which was in close agreement with our study.<sup>24</sup> Albasri et. al. found Gleasons score of 5-7 as the commonest followed by Gleason score 8-10.<sup>25</sup> In the study done by Bhat et al,<sup>6</sup> 56.16% cases of adenocarcinoma with Gleason score of 8-9. In the study by Bhatta S and Hirachan S,<sup>7</sup> most common grade was grade 4 and the most predominant Gleason score was 9. Similar to this Deshmukh BD et. al. found Gleason score 9 in 33.33% cases.<sup>14</sup>

Majority of the cases of prostatic adenocarcinoma were moderately to poorly differentiated in our study similar to other studies. Forae GD and Aligbe JU found out that moderately differentiated prostatic adenocarcinoma with (Gleason's score 5-7) was the most common accounting for 59.8% in the series.<sup>8</sup>

Perineural invasion is a pathognomic feature of prostate cancer if there is circumferential or intraneural invasion by the tumor cells. No cases in our study showed perineural invasion.

Various authors have reported perineural invasion in prostate carcinoma ranging from 24-42%.

Globally, there is general increase in prostate cancer incidence over the years. This could be due to the fact that there is more global awareness of the disease; which has led to improved health care seeking behaviour. Several studies of tumor grade reported that African-Americans have higher tumor grade and volumes than Caucasian counterparts with a similar stage of the tumor. This suggests that biological differences in tumorigenesis may be a factor in the course of disease among races. It may also partly be attributable to geo-ethnic variation, diet, environmental factors, and genetic factors.

## Conclusion

At present, H and E stained tissue sections are used for diagnosis of prostatic carcinoma specimens with selected cases being sent for immunohistochemical analysis and further ancillary studies. In this study out of 90 prostate specimens studied, commonest pathology encountered was benign lesions constituting 94.5% and malignant lesions were 5.5%.

Diagnosis of prostatic carcinoma was made in 5 cases. The incidence of carcinoma was 5.5% and the peak age group affected was between 71-80 years with the commonest symptoms of hesitancy, nocturnal and frequency.

Histologically, all the malignant lesions encountered were adenocarcinoma of prostate. The commonest pattern seen was acinar followed by arrangement of tumor cells in cords, sheets and cribriform pattern.

Use of immunohistochemistry and genetic profiling is recommended in all cases of prostatic adenocarcinoma for risk stratification.

## Conflicts of Interest

There are no conflicts of interest

## References

1. Lee C, Kozlowski MJ, Grayhack TJ. etiology of benign prostatic hyperplasia: Advances in BPH. Urol Clin N Am. 1995; 22(2):237-46.
2. Bushman W. Etiology, Epidemiology, and natural history: Benign prostatic Hyperplasia and lower urinary tract symptoms Urol Clin N Am. 2009;36(4): 403-15.
3. Guess AH. Epidemiology and Natural History of Benign Prostatic Hyperplasia: Advances in BPH. Urol Clin N Am. 1995; 22 (2):247-61.
4. Bostwick GD, Qian J, Schlesinger C. Contemporary pathology of prostate cancer: Localized prostate cancer. Urol clin N Am, 2003; 22(2): 181-207.
5. Akbulut ON, Guney S, Duman I, Comez I, Arisan S. Prostatic Intraepithelial neoplasm: Retrospective results of clinical, histopathological approaches. J cell and Molecular Biology 2004;3: 45-50.
6. Bhat S, Chaudhri S, Bhat P, Hatwal D. Histopathological Study of Prostatic Diseases in Garhwal Region. Int J Scientific Study 2015;3(8):136-40.
7. Bhatta S, Hirachan S. Prostatic lesions: Histopathological study in a tertiary care hospital. JManmohan Meml Inst Health Sci 2018;4:12-9
8. Forae GD, Aligbe JU. Histopathological patterns of prostate cancer in an African population: A private practice experience. Trop J Med Res 2014;17:16-9
9. Mansoor I. Pattern of prostatic diseases in Saudi Arabia. Int J Pathol 2003;2:2.
10. Jehoram TA, Sitara AS, Mohammed EB. Hyperplastic, premalignant and malignant lesions of the prostate gland. Hum Pathol 2005;36:480-5.
11. Bal MS, Kanwal S, Goyal AK, Singla N. Prostatic lesions in surgical biopsy specimens. JK Pract 2011;16:33-4.
12. Dawam D, Rafindadi AH, Kalayi GD. Benign prostatic hyperplasia and prostate carcinoma in native Africans. BJU Int 2000;85:1074-7
13. Garg M, Kaur G, Malhotra V, Garg R. Histopathological spectrum of 364 prostatic specimens including immunohistochemistry with special reference to grey zone lesions. Prostate Intl. 2013;1:146-151.
14. Deshmukh BD, Ramteerthakar NA, Sulhyan KR. Histopathological study of lesions of prostate- A five year study. Int J Health Sci Res. 2014;4:1-9.
15. Shakya G, Malla S, Shakya KN. Salient and comorbid features in benign prostatic hyperplasia: A histopathological study of the prostate. Kathmandu Univ Med J.2003;2:104-109.
16. Anim JT, Ebrahim BH, Sathar SA. Benign disorders of the prostate:A histopathological study. Ann Saudi Med 1998;18:22-7.

17. Mohammed AZ, Nwana EJ, Anjorin AS. Histopathological pattern of prostatic diseases in Nigerians. *Afr J Urol* 2005;11:33-8
18. Patel SK, Surti HB. Analysis of prostatic biopsies in a tertiary care hospital in correlation with prostatespecific antigen levels: A clinicopathological study. *Int J Med Sci Public Health*. 2017;6:842-846.
19. Josephine A. Clinicopathological study of prostatic biopsies. *J ClinDiagn Res*. 2014;8:4-6.
20. Sharma A, Sharma M, Gandhi S, Khajuria A, Goswami KC. Histomorphological spectrum of prostatic lesions: a retrospective analysis of transurethral resection of prostate specimens. *Int J Res Med Sci*. 2017;5: 2373-2378.
21. Orozco R, O'Dovid G, Kunnel B, Miller MC, Veltri RW. Observations on Pathology trends in 62,537 prostatic biopsies obtained from urology private practices in the United States. *Urology* 1998;51:186-95.
22. Subathra K, Sangeetha N. histopathological study of prostatic lesions and assessment with AGNOR index. *Int J Pharm Bio Sci* 2014;5:B253-60.
23. Jatav J, Tomar KS, Pandit V, Iyenger S, Jain B. Characterization of prostatic lesions in surgically resected specimens. *Indian J Appl Res* 2015;5:444-6.
24. Angurana N. Pattern of prostate diseases - A histopathological study in Jammu. *Int J Basic Appl Med Sci* 2014;4:163-7.
25. Albasri A, El-Siddig A, Hussainy A, Mahrous M, Alhosaini AA, AlhujailyA Histopathologic characterization of prostate diseases in Madinah, Saudi Arabia. *Asian Pac J Cancer Prev*2014;15:4175-9

