

Expression of Androgen Receptor in Triple Negative Breast Cancer Biopsies and Its Correlation with Prognostic Markers

Anshita Arora¹, Rashmi Chaturvedi², Vijay Goel³, Sangita Bohara⁴,
Vivek Gupta⁵, Mukesh Shukla⁶

¹Postgraduate resident ^{2,4}Associate Professor ⁵Professor & Head, Department of Pathology ³Associate Professor, Department of Surgery ⁶Assistant Professor, Department of Community Medicine, Hind Institute of Medical Sciences, Barabanki, Uttar Pradesh 225003, India.

Abstract

Context: Androgen receptor (AR) has been found to be associated with the occurrence and progression of breast cancer; however, their clinical significance in triple negative breast carcinoma (TNBC) cases is still a matter of debate.

Aims: The present research work was done to study the expression of AR in TNBC biopsies (ER-, PR-, & HER2/neu-) by immuno-histochemistry and to correlate AR expression patterns in TNBC with Ki-67 and other prognostic markers.

Settings and Design: The present cross-sectional study was conducted by Department of Pathology, Hind Institute of Medical Sciences, Barabanki, Uttar Pradesh from 2015-16.

Methods and Material: ER, PR and AR negative expression were defined as <10% nuclear staining and also HER2 (2+), FISH was performed. Nuclear staining was done for estimation of Ki-67.

Statistical Analysis Used: Categorical variables were expressed as frequencies and percentages and Chi-square test was used to study the association. P value < 0.05 was considered as significant.

Results: The mean age of TNBC cases was 53.8 ± 11.2 years. The most common Blooms Richardson histopathological grade found was Grade II in 35 cases (70%) followed by Grade III in 15 cases (30%). Majority of TNBC in our study group (60%) were AR positive (intermediate or strong). The AR positivity was found to be significantly associated with postmenopausal status and lymph nodes involvement. About 65% of the cases negative for AR intensity were from patients who were in pre-menopausal group. Among 80% cases with involvement of lymph node, the AR intensity was strongly positive. No significant correlation was observed between AR and Ki-67 expression.

Conclusions: Although, in our study no statistically significant correlation was observed between AR and Ki-67 index among TNBC cases but a strong AR intensity was observed with lymph node involvement. Thus in TNBC patients, evaluation of AR status may provide additional information on prognosis and treatment.

Keywords: Breast Cancer; Estrogen Receptor; Her-2/Neu; Progesterone Receptor.

Corresponding Author:

Rashmi Chaturvedi, Associate Professor,
Department of Pathology, Hind Institute of
Medical Sciences, Barabanki, Uttar Pradesh
225003, India.

E-mail: rashmi.chaturvedi1955@gmail.com

Received on 10.02.2019,

Accepted on 07.03.2019



How to cite this article:

Anshita Arora, Rashmi Chaturvedi, Vijay Goel et al. Expression of Androgen Receptor in Triple Negative Breast Cancer Biopsies and Its Correlation with Prognostic Markers. *Indian J Pathol Res Pract.* 2019;8(2):144-152.

Introduction

Breast carcinoma is the most common malignant tumor and is one of the most leading cause of death in women due to cancer; with more than ten lakhs cases occurring worldwide annually [1]. Of which over 1,40,000 new breast cancer patients are estimated to be diagnosed annually in India only [2]. Data from all urban and rural population-based cancer registries in India suggest a rising incidence of breast cancer in India [3]. Breast cancer in India is ranked number one cancer among Indian females with age adjusted rates as high as 25.8 per 1 lakh women [4].

In terms of prognosis, in addition to histological grade, tumor subtype, lymph node involvement, assessment of triple markers- ER, PR and HER2/neu, and the proliferative activity based on Ki-67 score have become significant requirements for the oncologist. Recent attention has been directed at molecular classification of breast cancer based on triple markers which has prognostic and therapeutic applications. Breast cancer is a highly diverse disease with prevalence of androgen receptor (AR) expression in triple negative breast cancer (TNBC) ranging from 13.7% to 64.3% [5]. Breast cancer can be commonly classified into five types according to the mRNA expression profile: luminal A (ER+, / PR+ /, both, with HER-2neu-), luminal B (ER+, / PR+ /, both, with HER-2neu+), human epidermal growth factor receptor 2 (HER2)-enriched, basal-like (ER-, / PR- /, both, with HER-2neu±) and normal breast like. [6] These breast cancers show variations in gene expression patterns. These patterns are derived from cDNA microarrays, mainly to identify intrinsic gene type set which depicted the basal-like type and was characterized by high expression of CK5 and CK17, laminin, and fatty acid binding protein; while normal breast like group showed the highest expression of many genes known to be expressed by adipose tissue and other non-epithelial cell types [7].

Triple negative breast cancer (TNBC) means lacking estrogen receptor (ER) and progesterone receptor (PR) expression as well as human epidermal growth factor receptor 2 (HER2)

amplification [8]. TNBC is an intractable breast cancer because of its highly malignant potential, characterized by aggressive growth and rapid dissemination to important organs. TNBC tumours are generally larger in size, are of higher grade, have lymph node involvement at diagnosis, and are biologically more aggressive [9]. Most of these studies with respect to TNBC have been performed in western countries and in India there is paucity of data. With the preceding context, the present research work was done to study the expression of AR in TNBC Biopsies (ER-, PR-, & HER2/neu) by immuno-histochemistry and to correlate AR expression patterns in TNBC with Ki-67 and other prognostic markers.

Materials and Methods

Study Design and Sample size: A cross sectional study was conducted on 50 TNBC cases on which AR immunohistochemistry expression was correlated with Ki-67 indexing and prognostic markers. Tru-cut biopsies, along with radical mastectomy specimens were received for the routine histopathological evaluation from the department of Surgery, in Hind Institute of Medical Sciences. All breast cancer biopsies which proved to be negative for ER, PR and Her2/neu on IHC were taken and labelled as TNBC.

Method of collection of data: The clinical history and data of relevant investigations done were collected from the patient's case sheets. For study of prospective cases, the mastectomy and lymph node dissection specimen were received in the pathology department in 10% formalin. For every case the standard protocol for surgical grossing of radical mastectomy specimens was followed. Multiple sections were taken from almost all tumor, surgical margins, nipple and areola, non-neoplastic breast and all the lymph nodes. After conventional processing paraffin sections of 5 micron thickness were stained by haematoxylin and eosin (H & E) for histo-pathological study and additional 4 micron meter sections were taken from single paraffin block of tumor tissue on 4 glasses coated with adhesive (poly-lysine) for IHC to detect ER, PR,

and HER2/neu negative expression (TNBC). Then this TNBC was subjected for the IHC expression of AR with Ki-67 proliferative index from biogenic kit.

Immunohistochemical Evaluation: Immunohistochemistry is performed on 3-4 mm thick sections taken on poly-L-lysine coated slides. Antigen retrieval was performed by heating the sections in citrate-buffer at pH 6.0 using pressure cooker. Rabbit monoclonal antibody was used to bind with primary antigen and was detected by adding secondary antibody conjugated with horse radish peroxidase-polymer and diaminobenzidine substrate. In this study, MART-1 antigen of biogenic laboratory products was used.

The H&E stained slides were studied for tumor histology, type, Blooms Richardson grade, lymph node status, embolization, TNM and Ki-67 score. [10] The immune-stained slides were examined for nuclear staining in case of ER, PR, AR and Ki-67 and membranous staining for HER2/neu. In each case the proportion of positive staining tumor cells (expressed in percentage) per 1000 cells was counted on a 40x power field. The cases in which the nuclear marker was present in at least 5% of cells were considered positive and the average intensity of staining (expressed as 0.1+, 2+, or 3+) was evaluated by the Allred score; [11] except AR intensity which was expressed as 0-1-negative, 1+= Intermediate and 2+= Strong. [12] The relationship between various parameters such as age, menopausal status, parity, mammography findings, tumor size, tumor extent, histological type, histological grade, lymph node status, TNBC status with the expression of AR and Ki-67 index was studied.

Data Analysis: The data was analysed using Epi-Info 7; [13] and the results were transferred to preformed tables in accordance to aims and objectives. Quantitative parameters such as age, size of tumors etc. were summarized in terms of mean. Percentage expression for positivity of ER, PR, HER2/neu and Ki-67 has been done. The differences in the positivity for different independent variables were tested through 'Chi' square test for qualitative variables.

Ethical Clearance: Owing to ethical considerations, permission was obtained from the Institutional Ethical Committee of the institute before commencing the study.

Results

In the present study, 50 cases of triple negative breast carcinomas were evaluated

histopathologically and subsequently evaluated for IHC marker AR. The age of the patients ranged between 32 to 85 years. About two-third patients were seen in between 35-60 years of age group followed by those aged more than 60 years (30%). Almost half of the females were of post-menopausal group (54%). Right breast was more commonly involved comprising of 27 cases (54%). Upper lateral position was most commonly involved (17 cases i.e. 34%), followed by lower lateral (30%), and the least was reported simultaneously together in the upper and lower lateral position (2%). [Table 1].

Table 1: Distribution of Triple Negative breast carcinoma cases by biosocial and tumour characteristic

Biosocial characteristics	Number	Percentage
Age-group		
≤35	4	8%
35-60	31	62%
≥60	15	30%
Menopausal status		
Pre-menopausal	23	46%
Post-Menopausal	27	54%
Side		
Left	23	46%
Right	27	54%
Quadrant		
Upper Medial	4	8%
Upper Lateral	17	34%
Lower lateral	15	30%
Lower-Medial	14	28%
Upper & Lower lateral	1	2%

(N=50)

Out of 50 triple negative breast cancer cases studied, 41 cases (82%) were invasive ductal carcinoma, followed by 3 cases (6%) of poorly differentiated carcinomas. Two cases of each Paget's disease of breast and medullary carcinoma and one case each of papillary carcinoma and lobular carcinoma were noted. With respect to TNM stages, there were 23 cases (46%) of type I stage followed by 12 cases (24%) of type IIA stage and least were 6, 5 and 4 cases (12%, 10%, 8%) of type IIB, IIIB and IIIA respectively. With respect to histopathological grade, 35 cases (70%) were of grade II followed by 15 cases (30%) of grade III type. Lymph node involvement was found only in 10% of cases. Also, lymphatic and vascular embolization was observed in 42% and 14 cases respectively. Also, out of 50 triple negative breast cancer cases studied, 21 cases (42%) were of high grade followed by low and intermediate grade (32% and 26%) respectively. [Table 2].

Table 2: Distribution of the Triple Negative breast carcinoma cases on the basis of Clinico-pathological profile.

Biosocial characteristics	Number	Percentage
Histopathological Type		
Invasive Ductal CA	41	82%
Papillary CA	1	2%
Apocrine Differentiated CA	3	6%
Paget's disease of breast	2	4%
Medullary CA	2	4%
Lobular CA	1	2%
TNM staging		
I	23	46%
IIA	12	24%
IIB	6	12%
IIIA	4	8%
IIIB	5	10%
Histopathological grade		
Grade II	35	70%
Grade III	15	30%
Lymph node		
Positive	10	20%
Negative	40	80%
Lymphatics Embolization		
Detected	21	42%
Absent	29	58%
Vascular Embolization		
Detected	7	14%
Absent	43	86%
Ki-67 Grade		
Low	16	32%
Intermediate	13	26%
High	21	42%
AR Intensity		
Negative	20	40%
Intermediate	11	22%
Strong	19	38%

(N=50)

About 70% of the TNBC specimens that were strongly positive for the AR were from patients in the age group of 35-60 years. However, almost equal proportion of cases were found with respect to AR positivity among patient's age ≥ 60 years. About 75% of the strongly positive cases belonged to grade II of NBR (Nottingham) grading. Apart from that 40% of both grade II and grade III TNBC specimens were negative for AR. Also, majority (80%) of the TNBC cases with TNM IIIB grade were strongly positive for AR receptor. Also about 80% of TNBC cases with vascular embolization showed strong AR positivity. The distribution of cases with lymphatic embolization was almost equal in both groups with AR negative as well as low AR intensity. The association of AR positive intensity was not found to be significantly associated with age, NBR grading, TNM staging, embolization (with lymphatic as well as vascular) and Ki-67 expression. Almost 65% of the cases negative for AR intensity were from patients who were in pre-menopausal group. However, equal number of cases from pre-menopausal and post-menopausal were strongly positive for AR (40%). The association between AR positive intensity and menopausal status was found to be statistically significant ($p < 0.05$). Among 80% cases with involvement of lymph node the AR intensity was strongly positive, while no lymph node involvement was observed in 90% cases negative for AR. The association between lymph node involvement and AR intensity was found to be significantly associated ($p < 0.05$). Among the 50 cases included in our study, the association of Ki-67 proliferative marker with androgen receptor intensity was found to be statistically insignificant. Among 21 cases which were of high grade, 42.9% were strongly positive for AR intensity. However, the association in between these entities with Androgen Receptor intensity was statistically insignificant ($p > 0.05$) [Table 3].

Table 3: Association between AR positive intensity with of Triple Negative with Clinico-pathological parameters

Clinico-pathological parameters	Androgen Receptor			p value (Chi-Square)
	Negative	intermediate	strong	
Age				
≤ 35	3 (75%) [15%]	0 (0.0) [0.0]	1(25%) [5%]	0.358
35-60	12(38.7%) [60%]	5(16.1%) [50%]	14(45.2%) [70%]	
≥ 60	5 (33.3%) [25%]	5(33.3%) [25%]	5(33.3%) [25%]	
Menopausal status				
Premenopausal	13(56.5%) [65%]	1(4.3%) [10%]	9(39.1%) [45%]	0.017*

Postmenopausal	7 (25.9%) [35%]	9 (33.3%) [90%]	11(40.7%) [55%]	
NBR (Nottingham) Grading				
Grade II	14 (40%) [70%]	6 (17.3%) [60%]	15(42.9%) [75%]	0.700
Grade III	6 (40%) [30%]	4 (26.7%) [40%]	5(33.33%) [25%]	
TNM				
I	6 (26.1%) [30%]	6 (26.1%) [30%]	11(47.8%) [55%]	
IIA	6 (50%) [30%]	2 (16.7%) [20%]	4(33.3%) [20%]	
IIB	2 (33.33%) [10%]	1 (16.7%) [10%]	3(50%) [15%]	0.590
IIIA	2 (50%) [10%]	1 (25%) [5%]	1(25%) [5%]	
IIIB	4 (80%) [20%]	0 (0.0) [0.0]	1(20%) [5%]	
Lymph node status				
Present	2 (20%) [10%]	0 (0.0) [0.0]	8(80%) [40%]	0.013*
Absent	18 (45%) [90%]	10 (25%) [100%]	12(30%) [60%]	
Vascular Embolization				
Detected	2 (20%) [10%]	0 (0.0) [0.0]	8(80%) [40%]	0.920
Absent	18 (45%) [90%]	10 (25%) [100%]	12(30%) [60%]	
Lymphatic Embolization				
Detected	10 (47.6%) [50%]	2 (9.5%) [20%]	9(42.9%) [45%]	0.274
Absent	10 (34.5%) [50%]	8 (27.6%) [80%]	11(37.9%) [55%]	
Ki-67 Grading				
Low	5 (31.3%) [25%]	4 (25%) [40%]	7(43.8%) [35%]	
Intermediate	7 (53.8%) [25%]	2 (15.4%) [20%]	4(30.8%) [20%]	0.796
High	8 (38.1%) [40%]	4 (19.0%) [40%]	9(42.9%) [45%]	

(N=50)

*p<0.05 considered as significant

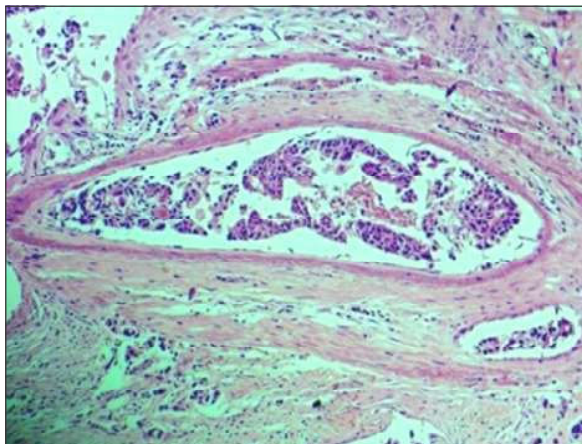


Fig. 1: H&E section (10x) showing Lympho-vascular emboli.

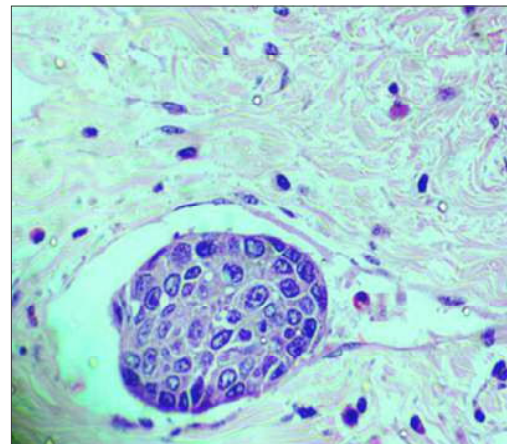


Fig. 2: H&E section (40x) showing Lymphatic emboli.

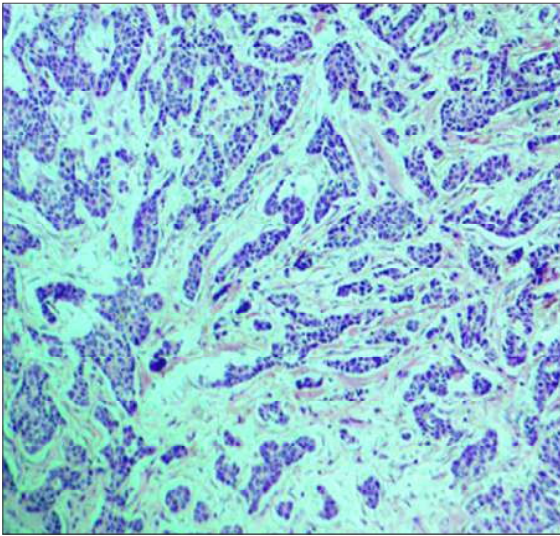


Fig. 3: H&E section (10x) is full of tubules portraying Grade II Nottingham tumour.

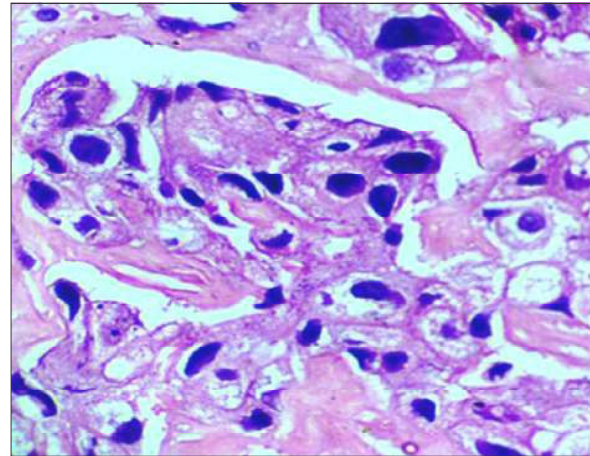


Fig. 6: H&E section (40x) is full of nuclear atypia portraying Grade III Nottingham tumour.

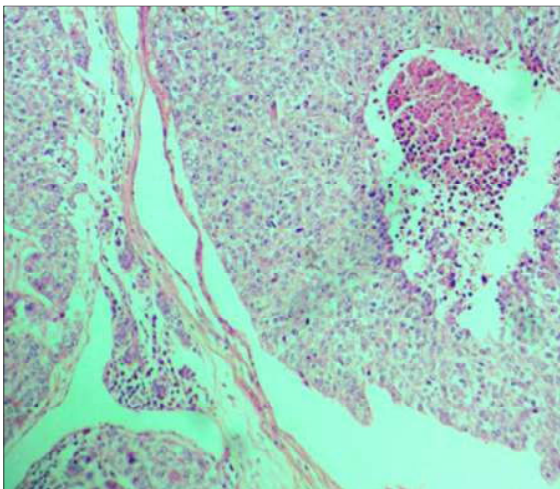


Fig. 4: H&E section (10x) is full of Necrosis portraying Grade III Nottingham tumour.

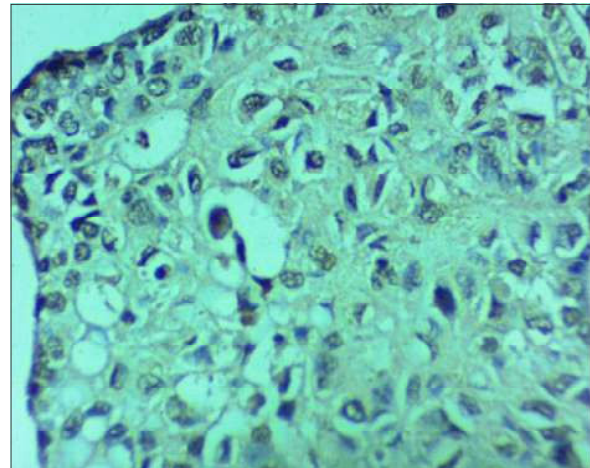


Fig. 7: IHC section (40x) is strong Androgen Receptor Intensity portraying Grade III Nottingham tumour.

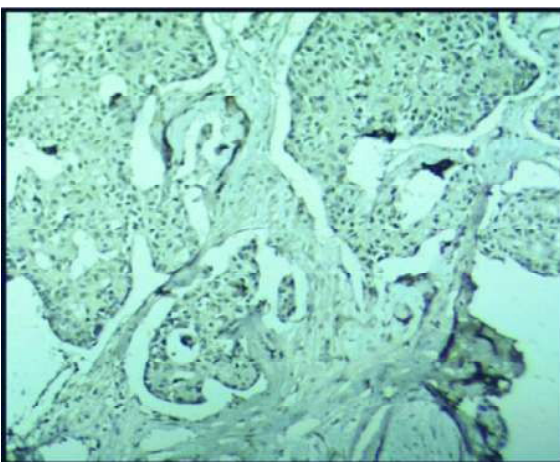


Fig. 5: Invasive Ductal Carcinoma showing Strong Androgen receptor intensity (10X)

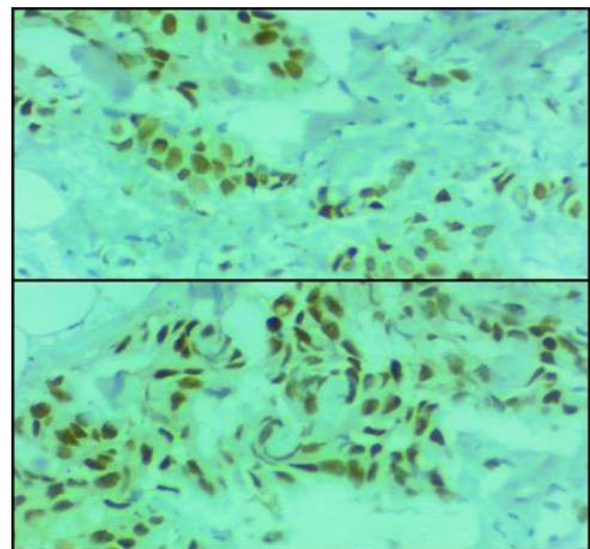


Fig. 8: Invasive Ductal Carcinoma showing Strong Androgen receptor intensity (40X)

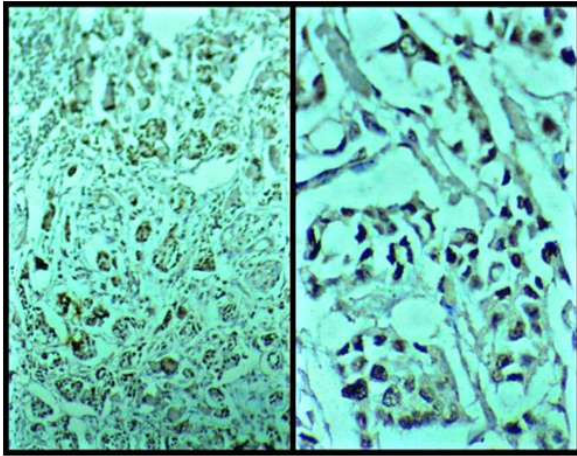


Fig. 9: Invasive Ductal Carcinoma showing Intermediate Androgen receptor intensity(10X& 40X respectively)

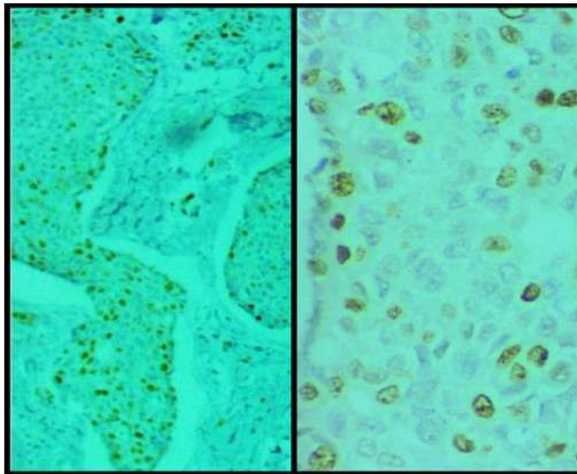


Fig. 10: Invasive Ductal Carcinoma showing Intermediate Androgen receptor intensity(10X& 40X respectively)

Discussion

The present study includes 50 triple Negative breast carcinomas cases which is categorized in basal subgroup according to molecular classification of breast. In recent years, it has been showed that androgen receptor plays an important role in the genesis and development of breast cancer. In present study we have investigated the expression of Androgen Receptor (AR) and its significance in TNBC biopsies for any correlation with other prognostic markers and clinico-pathological parameters. This includes age, parity menopause status, tumor side and tumor quadrant, histopathological grade, lymph-vascular embolization lymph-node status, and Ki-67 score.

In our study of total 50 TNBC patients, the mean

age was 53.8 years and majority of patients were in the age group 35-60 years (62%). However, in our study, age was not found to be statistically associated with androgen receptor intensity. Similar findings have been reported by Xiang Luo et al; [5] in their study among the patients of TNBC with mean age of 50 yrs. However, contrary to this, S Park et al. [14]; in 2009 showed patient's mean age to be 35 years, with 96% of the cases being above 35 years of age. Yet another study by Yuko Asano et al [12]; in 2017 showed the patient's mean age to be 55 years. In our study the association between AR positive intensity and menopausal status was found to be statistically significant. ($p < 0.05$). The results in our study show some harmony with Xiang Luo et al [5]; who reported AR positive intensity to be significantly associated with menopausal status. In our study, the most common quadrant involved was superior lateral in 17 cases (34%), followed by lower lateral in 15 cases (30%) followed by 9 cases in inferior-medial (18%). The least frequent involvement was that of superior medial quadrant (4), lower medial (4) and simultaneously involving both upper & lower quadrant together (1). This finding is similar to results of Yuko Asano et al in 2016 [12].

Prognostic features findings which were used in our study to correlate with the expression of Androgen receptor intensity were histopathological grade, lymph-vascular emboli, lymph node status, TNM staging and Ki-67 scoring. In our study according to Blooms Richardson histopathological, androgen receptor intensity was maximally found in Grade II in 35 cases (70%) followed by Grade III in 15 cases (30%). However, it was not significantly associated with androgen receptor intensity ($p > 0.05$). Similar to our study, Yuko Asano et al showed 71.4% cases in grade II & III respectively [12]. Another study by S. Park et al study also showed 22 cases in grade II followed by 21 cases in grade III with statistically significant androgen receptor expression [14]. In our study according to TNM histopathological staging, androgen receptor intensity was maximally found in TNM stage I (46%) followed by 24% cases in IIA and least involved 12%, 10% and 8% in IIB, IIIB and IIIA respectively. However, the association TNM staging was also not statistically significant with androgen receptor intensity. Similar to our study S. Park et al. in 2010 showed 49.2% cases in stage I followed by 29.9% cases in stage II. [14] Yet another study by Keely M. Mc Namara et al. showed 40% cases in stage IIA followed by 27.8% cases in stage I. [15]

In our study Lymphatic and vascular

embolization was observed in 45% and 40% cases of strong androgen receptor intensity. While only 2 cases showed vascular emboli in negative androgen receptor TNBC cases. However, the association between these entities with androgen receptor intensity was found to be statistically insignificant ($p > 0.05$). Our study was only comparable with Yuko Asano et al. [12], who showed only 21.4% cases of lymph-vascular emboli which with statistically insignificant association with AR intensity ($p > 0.05$). Among the 50 cases included in our study, 10 cases (20%) have showed positive lymph node followed by 80% which show a high negativity correlated with androgen receptor intensity. However, the association between the lymph node involvement with androgen receptor intensity was found to be statistically significant. The findings in the present study are in concordance with the results reported by Xiang Lu et al and Asana et al. [5,12]. In our study, the association of Ki-67 proliferative marker with androgen receptor intensity was found to be statistically insignificant. Similar findings were also reported by Xiang Luo et al. and Patnayak R et al. [5,16]. However, in few other studies conducted by Yuko Asano et al and Park et al significant association were observed between Ki-67 and AR positive intensity in TNBC cases [12,14].

The strength of the study is based on the data which was gathered from a rarely found entity of triple negative breast carcinoma cases. Since the study was carried out in a tertiary care institute and highly experienced pathologists were involved in the evaluation of the specimens and reporting, this makes our data very consistent, precise and reliable.

Conclusion

The present study includes a total 50 triple negative breast carcinomas (TNBC) cases in a one year time period which belongs to basal subgroup categorized in molecular classification of breast. The present study concludes with the findings that maximum number of TNBC in our study group (60%) were AR positive (intermediate or strong). The AR positivity was also significantly associated with postmenopausal status and metastatic lymph nodes. Majority of AR positivity were seen from 35-60 years age group (62%). Among 80% cases with involvement of lymph node the AR intensity was strongly positive, while no lymph node involvement was observed in 90% cases negative for AR. As the results relating to AR positivity with TNBC were not statistically significant, therefore it is suggested

to conduct similar studies in larger group of TNBC patients to further elucidate the association. It is quite important to segregate that population which is AR positive in TNBC cases because they show a promising response to the treatment with better survival.

Source(s) of support:

Presentation at a meeting: None

Conflicting Interest

(If present, give more details): None

References

1. Rosai J. Breast. In: Rosai J. Rosai and Ackerman's Surgical Pathology. 10th edition. St. Louis: Mosby; 2011. pp.1659-1770.
2. Ferlay J, Soerjomataram I, Ervik M, Dikshit R, Eser S, Mathers C et al. GLOBOCAN 2012 v1.0, Cancer Incidence and Mortality Worldwide: IARC CancerBase No. 11 [Internet]. 2013 [cited 2014 September 11]; Available from: <http://globocan.iarc.fr>.
3. Leong SPL, Shen Z, Liu T, Agarwal G, Tajima T, Paik N, et al. Is breast cancer the same disease in Asian and Western countries?. World J Surg. 2010; 34:2308-24.
4. Malvia S, Bagadi S, Dubey U, Saxena S. Epidemiology of breast cancer in Indian women. Asia-Pacific Journal of Clinical Oncology. 2017;13(4):289-95.
5. Luo X, Shi Y, Li Z, Jiang W. Expression and clinical significance of androgen receptor in triple negative breast cancer. Chinese Journal of Cancer. 2010;29(6):585-90.
6. Abd El-Rehim D, Ball G, Pinder S, Rakha E, Paish C, Robertson J et al. High-throughput protein expression analysis using tissue microarray technology of a large well-characterised series identifies biologically distinct classes of breast cancer confirming recent cDNA expression analyses. International Journal of Cancer. 2005;116(3):340-50.
7. Sorlie T, Perou C, Tibshirani R, Aas T, Geisler S, Johnsen H et al. Gene expression patterns of breast carcinomas distinguish tumor subclasses with clinical implications. Proceedings of the National Academy of Sciences. 2001;98(19):10869-10874.
8. Podo F, Buydens LM, Degani H, et al. Triple-negative breast cancer: present challenges and new perspectives. Mol Oncol. 2010;4(3):209-29.
9. Lehmann B, Bauer J, Chen X, Sanders M, Chakravarthy A, Shyr Y et al. Identification of human triple-negative breast cancer subtypes and preclinical models for selection of targeted therapies. Journal of Clinical Investigation. 2011;121(7):2750-2767.
10. Elston CW, Ellis IO. Pathological prognostic factors

- in breast cancer. I. The value of histological grade in breast cancer: experience from a large study with long-term follow-up. *Histopathology*. 1991;19:403-10.
11. Allred DC, Bustamante MA, Daniel CO, Gaskill HV, Cruz AB Jr. Immunocytochemical analysis of estrogen receptors in human breast carcinomas. Evaluation of 130 cases and review of the literature regarding concordance with biochemical assay and clinical relevance. *Arch Surg*. 1990;125:107-13.
 12. Asano Y, Kashiwagi S, Goto W, Tanaka S, Morisaki T, Takashima T et al. Expression and Clinical Significance of Androgen Receptor in Triple-Negative Breast Cancer. *Cancers*. 2017;9(12):4.
 13. Dean AG, Arner TG, Sunki GG, Friedman R, Lantinga M, Sangam S, Zubieta JC, Sullivan KM, Brendel KA, Gao Z, Fontaine N, Shu M, Fuller G, Smith DC, Nitschke DA, and Fagan RF. Epi Info™, a database and statistics program for public health professionals. CDC, Atlanta, GA, USA, 2011.
 14. Park S, Park H, Choi S, Lee J, Park B, Lee K. Expression of Androgen Receptor in Breast Cancer. *Cancer Research*. 2009;69(24 Supplement):4156-4156.
 15. McNamara K, Yoda T, Miki Y, Chanplakorn N, Wongwaisayawan S, Incharoen P et al. Androgenic pathway in triple negative invasive ductal tumors: Its correlation with tumor cell proliferation. *Cancer Science*. 2013;104(5):639-646.
 16. Patnayak R, Jena A, Bhargavi D, Chowhan AK. Androgen receptor expression in triple negative breast cancer - Study from a tertiary health care center in South India. *Indian J Med Paediatr Oncol* 2018;39:28-31.
-