

# Comparative Study between Subcostal Transverses Abdominis Block and Erector Spinae Plane Block for Post-operative Opioid Sparing Analgesia in Laparoscopic Cholecystectomy Patient

S.P. Krupani<sup>1</sup>, Gollamudi Uday<sup>2</sup>

## How to cite this article:

S.P. Krupani, Gollamudi Uday/Comparative Study between Subcostal Transverses Abdominis Block and Erector Spinae Plane Block for Post-operative Opioid Sparing Analgesia in Laparoscopic Cholecystectomy Patient/Indian J Anesth Analg. 2023;10(4) 143-149.

## Abstract

**Background and Aim:** Laparoscopic cholecystectomy is one of the most commonly performed minimally invasive intra abdominal surgeries to remove the diseased gallbladder. Though associated with complications like pneumoperitoneum. Major benefits include reduced post-operative pain and fewer wound related adverse effects. Growing need for opioid sparing analgesia has led to use of regional techniques for post-operative pain relief.

Aim of this study is to compare quality and duration of post-operative analgesia between subcostal transverses abdominis block and erector spinae plane block.

**Methods:** It is a prospective study, where 40 patients were randomly allocated into two groups of 20 each. All the patients received 40 ml of inj 0.25% bupivacaine + 10 mcg inj dexmedetomidine in total. Erector spinae plane (EPS) block was performed in one group of patients and other received sub costal transverses abdominis plane (SCTAP) block. Quality of post-operative analgesia is documented using visual analogue score (VAS) and duration being assessed by the need for rescue analgesia for the set duration of post-operative stay.

**Results:** In the erector spinae plane block group the VAS is considerably lower compared to subcostal transverses abdominis block group. Need for rescue analgesia with NSAIDs was lower in erector spinae plane block group patients. No complications related to the block were documented in either group.

**Conclusion:** In conclusion ultrasound guided bilateral erector spinae plane block provides analgesia superior to bilateral subcostal transverses abdominis plane block.

**Keywords:** Laparoscopic cholecystectomy; Post-operative Analgesia; Erect or Spina Eplane Block; Subcostal Transverses Abdominis Plane Block; Visual Analogue Score; Opioid Free Analgesia.

**Author's Affiliation:** <sup>1</sup>Post Graduate, <sup>2</sup>Assistant Professor, Department of Anesthesiology, Apollo Institute of Medical Science and Research, Hyderabad 500033, Telangana, India.

**Corresponding Author:** Gollamudi Uday, Assistant Professor, Department of Anesthesiology, Apollo Institute of Medical Science and Research, Hyderabad 500033, Telangana, India.

**E-mail:** gollamudiudayreddy@gmail.com

**Received on:** 12.06.2023

**Accepted on:** 31.07.2023

## INTRODUCTION

Laparoscopic Cholecystectomy (LC) has become the gold standard for symptomatic gallstone disease. It is being practiced as a day care procedure in healthy individuals in American Society of Anesthesiologists (ASA) grade I and II.<sup>1</sup> The complexity of pain following laparoscopic cholecystectomy, growing need for opioid sparing



This work is licensed under a Creative Commons Attribution-NonCommercial-ShareAlike 4.0.

analgesia, increased incidence of pulmonary dysfunction, physical inactivity, mood and sleep disturbances suggests that effective treatment of post-operative pain should be multimodal in nature.

Randomized trial done by Michaloliakou *et al.* and Bisgaard *et al.* Precluded definitive conclusions on the subject, as perioperative use of NSAIDs or COX-2 inhibitors, opioids, steroids, gabapentin, alpha 2 receptor agonist, N-methyl-d-aspartate (NMDA) receptor antagonists, incisional instillation of local anesthetics and regional anesthesia techniques play multi factorial role. The aim of this study is to test the hypothesis that ultrasound guided erectorspinae plane block compared to subcostal transverses abdominis block can reduce use of opioid during the first 24 hrs after laparoscopic cholecystectomy.

---

## MATERIAL AND METHODS

---

*Study design:* A prospective randomized, controlled comparative study conducted in Apollo Institute of Medical Sciences and Research.

*Sample size:* With accuracy mode calculations with VAS as the primary variant and assuming type 1 error protection of 0.05, a total sample size of 40 patients was required for the study.

*Inclusion criteria:* Patients aged 18-40 years for elective laparoscopic cholecystectomy surgery under general anesthesia.

Patients with (American Society of Anesthesiology) ASA 1 and ASA 2 classification.

*Exclusion criteria:* Patients who refuse to give consent for the block.

Patients with a history of cardiovascular disorder, unstable hemodynamic, uncontrolled diabetes and hypertension.

*Pregnant Women:* Patients with allergic history to the said drugs.

Patients with coagulation disorder, infection at the injections site of the block.

*Patient Randomization:* Patients were randomly allocated into two groups based on an envelope based randomization created by a researcher how as not involved in the study. For each patient, in the operation theater the anesthesiologist opens the envelope indicating the type of block to be performed on the patient.

### Methodology

On the day of surgery patients were shifted to the pre-operative area, after obtaining a brief history,

confirming the NBM status patient is shifted to the operation theater.

In the operating theater, standard monitoring with electrocardiography, non-invasive blood pressure and peripheral oxygen saturation probe are applied to all patients.

After the securing 20 or 18 gauge intravenous line, 80-100 ml/hour isotonic saline infusion was started. After administering IV midazolam 0.05 mg/kg, IV glycopyrolate 0.005-0.01mg/kg and ondansetron 0.1-0.3 mg/kg, pre-oxygenation was done with 100% oxygen and general anesthesia was induced with IV Fentanyl 1-2 mcg/kg and IV propofol 2-3 mg/kg.

After securing mask ventilation, intubation will be facilitated with IV rocuronium bromide 0.6mg/kg for muscle relaxation and endotracheal tube of appropriate size is secured under direct laryngoscopy.

Maintenance of anesthesia was provided with 2% isoflurane 3 L of 40% O<sub>2</sub> and 60% air mixture and IV atracurium 0.1 mg/kg body weight.

---

### Block interventions

---

*Group E:* Following intubation, patients in the ESP block group were placed in the lateral decubitus position and cocktail of study drug 40ml 0.25% bupivacaine + 10 mcg of dexmedetomidine was kept ready. The linear ultrasound probe is placed in longitudinal orientation at the level of the T7 spinous process in the midline and then the probe is moved 3 cm laterally. The ultrasound landmarks, which included the T7 transverse process and the overlying erector spinae muscle, were identified. Under aseptic conditions, a 50mm 22 gauge stimuplex block needle was inserted in-plane at an angle of 30-40° in cranial-to-caudal direction until the tip contacted the T7 transverse process. After hydro-dissection with 2-3 ml of isotonic saline solution confirmed the correct needle tip position, 10 ml of study drug was injected deep to the erector spinae muscle. The same procedure was repeated on the opposite side and also bilateral at T9 level on each side.

*Group S:* In the second group of patients receiving SCTAP block with a subcostal approach in the supine position. The ultrasound probe was placed in the midline of the abdomen 2 cm below the xiphisternum and moved right laterally along the subcostal margin to the anterior axillary line. The landmarks, which included the rectus abdominis muscle and underlying transverses abdominis muscle, were identified. A 100mm, 22 gauge.

Stimuplex block needle was then guided, in plane, to a point just inferior to the right costal margin at the anterior axillary line such that the tip lay between the transverses abdominis and internal oblique muscle within the neurovascular muscular fascial plane.

Following aspiration, 20ml of the cocktail study drug, 40 ml of 0.25% bupivacaine + 10 mcg dexmedetomidine was injected between the rectus abdominis and transverses abdominis muscles along the subcostal line.

The same procedure was repeated on the opposite side.

*Evaluation of Pain:* The visual analogue scale, which is a uni-dimensional measure of pain intensity, was used for the assessment of post-operative pain in both groups. It is a horizontal line on which the patient's pain intensity is represented by a point between the extremes of "no pain at all" and "worst pain imaginable". Patients selected a whole number to describe the intensity of their pain, which were recorded at the post-operative 15th min, 30th min, 60th min, 2nd hour, 6th hour, 12th hour and 24th hour by an anesthesiologist who was blinded to the group allocations.

The time of first analgesic requirement in the first 24 hours was documented.

## OBSERVATION AND RESULTS

The study was done on 40 patients belonging to ASA class I and II under going elective laparoscopic cholecystectomy.

The patients were categorized into 2 groups.

*Group E:* Patients in the ESP block group receiving 40ml 0.25% bupivacaine + 10 mcg of dexmedetomidine, bilaterally at T7 and T9 level (10 ml of the cocktail study drug on each side at T7 and T9 level).

*Group S:* Patients received SCTAP block with a sub costal approach, 40 ml of 0.25% bupivacaine + 10 mcg dexmedetomidine, 20ml of the cocktail study drug was injected bilaterally.

*Statistical analysis:* All the data were recorded in a Microsoft excel sheet and then transferred to SPSS-24 Software (statistical package for social sciences) for analysis.

Continuous data were represented as mean and standard deviation and ANOVA (repeated measures) was done for pain scores using VAS, followed by LSD multiple comparison analysis. The categorical data, represented as frequency and

percentages, were analyzed by Chi-square test. The P value <0.05 was considered significant.

**Table 1:** Mean comparison of age between the groups

Parameters	Group E	Group S	p value
Mean age in years ± SD	40.94±10.876	43.17±13.129	0.442

On comparison of the age, there was no significant difference between the groups (p=0.442).

**Table 2:** Gender distribution between the groups

Parameters	Male	Female
Group E	3	17
Percentage	15%	85%
Group S	7	13
Percentage	35%	65%
Total	10	30
Percentage	25%	75%

The percentage of males and females was similar in both groups

**Table 3:** Mean weight comparison between the groups

Parameters	Group E	Group S	p value
Mean weight in kgs ± SD	59.46 ± 3.936	61.20 ± 6.712	0.190

There was no significant difference in the weight distribution between the groups (p=0.190)

**Table 4:** VAS score sat 15th min

Parameters	Group E	Group S	p value
VAS at 15 Minutes	1.54 ± 1.039	0.26 ± 0.443	0.000

Pain scores using VAS showed significantly (p<0.000) less scores in Group-E when compared with Group-S.

**Table 5:** VAS scores at 30 min

Parameters	Group E	Group S	p value
VAS at 30 Minutes	1.80 ± 0.868	0.97 ± 0.822	0.000

Pain scores using VAS at 30 minutes showed significantly (p<0.000) less scores in Group-E when compared with Group-S

**Table 6:** VAS scores at 60 min

Parameters	Group E	Group S	p value
VAS at 60 Minutes	1.57 ± 0.739	1.14 ± 0.845	0.027

Pain scores using VAS at 2 hours showed significantly (p<0.027) less scores in Group-E when compared with Group-S

**Table 7:** VAS scores at 2 hours

Parameters	Group E	Group S	p value
VAS at 2 hours	1.69 ± 0.718	1.37 ± 0.808	0.090

Pain scores using VAS at 2 hours shows no significance (p<0.090)

**Table 8:** VAS scores at 6 hours

Parameters	Group E	Group S	p value
VAS at 6 hours	2.29 ± 0.825	1.31 ± 0.900	0.000

Pain scores using VAS at 6 hours showed significantly ( $p < 0.000$ ) less scores in Group-E, when compared with Group-S.

**Table 9:** VAS scores at 12 hours

Parameters	Group E	Group S	p value
VAS at 12 hours	2.49 ± 0.702	2.14 ± 0.974	0.096

Pain scores using VAS at 12 hours shows no significance ( $p < 0.096$ ) between the study groups.

**Table 10:** VAS scores at 24 hours

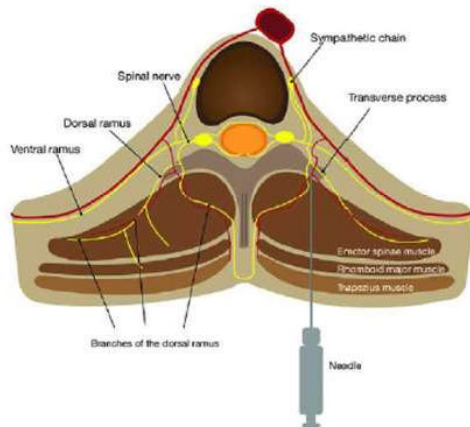
Parameters	Group E	Group S	p value
VAS at 24 hours	3.230.690	2.510.562	0.000

Pain scores using VAS at 24 hours showed significantly ( $p < 0.000$ ) less scores in Group-E when compared with Group-S

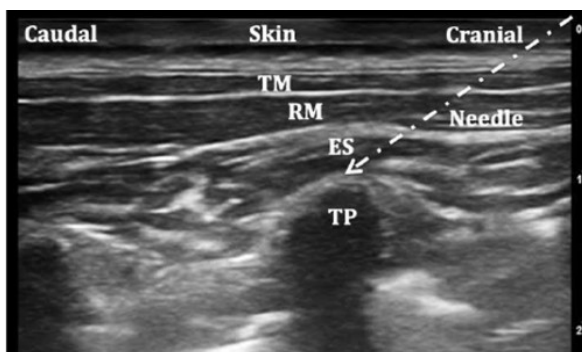
**Table 11:** Need for rescue analgesia

Rescue Analgesia	Group E	Group S
Yes	8.6%	28.6%
No	91.4%	71.4%

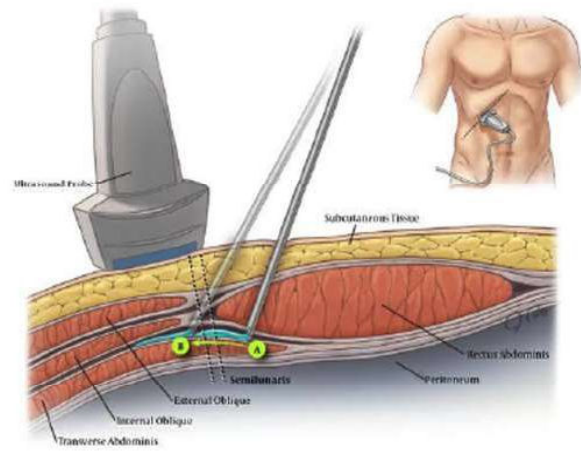
The need for rescue analgesia was less in Group-E when compared with Group-S.



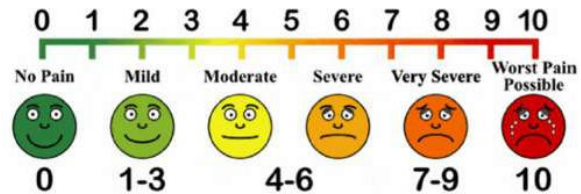
**Fig. 1:** Anatomical Representation of Deposition of Study Drug



**Fig. 2:** Tp: Transversus Process, ES: Erector spinae muscle, RM: Rhomboid major muscle, TM: Trapezius muscle.



**Fig. 3:** EO: External oblique, IO: Internal oblique, TAM: transversus abdominis muscle (right), needle insertion in plane to the probe from lateral side



**Fig. 4:** Visual analogue scale

## DISCUSSION

Laparoscopic cholecystectomy is one of the most common, minimally invasive surgical procedures for removal of a diseased gallbladder. This technique essentially has replaced the open technique for routine cholecystectomies since the early 1990s. Laparoscopic cholecystectomy is indicated for the treatment of cholecystitis (acute/chronic), symptomatic cholelithiasis, biliary dyskinesia, acalculous cholecystitis, gallstone pancreatitis, and gallbladder masses/polyps.<sup>2</sup>

Laparoscopic surgery has approved advantages over open surgical procedures, including reduction in post-operative pain and opioid requirements due to smaller surgical incisions, less impairment of pulmonary function resulting from splinting, decreased incidence of ileus and respiratory depression, and to reduction in the potential for prolonged wound healing and wound dehiscence, but with limitations of inability to tolerate pneumoperitoneum or general anesthesia, uncorrectable coagulopathy.<sup>3</sup>

Following nausea and vomiting, pain is the most common reason for longer duration of hospital admission after laparoscopic surgery, overall pain is a consolidate of three different and clinically



separate components: Incisional pain (somatic pain), visceral pain (deep intra abdominal pain), and shoulder pain (presumably referred visceral pain).<sup>4</sup>

The anatomy of the peritoneum is complex and must be understood for a proper understanding of the pain associated with laparoscopic surgery. The differing embryologic origins of the parietal and visceral layers of the peritoneum give rise to distinct pain sensations. The parietal and visceral peritoneal linings have distinct embryologic origins and, therefore, differing innervation.<sup>5</sup>

The parietal peritoneum is derived from the soma to pleural layer and is sensitive to pain, pressure, touch, friction, cutting and temperature. It is innervated by the phrenic nerves and by the sensitive spinal (lower thoracic) nerves. The anterior and lateral surfaces of the diaphragmatic peritoneum receive sensitive branches from the intercostal nerves 6–8. In contrast, the central part of the diaphragm receives a sensitive branch from the phrenic nerve (C3-C5) and has a bilateral innervation by neurons from no dose and cervical dorsal root ganglia. The remaining parietal peritoneum receives sensory nerves only from the (ipsilateral) dorsal root ganglia, and not from the vagus nerve. This innervation has the same segmental arrangement as the corresponding dermatomes (T6-T12) thus, is innervated by the associated dermatomes.

Conversely, the visceral peritoneum is derived from the splanchnopleural layer and receives sensory nerves from the spinal nerves. However, in addition to the parietal peritoneum, the visceral peritoneum also receives innervation from the vagus nerve.<sup>6</sup>

Post cholecystectomy pain has high inter individual variability in intensity and duration and is largely unpredictable, being most intense on the day of surgery and on the following day and subsequently declines to low levels within 3–4 days.<sup>4</sup> NSAIDs or COX-2 inhibitors are recommended for routine use in patient sunder going laparoscopic cholecystectomy. Treatment should be initiated shortly before or at in duction of anesthesia or during surgery and continued for 3–4 days.

Local anesthetics prevent transmission of nerve signals from the trauma site to the spinal cord by blocking Na<sup>+</sup> current, there by reducing neurogenic local inflammation at the trauma site.<sup>7</sup>

Studies support use of local anesthetics at all trocar incisions, whereas routine use of intraperitoneal local anesthetics cannot be

recommended, because of the low study quality in many trials and conflicting results.<sup>4</sup>

Opioids reduce pain by acting as agonists at opioid receptors or at presynaptic and postsynaptic sites in the central nervous system (CNS). They decrease local inflammation at the trauma site and in the dorsal horn by decreasing neurotransmission in presynaptic area. Though opioids remain the main stay of modern perioperative care and pain management, its analgesic properties in the treatment of acute, intense post-operative pain after major and minor surgery are well accepted. However, to hasten recovery and minimize opioid related side effects (somnolence and sedation, nausea and vomiting, sleep disturbances, urinary retention, and respiratory depression), prophylactic use of opioids in post-operative pain is avoided.<sup>4,7</sup> Hence clinicians are seeking novel modalities to decrease post-operative opioid requirements and their associated side effects such as nausea and decreased bowel motility. These adverse effects delay recovery after surgery, increasing length of stay, and costs to the health care system while worsening patient satisfaction. Other drugs, such as NSAIDs or COX-2 inhibitors, incisional local anesthetics, and steroids have been shown to have valuable opioid sparing effects.<sup>4</sup>

Epidural local anesthetics work by blocking afferent nerve activity at the spinal level. Epidural analgesia and intrathecal local anesthesia/morphine probably provide effective control of pain after laparoscopic cholecystectomy. However, these invasive techniques cannot be commended as routine in laparoscopic cholecystectomy, because of the potential risks.<sup>4</sup> The development of enhanced recovery after surgery (ERAS) protocols and robotic techniques for laparoscopic surgery has propelled regional techniques to a new prominence. Regional anesthetics for abdominopelvic surgeries fall broadly into two categories, neuraxial blocks and peripheral blocks. Neuraxial blocks include intrathecal or epidural administration of opioid or local anesthetic and para vertebral blocks with local anesthetic. Although individual nerves have been targeted for abdominal regional anesthesia, peripheral blocks of the abdominal and pelvic analgesia usually are generally “plane blocks.” Instead of injecting local anesthetic directly around a target nerve as with conventional peripheral nerve blocks, plane block utilizes a large volume of more diluted local anesthetic to infiltrate a plane the targeted nerves traverse.

Based on the local anesthetic used, neuraxial blocks can produce surgical anesthesia and dense

post-operative analgesia.<sup>4</sup> Though continuous infusion via thoracic or lumbar epidural provides excellent analgesia following laparoscopic surgery, they are associated with numerous disadvantages. Mainly continuous monitoring for associated risks like profound hypotension, epidural abscess, and hematoma resulting in spinal cord compression and requiring in patient hospital admission. Hence epidural analgesia is reserved for major surgeries requiring hospital admission for pain management, reducing the need for opioids and enhancing recovery.<sup>8,4</sup>

The transverses abdomen is plane (TAP) is the fascial plane superficial to the transverses abdominis muscle. Transversus abdominis muscle is deep to the internal oblique muscle, it ends as anterior aponeurosis, which lies posterior to the rectus abdominis muscle and reaches the xiphoid process. The posterior aponeurosis of the transverses abdominis and internal oblique muscles fuse and attach to the thoracolumbar fascia (TLF). In the TAP, the intercostal, sub costal, and L1 segmental nerves communicate to form the upper and lower TAP plexuses, which innervate the anterolateral abdominal wall, including the parietal peritoneum.<sup>6</sup>

The sub costal approach to the TAP nerve block ideally anesthetizes the inter costal nerves T6-T9 between the rectus abdominis sheath and the transverses abdominis muscle, where the epigastric port of laparoscope is inserted for which the block is required to be given at a more anterior level. TAP nerve blocks provide somatic analgesia of the abdominal wall including the parietal peritoneum.<sup>9</sup> Though various comparative studies, it is concluded that by using subcostal approach of transverses abdominis plane block in conjunction with the multimodal analgesia in patient under going laparoscopic cholecystectomy, provides satisfactory post-operative analgesia can be achieved which improves patient and surgical outcomes.<sup>10</sup>

The Erector Spinae Plane Block (ESP) is a novel regional technique for anesthesia or analgesia, which was originally described by Forero *et al.* in 2016, when it was used to treat thoracic neuropathic pain.<sup>12</sup> The "erector spinae" comprises a group of muscles including the iliocostalis, longissimus, and spinalis muscles, anterior to trapezius and rhomboids muscles.

They run bilaterally from the skull to the pelvis and sacral region, and from the spinous to the transverse processes, extending to the ribs.<sup>11,12</sup>

It is a paraspinous fascial plane block, where the

needle placement is between the erector spinae muscle and the thoracic transverse processes, and a local anesthetic is administered, blocking the dorsal and ventral rami of the thoracic and abdominal spinal nerves. This blockage of spinal nerves helps to achieve a multi-dermatomal sensory block of the anterior, posterior, and lateral thoracic and abdominal walls.<sup>13</sup>

ESP was hypothesized to be a multi-dermatomal sensory block due to the cranial and caudal spread of the injected local anesthetic. This spread is aided by the thoracolumbar fascia, which extends across the posterior thoracic wall and abdomen. The hypothesis was supported by Chinet demonstrating the cadaveric spread of local anesthetic, which was noted radiologically, the local anesthetic spread extended 3 or 4 levels cranially and caudally from the site of injection.<sup>14</sup>

In our study, the VAS score of post laparoscopic cholecystectomy patients in the ESP block group is significantly less compared to SCTAP group and the need for rescue analgesia was decreased in group E patients. These findings were supported by a study done in 2020 by Alshaimaa Abdel Fattah Kamel *et al.*, stating bilateral ultrasound guided ESP block provides more potent and longer post-operative analgesia with less morphine consumption than TAP block after open total abdominal hysterectomy.<sup>16</sup>

---

## CONCLUSION

---

Following development of enhanced recovery after surgery (ERAS) protocols (15), clinicians are seeking novel modalities to decrease post-operative opioid requirements and their associated side effects. We have observed that bilateral ultrasound guided ESP block was found to be superior to sub costal TAP block.

---

## REFERENCES

---

- Day Care vs Over night Stay after Laparoscopic Cholecystectomy even with Co-morbidity and a Possible Second Surgery: A Patient's Choice-A Swini Kumar Puj Ah Ari.
1. Laparoscopic Cholecystectomy-Hassler KR, Collins JT, Philip K, *et al.*
  2. Regional Anesthesia Techniques for Pain Management for Laparoscopic Surgery: a Review of the Current Literature -Alvaro Andrés Macías.
  3. Analgesic Treatment after Laparoscopic Cholecystectomy: A Critical Assessment of the Evidence - Thue Bisgaard, M.D., D.Sc.; David C.

- Warltier, M.D., Ph.D.
4. Peritoneal innervation: embryology and functional anatomy - Florian Struller, Frank-Jürgen Weinreich, [...], and Marc A.Reymond.
  5. Gray's Anatomy for Students - 3rd edition - chapter 4 page number 290.
  6. Stoelting's Pharmacology and Physiology in Anesthetic Practice - 5th edition- chapter 10 page number 284.
  7. Miller's Anaesthesia.
  8. Ultrasound-Guided Transversus Abdominis Plane and Quadratus Lumborum Nerve Blocks - Hesham Elsharkawy and Thomas F. Bendtsen - <https://www.nysora.com/topics/regional-anesthesia-for-specific-surgical-procedures/abdomen/ultrasound-guided-transversus-abdominis-plane-quadratus-lumborum-blocks/>.
  9. Analgesic Effect of Bilateral Subcostal Tap Block After laparoscopic cholecystectomy-Karimakaram khan, Robynairshad khan department of anaesthesiology, The Aga Khan University Hospital.
  10. Erector Spinae Plane Nerve Block-<https://www.nysora.com/erector-spinae-plane-block/>.
  11. Erector spinae plane block for post-operative analgesia in laparoscopic cholecystectomy: a case report - Dimosthenis Pets as.
  12. Erector Spinae Plane Block - Krishnan S, Cascella M.
  13. ChinKJ, Adhikary S, Sarwani N, Forero M.Theanalgesic efficacy of pre-operativebi lateral erector spinae plane (ESP) blocks in patients having ventral hernia repair. Anaesthesia. 2017 Apr;72(4):452-460.
  14. Enhanced Recovery in Laparoscopic Cholecystectomy (ERLAC).
  15. Bilateral Ultrasound-Guided Erector Spinae Plane Block Versus Transversus Abdominis Plane Blockon Postoperative Analgesia after Total Abdominal Hysterectomy-Alshaimaa Abdel Fattah Kamel-2020.

