

## Anaesthetic Management of Patient with Spinal Muscular Atrophy Posted for Feeding Gastrostomy under General Anaesthesia

Akhil Kumar<sup>1</sup>, Ravi M<sup>2</sup>, Kiran N<sup>3</sup>

### How to cite this article:

Akhil Kumar, Ravi M, Kiran N. Anaesthetic Management of Patient with Spinal Muscular Atrophy posted for Feeding Gastrostomy under General Anaesthesia. Ind J Anesth Analg. 2024; 11(3):143-146.

### Abstract

**Introduction:** Spinal Muscular Atrophy (SMA) is a genetic disorder impacting approximately 1 in 10,000 individuals. It manifests across varying degrees of severity. Generally, the disease's onset at an earlier age corresponds to more pronounced symptoms, such as difficulty with swallowing, breathing, etc. A present case of a two-year-old male child diagnosed with SMA type 2 was planned for feeding gastrostomy under general anesthesia. This case report highlights how awareness of this rare ailment can facilitate early identification, empower parents to seek genetic counseling and help prevent potential complications.

**Case Report:** A 2-year and 10-month-old male child was brought with cough, cold and shortness of breath persisting for three days. Medical history reveals that he had SMA type 2 and underwent Zolgensma. Provisional diagnosis of SMA type2/ bronchopneumonia with respiratory distress was made.

His treatment commenced with oxygen support via nasal prongs, IV antibiotics Inj. Collistin 75K/kg/day TID, Inj. Fluconazole 100 mg iv OD, Nebu Asthalin, Nebu Budecort nebulization. Following day, i/v/o respiratory distress, he was connected to high-flow nasal cannula support. The antibiotics regimen was adjusted to include increased doses of PIPTAZ syrup azithromycin and oseltamivir.

He was premedicated with Inj. Glycopyrrolate, Inj. Midazolam and Inj. Fentanyl and pre-oxygenation with 100% oxygen and intubated with 4mm uncuffed endotracheal tube and shifted to the OT. Anesthesia was induced with sevoflurane and maintained with a combination of nitrous oxide and oxygen. Skeletal muscle relaxation atracurium was given. The pediatric surgeon performed gastrostomy by inserting MIC-KEY Tube of 12FR through the anterior abdominal wall into the stomach. Throughout the procedure, his hemodynamic parameters remained stable and was transferred to the Pediatric ICU with Ambubag and ET tube ventilation and then transitioned to mechanical ventilator support. Postoperative recovery was uneventful.

**Conclusion:** Individuals with SMA can effectively be administered with general anesthesia, using muscle relaxants and inhalation anesthetics. Addressing specific concerns and ensuring

**Author's Affiliation:** <sup>1</sup>Junior Resident, <sup>2,3</sup>Professor, Department of Anaesthesiology, Sri Devaraj Urs Medical College Tamaka, Kolar 563103, Karnataka, India.

**Corresponding Author:** Ravi M, Professor, Department of Anaesthesiology, Sri Devaraj Urs Medical College Tamaka, Kolar 563103, Karnataka, India.

**E-mail:** [ravijaggu@gmail.com](mailto:ravijaggu@gmail.com)

**Received on:** 28.03.2024 **Accepted on:** 27.09.2024

access to advanced airway and imaging equipment are pivotal for safely managing anesthesia in this specialized patient cohort.

**Keywords:** Feeding Gastrostomy; General Anesthesia; Spinal Muscular Atrophy.

**Key Messages:** Gastrostomy surgery for children's with spinal muscular atrophy can significantly improve nutritional intake, weight gain and overall quality of life by providing a safer and more efficient



way to deliver nutrition and medication the anesthesia management of post gastrostomy patients is to ensure careful airway management due to the risk of aspiration, monitor fluid balance and consider the delayed gastric emptying when administering medications.

## INTRODUCTION

Spinal muscular atrophies (SMAs) are a group of inherited disorders characterized by motor neuron loss in the spinal cord and lower brainstem, muscle weakness and atrophy. The inheritance of SMA related to chromosome 5q follows an autosomal recessive pattern. Its incidence stands between 4 to 10 cases per 100,000 live births, with a higher prevalence of carriers of the survival motor neuron1 (SMN1) mutation causing the disease, ranging from 1 in 47 individuals to as frequent as 1 in 90.<sup>2</sup>

SMA should be considered as a potential diagnosis for infants displaying unexplained weakness or hypotonia. Confirmation of the condition often involves molecular genetic testing. Additionally, electromyography may reveal abnormal spontaneous activity characterized by fibrillations and positive sharp waves.<sup>3</sup> Dysphagia and exhaustion during feedings can cause failure to thrive, exacerbating weakness. If oral feeding are continued, aspiration pneumonia could develop. Continuation of oral feeding under these conditions might elevate the risk of developing aspiration pneumonia. Consequently, many patients may benefit from feeding gastrostomy procedures.<sup>2,3</sup>

A comprehensive, multidisciplinary approach is pivotal in managing individuals with SMA. Monitoring various facets influencing disease progression and offering anticipatory care whenever feasible is crucial in SMA management.<sup>4</sup> The present case has also highlighted the significance of a multidisciplinary approach and successful perioperative management in a patient scheduled for gastrostomy.

## CASE REPORT

A 2-year 10-month-old male child with a known case of SMA type 2 brought with a chief complaint of cough and cold persisting for three days, accompanied by shortness of breath for the last day. The past medical history of the child reveals that the child was diagnosed with SMA type 2 at one year and two months through MLPA test.

Additionally, the child underwent gene therapy (Zolgensma) in March 2022. Upon admission to the hospital, the child presented with tachypnea and tachycardia. System examination revealed rhonchi, mild subcostal retractions, hypotonia and areflexia of all limbs. A provisional diagnosis of k/c/o spinal muscular atrophy type 2/bronchopneumonia with respiratory distress was made. Given that the patient was under 18 years old, the patient's mother provided written informed consent to allow the publication of the case details for future academic purposes.

**Anesthetic Management:** The child's treatment plan commenced with oxygen support via nasal prongs, IV antibiotics Inj. Collistin 75K/kg/day TID, Inj. Fluconazole 100 mg iv OD, Nebu Asthalin, Nebu Budecort nebulization and other supportive measures. On day 2 of admission, i/v/o respiratory distress, the child was connected to high-flow nasal cannula (HFNC) support. The antibiotics regimen was adjusted to include increased doses of PIPTAZ syrup azithromycin and the addition of oseltamivir.

The child was premedicated with Inj. Glycopyrrolate, Inj. Midazolam and Inj. Fentanyl and pre-oxygenation with 100 percent oxygen. The patient was intubated with a 4 mm uncuffed

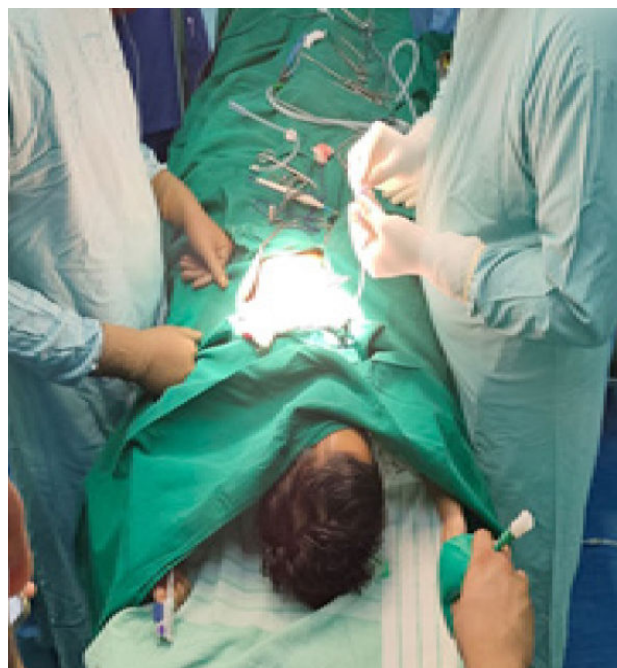

Fig. 1: Intraoperative Gastrostomy

endotracheal tube and fixed after confirming the chest rise and equal air entry in lung fields. Following intubation, the child was connected to an Ambu bag and started tube ventilation.

The child was shifted to the operation theatre by bagging with oxygen. Anaesthesia was induced with

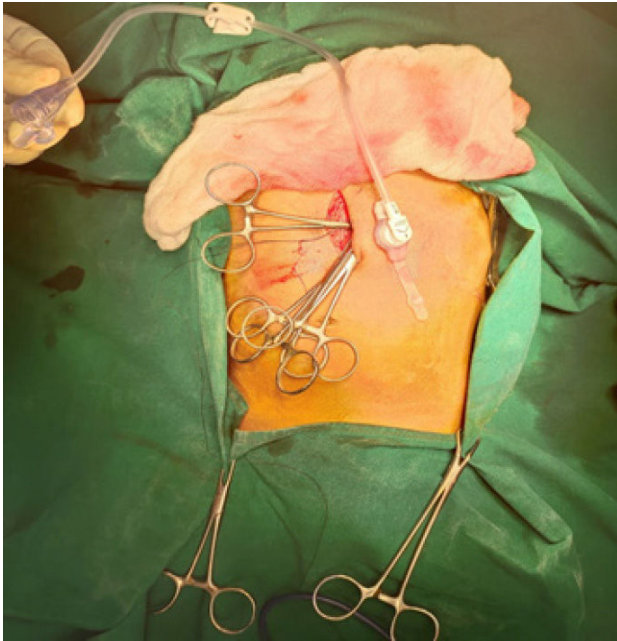


Fig. 2: Post Operative Gastrostomy

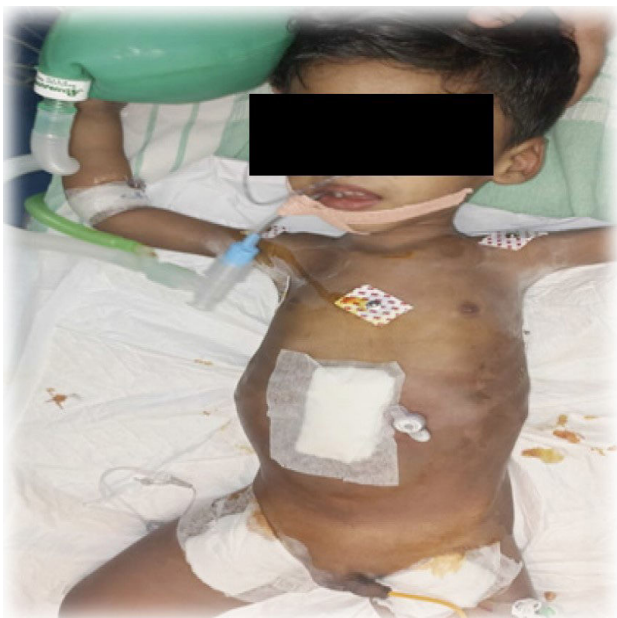

Fig. 3: Post Operative ICU

sevoflurane and maintained with a combination of nitrous oxide and oxygen. Skeletal muscle relaxation atracurium was given. The pediatric surgeon performed a gastrostomy by identifying

the stomach and inserting a MIC-KEY Tube of 12 FR through the anterior abdominal wall into the stomach. Throughout the procedure, the child's hemodynamic parameters remained stable. The process lasted approximately 60 minutes, during which intravenous fluids were administered. Following the procedure, the child was transferred to the Pediatric Intensive Care Unit (PICU) with Ambu bag and ET tube ventilation and then transitioned to mechanical ventilator support. Postoperative recovery was uneventful.

## DISCUSSION

Spinal muscular atrophy encompasses a set of inherited conditions leading to progressive muscle degeneration and weakness. This condition is categorized into four types, dependent on the age of onset and the severity of symptoms. Type II, or intermediate SMA or Dubowitz disease, typically manifests before a child achieves independent standing or walking, occurring between 3 and 15 months of age. In this type, muscle weakness predominantly affects the lower limbs more than the upper limbs.<sup>3</sup>

Children diagnosed with SMA often require anaesthesia for both diagnostic tests and surgical procedures. Various anaesthetic techniques are employed, ranging from total intravenous anaesthesia to regional anaesthesia, along with a diverse range of intubation techniques and equipment. While each method has shown both success and failure, there is a lack of evidence-based advice or established guidance for anaesthetic management specific to this patient group.<sup>4</sup>

The surgical and anesthesia teams should consider the potential need for perioperative total parenteral nutrition (TPN) and non-invasive positive pressure ventilation (NIPPV). It is crucial to anticipate challenges such as difficult intubation, longer-than-usual anesthesia durations and extended stays in intensive care, particularly for patients diagnosed with SMA types I and II.<sup>9</sup>

According to Massucato *et al.* (2015), a 3-year-old girl was diagnosed with SMA type 2 at 6 months of age, with difficulty keeping seated. She showed generalized hypotonia and respiratory pathologies similar to those in our patient. In contrast, she experienced severe atrophy of the muscles. In another case of a 4-year-old boy with SMA type 2 had an apparent musculoskeletal abnormality, bilateral superior rib cage decrease and scoliosis, which were impairing his ability to breathe. In

another case, a 2-year-old boy underwent open fundoplication and gastrostomy, resembling the current case's management. However, unlike the present scenario, this child encountered respiratory problems on the 5th postoperative day (POD) attributed to a chest infection. The condition was addressed with oxygen and antibiotics, leading to discharge on the 10<sup>th</sup> POD.<sup>8</sup>

This case report illustrates that through the implementation of comprehensive multi-disciplinary care, children diagnosed with SMA undergoing gastrostomy can be safely and effectively managed throughout the perioperative phase.

## CONCLUSION

Individuals diagnosed with spinal muscular atrophy (SMA) can be effectively and safely administered general anesthesia utilizing muscle relaxants and inhalation anesthetics. Optimal care for these patients necessitates a multidisciplinary approach tailored to their unique needs. Addressing specific concerns and ensuring access to advanced airway and imaging equipment are pivotal for safely managing anesthesia in this specialized patient cohort.

**Conflict of Interest:** *NIL*

## REFERENCES

1. Farrar MA, Kiernan MC. The genetics of spinal muscular atrophy: Progress and challenges. *Neurotherapeutics*. 2015;12:290-302.10.1007/s13311-014-0314-x.
2. Harris SJ, Moaz K. Caesarean section conducted under subarachnoid block in two sisters with spinal muscular atrophy. *Int J ObstetAnesth*. 2002;11:125-7.10.1054/ijoa.2001.0911.
3. Arnold WD, Kassam D, Kissel JT. Spinal muscular atrophy: Diagnosis and management in a new therapeutic era. *Muscle Nerve*. 2015;51:157-67.10.1002/mus.24497.
4. Davidson JE, Farrar MA. The changing therapeutic landscape of spinal muscular atrophy. *Aust J Gen Pract*. 2022;51:38-42. 10.31128/AJGP-03-21-5924.
5. Islander G. Anesthesia and spinal muscle atrophy. *PaediatrAnaesth*. 2013;23:804-16. 10.1111/pan.12159.
6. Prior TW, Leach ME, Finanger E. Spinal muscular atrophy. *GeneReviews*. Adam MP, Ardinger HH, Pagon RA, *et al.* (ed): University of Washington, Seattle; 2019.
7. Halanski, Matthew MA, Steinfeldt, *et al.* Perioperative management of children with spinal muscular atrophy. *Indian J Anaesth*. 2020;64(11):931-36. 10.4103/ija.IJA\_312\_20.
8. Massucato BS, Cognette RC, Barroti LC, Godoy AJ: Spinal muscular atrophy type 2, a case report. *J Neurol Sci*. 2015, 357:E344. 10.1016/j.jns.2015.08.1222
9. Case study: 4-year-old with spinal muscular atrophy type 2. (2019). Accessed: October 10, 2023: <https://www.chop.edu/news/case-study-4-year-old-spinal-muscular-atrophy-type-2>.
10. Thomas DE; Sebastian, Geethu, *et al.* Anesthetic management of a child with spinal muscular atrophy. *Amrita J Med*. 2023;19:147-9. 10.4103/AMJM.AMJM\_44\_23.