Case Report

Indian Journal of Anatomy
Volume 12 Number 3, July – September 2023
DOI: http://dx.doi.org/10.21088/ija.2320.0022.12323.3

Injectable Method of Emblaming in Case of Non-availability of Machine or in Cadaver Rejecting Infusion: A Novel Study

Kalasapakam Vijay Ananth

How to cite this article:
Kalasapakam Vijay Ananth/Injectable Method of Emblaming in Case of Non-availability of Machine or in Cadaver Rejecting Infusion: A Novel Study J Anat. 2023;12(3):119-120.

Abstract

Introduction: It was accidental study in a cadaver which was donated to the Institute for study purpose but the cadaver rejected the traditional method of gravity based infusion into the major arteries like Femoral in the thigh.

So, to save the Cadaver from decomposition injection of Raw Formaldehyde was done via syringe of 10 ml into the various areas of the soft parts of the body.

Keywords: Cadaveric Body; Donated Body; Study Purpose; Syringe; Formaldehyde.

INTRODUCTION

The Method of Embalming of Human Body its procedure as old in article[1] and the other aspects discussed in[3] with the modern methods was applied as mentioned.[2]

Our Institute was not housing the Embalming Machine as it was following a traditional method of gravity based infusion the Can the catheter tube and a copper cannula.

Author's Affiliation: Associate Professor, Department of Anatomy, National Institute of Homeopathy, Kolkata 700106, West Bengal, India.

Corresponding Author: Kalasapakam Vijay Ananth, Associate Professor, Department of Anatomy, National Institute of Homeopathy, Kolkata 700106, West Bengal, India.

E-mail: vjananth74@gmail.com

Received on: 30.05.2023

Accepted on: 28.07.2023

© Red Flower Publication Pvt. Ltd.

Caution: Care was taken not to mix water with the Formaldehyde because the body on and average possesses high water content which only aid in decomposition not preservation so avoided it completely.

MATERIALS AND METHODS

A Cadaver was received from the free donation with due formalities into the Department of Anatomy few years back. It was soon found out that during embalming the cadaver started to reject the infusion (the fluid couldn't enter) when tried with the traditional method of gravity based infusion the Aluminum can the Catheter tube and a copper cannula attached to it. So, in this current scenario I had to go for the only alternative to preserve the cadaver me and my attendant Dom started giving injection of Formaldehyde which was done via syringe of 10 ml into the various areas of the soft parts of the body. Here leaving the skull and bones of leg we started to inject propositional every area such as the muscular sites (face, neck, shoulders,

arms and pelvis, popliteal, plantar) and in the abdomen the peritoneal area and the soft parts such as the liver, spleen. Also it was applied to the thorax between the intercostal area reaching the lungs, heart the mediastinum and the Diaphragmatic area. Though calculation was not done but a quantity of 4 liters was injected the Cadaver swelled with the injected fluid.

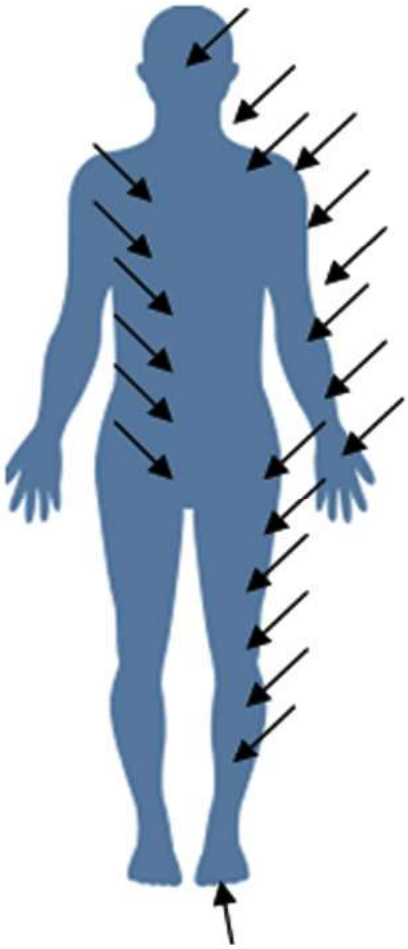

Fig. 1: Descriptive positions as arrows are shown for the injectable sites.

After that the cadaver was left for two days and after the fluid is absorbed into the system it is then put in the tank containing formaldehyde and other preservatives as per the norms.

Note: I rather not suggest to go for such methods as it posses direct exposure to the Raw formaldehyde resulting in irritation of the mucous membranes of eyes and nose. But in the present world when donated dead bodies are extremely rare so to simply throwing it away is not ethically correct. But I suggest if necessary go for APR full face masks and do the procedure.



Fig. 2: The human cadaver after injecting the raw formaldehyde



Fig. 3: The human cadaver after two days of injecting the raw formaldehyde the fluid absorbed

CONCLUSION

By this above method we could obtain a Embalmed Cadaver which did posses all the normal embalming procedures which included the well preserved viscera and other structures.

REFERENCES

1. Susan Parsons, Preserving the Union: a History of Modern Embalming.
2. Erin L. Wilcox, Embalming: Diseases and Conditions 3 CE Hours. *Funeral Service Academy* Embalming - Diseases & Conditions, Pg 1-25.
3. Bajracharya S, Magar A, Embalming an art of preserving Human Body, Kathmandu University Medical Journal (2006), Vol 4, No. 4, Issue 16, 554-557.