Review Article

Indian Journal of Anatomy
Volume 12 Number 3, July – September 2023
DOI: http://dx.doi.org/10.21088/ija.2320.0022.12323.2

Recent Advances in Management of Brachial Plexus Injury

Amrutha JS[1], Ravi Kumar Chittoria[2]

How to cite this article:

Amrutha JS, Ravi Kumar Chittoria / Recent Advances in Management of Brachial Plexus Injury / Indian J Anat. 2023; 12(3):109-116.

Abstract

Brachial plexus injury resulting in variable degrees of neurapraxia and axonotmesis may potentially recover spontaneously, whereas axonotmetic or neurotmetic injuries resulting in neuromas-in-continuity, nerve root ruptures, or nerve root avulsions will not. Along with clinical evaluation, various investigation like MRI, CT Myelography, USG and electrodiagnostic methods are there. The treatment of injury includes nerve transfers, nerve grafts and muscle transfers. This article discuss about newer developments of diagnostic evaluation and management of brachial plexus injury.

Keywords: Brachial Plexus; Recent; Advances; Nerve Grafting; Neurotisation.

INTRODUCTION

The pericardium The brachial plexus is formed by the ventral rami of C5 to T1 nerve roots. It is composed of:

1. *Roots:* The five spinal nerves C5, C6, C7, C8, and T1.
2. *Trunks:* Upper (C5-C6), middle (C7) and lower (C8-T1) trunks.
3. *Divisions:* Each trunk divides into anterior and posterior divisions.
4. *Cords:* The divisions recombine to form lateral, posterior, and medial cords.
5. *Branches:* From the cords peripheral nerves arise.

Injuries resulting in variable degrees of neurapraxia and axonotmesis may potentially recover spontaneously, whereas axonotmetic or neurotmetic injuries resulting in neuromas-in-continuity, nerve root ruptures, or nerve root avulsions will not recover easily.

Pre-Operative Evaluation

Clinical

Evaluation of Movements:

1. Direct measurements:

- Degrees of active range of motion (ROM).
- Hospital for Sick Children Active Movement Scale (AMS).

2. Subjective assessments of strength

- Medical Research Council (MRC) score.

Author's Affiliation: [1]Senior Resident, Department of Plastic Surgery, [2]Professor, Head of IT Wing, Department of Plastic Surgery and Telemedicine, Jawaharlal Institute of Postgraduate Medical Education & Research, Pondicherry 605006, India.

Corresponding Author: Ravi Kumar Chittoria, Professor, Head of IT Wing, Department of Plastic Surgery and Telemedicine, Jawaharlal Institute of Postgraduate Medical Education & Research, Pondicherry 605006, India.

E-mail: drchittoria@yahoo.com

Received on: 31.07.2023

Accepted on: 05.09.2023

© Red Flower Publication Pvt. Ltd.

3. Composite movement scores

- Mallet scale for shoulder function.
- Raimondi score for hand function.
- Toronto Test Score.

The AMS determines total active ROM relative to passive ROM on a seven point ordinal scale for a specific movement, both against gravity and with gravity eliminated. The AMS does not require the patient to follow commands, allows for extended statistical analysis, has excellent interrater reliability, and has been validated when used as a composite score (Toronto Test Score) to predict which patients would benefit from surgical intervention. Motor functions in degrees of active ROM should be documented at ages 1,3,6, and 9 months: external rotation (with arm adducted), shoulder abduction, elbow flexion, wrist extension, finger flexion, and finger extension.[1]

Asymmetry of the soft tissue folds near the axilla, apparent shortening of the humeral segment, and an internally rotated resting posture can be seen.[5] Passive ROM for shoulder external and internal rotation should be assessed with the arm adducted and abducted. Examination may reveal tightness of the internal rotators (pectoralis major, latissimus dorsi, teres major, subscapularis) or posterior fullness caused by a posteriorly displaced humeral head.

Imaging

Computed tomographic myelography or magnetic resonance imaging (MRI) may be useful for evaluating suspected nerve root avulsion. Computed tomography myelography has been the imaging modality of choice to detect root avulsions, which are indicated by the presence of pseudomeningoceles. However, this type of imaging is limited by its invasive nature and inability to further characterize a nerve injury.

Magnetic resonance neurography can provide high-resolution images at the fascicle level. It allows detection of neuromas, perineural scarring, and pathologic fluid shifts. Magnetic resonance neurography also helps characterize the integrity of surrounding structures and distinguish between acute and chronic denervation changes. MRI is noninvasive and nonionizing, and newer rapid sequence protocols may enable image capture without anesthesia or sedation in infants.[2]

MRI tractography, which quantifies the longitudinal diffusivity of water molecules in a nerve segment to generate high resolution images of peripheral nerve tracts.[3,4] It can noninvasively monitor progressive nerve regeneration radiographically.

In addition to neurologic recovery, serial evaluation of the shoulder is crucial in children with BPBI. As a result of muscle denervation, incomplete reinnervation, and impaired longitudinal muscle growth, soft tissue imbalances commonly arise around the shoulder and may progress to an internally rotated shoulder posture with posterior humeral head instability and subluxation or dislocation, and aberrant glenohumeral joint development including glenoid retroversion.[6-8] This pathologic development of the shoulder joint is termed glenohumeral dysplasia.

Although ultrasonography is the preferred screening test in BPBI, MRI remains the standard for comprehensive glenohumeral joint evaluation and surgical decision making.[10] The severity of glenohumeral dysplasia is graded by the Waters classification (Table 1), which progresses from minimal posterior glenoid deformity to humeral head subluxation and the development of a false glenoid, to flattening of both the glenoid and humeral head.

Table 1: Water's Classification

Classification	Description
Type I (normal glenoid)	Less than 5^0 difference in retroversion between affected and unaffected glenoid
Type II (mild deformity)	More than 5^0 difference in retroversion between affected and unaffected glenoid
Type III (moderate deformity)	Posterior subluxation of humeral head. Less than 35% of head is anterior to scapular line
Type IV (severe deformity)	Presence of false glenoid
Type V	Severe humeral head and glenoid flattening with progressive or complete humeral head posterior dislocation
Type VI	Posterior humeral head dislocation in infancy
Type VII	Growth arrest of proximal aspect of humerus

Electrodiagnostic Tests

Electrodiagnostic studies aid in localizing injured elements of the plexus and inform the surgical reconstructive strategy. The disruption of sensory nerve action potentials suggests a postganglionic injury, whereas sensory nerve action potential preservation in clinically detected sensory deficit denotes preganglionic injury.

Electromyography (EMG) assessment helps in both the extent and severity of an injury. It can be done 3-4 weeks after an injury after Wallerian

degeneration has occurred. Denervated muscles show positive sharp waves and fibrillation potentials during the resting phase of EMG. The presence or absence of motor unit action potentials (MUAPs) during the recruitment phase of EMG is a key predictor of injury severity. Electromyography can also help identify candidate donors for nerve transfers, which is helpful for formulating reconstruction plans. In settings where healthy nerves are not available, injured but recovering nerves can be used as donors. The donor MUAP pattern indicates muscle recovery after a nerve transfer. The MUAP recruitment pattern is typically graded as full or normal, reduced, discrete, or absent (in order of increasing denervation). Donors with normal or reduced recruitment have been shown to be associated with better outcomes compared with those with discrete recruitment patterns.[51]

Nonsurgical Management of the Shoulder

Management goals for the shoulder include maintaining external rotation passive ROM, preserving glenohumeral joint integrity to clearance of the for earm from the chest during attempted active elbow flexion despite the presence of recovering elbow flexors.[9]

Non-surgical strategies for managing the shoulder abnormality include regular physiotherapy to preserve passive external rotation with scapular stabilization in adduction and abduction, targeting specific movements to strengthen weak muscles, and encouraging normal upper limb use and play. Early shoulder repositioning with splinting stretch tight muscles and maintain congruity of the glenohumeral joint, facilitating physiologic glenohumeral development in parallel with neuromuscular reinnervation and restoration of muscle balance.[11,12]

Botulinum toxin can temporarily weaken strong antagonist muscles and enable agonist muscles to be stretched and strengthened. Botulinum toxin helps in improving elbow flexion and improving shoulder external rotation are not sufficiently sustained over time to be of lasting clinical benefit,[13] and some still require secondary shoulder surgery.[14,15] By pharmacologically inhibiting protein degradation, longitudinal muscle growth may be restored and muscle contractures inhibited.

Treatment

Techniques of primary brachial plexus reconstruction can be broadly grouped into.

1. Neuroma excision with interposition nerve grafting and
2. Nerve transfers (neurotization) using proximal or distal donor nerves.

Post ganglionic, extraforaminal neurotmetic injuries (nerve root ruptures) are amenable to interpositional nerve grafting for axonal regeneration, whereas preganglionic, intra-foraminal neurotmetic injuries (nerve root avulsions) have loss of spinal cord continuity and are not. Based on the injury pattern and the availability of healthy nerves, these techniques may be used in combination to maximize neuromuscular reinnervation.[17] Neurolysis alone has been repeatedly shown to have no therapeutic benefit compared with the natural history of unoperated patients.[18-23]

Microsurgical Nerve Reconstruction

General indications for early surgical intervention (within 3 months of age).

- Evidence of T1 avulsion or Horner syndrome.
- Panplexus injury, or failed progression of spontaneous recovery.

For children with upper trunk injury and absent biceps function, early surgical intervention at 3 months of age may not result in better outcomes than the natural history of spontaneous biceps recovery. Thus, a slightly longer period of observation for failed recovery of elbow flexion at 6 to 9 months[16] is more commonly accepted as an indication for surgery in upper trunk injury.

Neuroma Excision and Interpositional Nerve Grafting

Neuroma excision and interpositional nerve grafting remains the standard for primary brachial plexus reconstruction of postganglionic (extraforaminal) nerve root ruptures. Families should be pre-emptively counselled about an initial down grade in motor function immediately after surgery but it is expected to return to pre-operative levels by 3 to 6 months, and an extended timeline for muscle reinnervation, averaging 30 months for shoulder external rotation, 17 months for elbow flexion, and 14 months for wrist extension.[24]

Distal Nerve Transfers (Neurotisation)

It include a single site of neurorrhaphy for axonal out growth, decreased axonal regeneration distance, decreased muscle reinnervation time and reduced technical complexity with shorter operative times.[25] Shorter reinnervation times enable nerve transfers to be performed at older

ages, for late presentations, or after failed primary reconstruction. Greater functional specificity with reduced axonal misdirection and synkinesis may also be achieved with distal nerve transfers, where intraneural topography is more clearly defined. Neuroma-in-continuity in the brachial plexus is not sacrificed with distal nerve transfers, thereby preserving functioning or spontaneously recovering motor units.[26]

Spinal Accessory-to-Suprascapular Nerve Transfer for Shoulder Function

The distal spinal accessory nerve (SAN) to suprascapular nerve (SSN) transfer is one of the most commonly used primary nerve transfers in upper trunk injuries to improve shoulder abduction and external rotation.[27-32] Unfortunately, although SAN-to-SSN transfer improves quantitative external rotation, not all children achieve clinically meaningful external rotation. Three years after SAN-to-SSN transfer, only 14% of BPBI children have external rotation greater than 20 degrees beyond the sagittal plane,[29] and several studies have independently demonstrated a mean external rotation AMS score of only 3 after SAN-to-SSN transfer.[28,31,33,34] Transfer of the SAN to the infraspinatus branch of the SSN has been described recently, in patients with congruent glenohumeral joints giving promising results.

Distal Nerve Transfers for Elbow Flexion

Distal ulnar and/or median fascicular nerve transfers to branches of the musculocutaneous nerve have shown reasonable outcomes for elbow flexion.[35] Compared with nerve grafting, distal fascicular nerve transfers for elbow flexion have not demonstrated clear superiority. Ulnar and/or median fascicular nerve transfer has demonstrated recovery of functional elbow flexion more rapidly, by a greater proportion of patients, and through a greater active ROM than nerve grafting.[36-38] In addition, for earm supination is improved with fascicular nerve transfer compared with nerve grafting, although differences between single versus double fascicular transfer are unclear.[36,37] Other upper limb functions may also benefit indirectly with fascicular nerve transfer from the availability of a greater length of nerve autograft for proximal nerve grafting. In by passing proximal nerve roots or trunks, distal nerve transfers do not restore anatomical continuity and leave thousands of proximal nerve fibers without targets. Unlike nerve graft reconstruction, partial cutaneous sensory recovery is not expected after distal nerve transfers of motor donors and recipients, and donor nerve morbidity with functional down grade is always a potential risk. Current indications of distal nerve transfer are included in Table 2.

Triple Nerve Transfer and Contralateral C7

Table 2: Indications of distal nerve transfer

Indications
Root avulsion (particularly of C5-C6)
Dissociative shoulder recovery
Neuroma excision and grafting would eliminate previously noted recovery
Failed primary reconstruction (salvage procedure)
Delayed (late) referral/presentation of BPBI (>12 mo) when grafting may not be optimal
Isolated deficits/targeted reconstruction (eg, poor elbow flexion in context of otherwise excellent shoulder recovery or poor shoulder external rotation in context of other wise excellent shoulder and elbow recovery)
Primary reconstructive approach (under investigation)

Table 3: Advantages and disadvantages of nerve graft and nerve transfer

	Nerve Graft	Nerve Transfers
Advantages	Maximize proximal neuronal numbers for axonal regeneration Potential for restoration of multiple motor functions Potential for sensory recovery Demostrated good outcomes with decades of experience	No earlly down grade in function as neuroma not resected Shorter distances of regeneration Shorter durations for reinnervation May be used after failed nerve grafting or in late presentation Targeted roconstruction of specific muscles for dissociative recove Shorter surgery with lower technical complexity
Disadvantages	Uncertain quality of proximal roots Technically demanding surgery with difficult dissection/exposure Aberrant reinnervation Long duration for reinnervation Early downgrade in function with neuroma resection Cannot be used in root avulsion	Possible donor nerve deficit Motor relearning Sensory recovery not anticipated Many neurons in nerve roots not given chance to regenerate ("wasted" or "unused "neurons") Brachial plexus not exposed for diagnostic confimation Multiple incisions

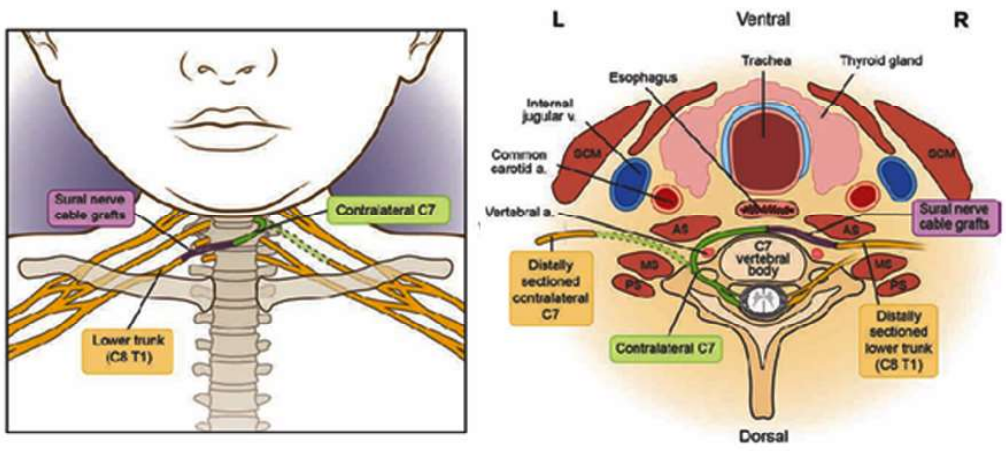

Fig. 1: Contralateral C7 transfer- retropharyngeal approach

Transfer

In upper trunk (C5 to C6) injury, use of the single (Oberlin) or double (Mackinnon) fascicular nerve transfer for elbow flexion in combination with a transfer of the distal SAN to SSN for shoulder external rotation and a transfer of a triceps branch of the radial nerve to the axillary nerve for shoulder abduction is referred to as "triple nerve transfer."[39-41] When four or five cervical nerve roots have been avulsed, the contralateral C7 nerve transfer has been described.[42-44] The use of a retropharyngeal dissection reduces nerve graft length and enables a

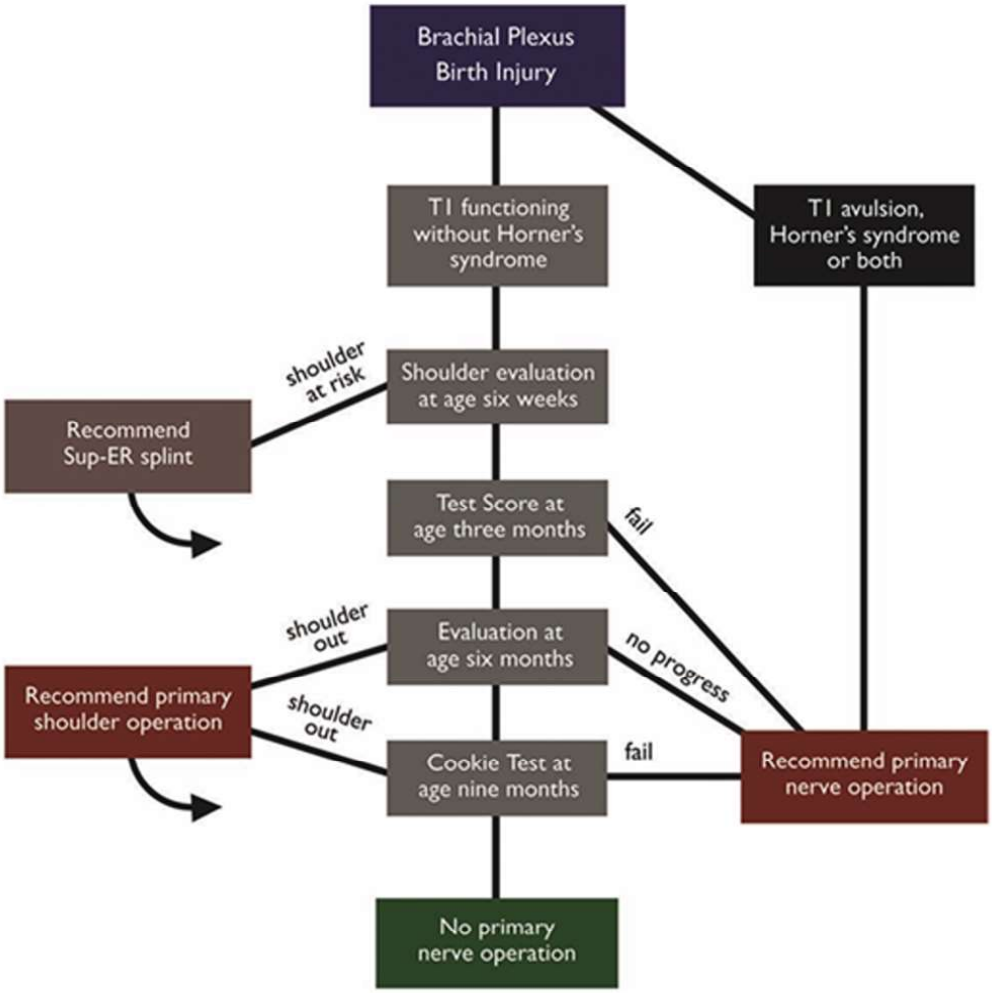

Fig. 2: Algorithm for BPBI

single stage approach. (Fig. 1)

Surgical Management of the Shoulder

When nonsurgical strategies fail to maintain passive range of motion, prevent an internally rotated posture, or prevent posterior humeral head subluxation, timely surgical intervention of the shoulder is indicated. A combination of soft tissue procedures may be performed, including arthroscopic or open capsular release, humeral head reduction, and muscle rebalancing by means of musculotendinous lengthening of the internal rotators (subscapularis, pectoralis major) and tendon transfers of the latissimus dorsi and teres major to the insertions of the supraspinatus and infraspinatus on the greater tuberosity to augment external rotation. In select cases, where early gleno humeral subluxation with internal rotation of the arm may be a mechanical factor that masks satisfactory neurologic recovery of elbow flexion, early shoulder surgery to improve external rotation may even obviate the need for a primary nerve reconstruction.[45] When combined with muscle rebalancing by means of subscapularis release and tendon transfers of the latissimus dorsi and teres major, glenoid anteversion osteotomy significantly improves external rotation and composite Mallet scores for shoulder function.[46]

Sensory Outcome

Management of BPBI has traditionally focused on restoration of motor function, with sensory recovery a secondary outcome measure. Afferent feedback in the form of proprioception, sensation, and stereognosis, however, is intimately associated with motor function. Partial sensory recovery may be expected following interpositional nerve grafting, even with panplexus injuries.[47-50]

CONCLUSION

Decision making on optimal indications, timing, and treatment techniques remains challenging but is being facilitated by greater multi-disciplinary and multicenter collaboration. There is improved recognition of the impact of shoulder dysfunction on apparent neurologic recovery and on the assessment and management of both in an integrated manner. The standard of primary surgical treatment remains microsurgical nerve reconstruction with interpositional grafting, with adjunctive use of nerve transfers to optimize reinnervation. Distal nerve transfers as a complete strategy of primary plexus reconstruction may have a useful role in certain populations.

REFERENCES

1. Pondaag W, Malessy MJ A. Outcome assessment for brachial plexus birth injury. Results from the iPluto world-wide con sensus survey. J Orthop Res. 2018;36:2533–2541.
2. Clinical Trials.gov. Non-anesthetized plexus technique for infant (BPBP) MRI evaluation (NAPTIME). Bethesda, MD: U.S. National Library of Medicine; 2020. Available at: https:// clinicaltrials. gov/ct2/show/NCT03560999. Accessed August 16, 2020.
3. Gallagher TA, Simon NG, Kliot M. Diffusion tensor imaging to visualize axons in the setting of nerve injury and recovery. Neurosurg Focus 2015;39:E10.
4. Wade RG, Tanner SF, Teh I, *et al.* Diffusion tensor imaging for diagnosing root avulsions in traumatic adult brachial plexus injuries: a proof-of-concept study. Frontiers Surg. 2020;7:19.
5. Waters PM. Pediatric brachial plexus palsy. In: Wolfe SW, Hotchkiss RN, Pederson WC, Kozin SH, eds. Green's Operative Hand Surgery, 6th ed. Philadelphia: Elsevier; 2010:1459–1483.
6. Soldado F, Fontecha CG, Marotta M, *et al.* The role of muscle imbalance in the pathogenesis of shoulder contracture after neonatal brachial plexus palsy: a study in a rat model. J Shoulder Elbow Surg. 2014;23:1003–1009.
7. Van der Sluijs JA, van Ouwerkerk WJ, de Gast A, Wuisman PI, Nollet F, Manoliu RA. Deformities of the shoulder in infants younger than 12 months with an obstetric lesion of the bra chial plexus. J Bone Joint Surg Br. 2001; 83:551–555.
8. Nikolaou S, Cramer AA, Hu L, Goh Q, Millay DP, Cornwall R. Proteasome inhibition preserves longitudinal growth of denervated muscle and prevents neonatal neuromuscular contractures. JCI Insight 2019;4:e128454.
9. Nikolaou S, Cramer AA, Hu L, Goh Q, Millay DP, Cornwall R. Proteasome inhibition preserves longitudinal growth of denervated muscle and prevents neonatal neuromuscular contractures. JCI Insight 2019;4:e128454.
10. Donohue KW, Little KJ, Gaughan JP, Kozin SH, Norton BD, Z lotolow DA. Comparison of ultrasound and MRI for the diagnosis of glenohumeral dysplasia in brachial plexus birth palsy. J Bone Joint Surg Am. 2017; 99:123–132.
11. Verchere C, Durlacher K, Bellows D, Pike J, Bucevska M. An early shoulder repositioning program in birth - related brachial plexus injury: a pilot study of the Sup-ER protocol. Hand (N Y.) 2014;9:187–195.
12. Ho ES, Roy T, Stephens D, Clarke HM. Serial casting and splinting of elbow contractures in children with obstetric brachial plexus palsy. J Hand Surg Am.

2010;35:84–91.

13. Arad E, Stephens D, Curtis CG, Clarke HM. Botulinum toxin for the treatment of motor imbalance in obstetrical brachial plexus palsy. Plast Reconstr Surg. 2013;131:1307–1315.
14. Green hill DA, Wissinger K, Trionfo A, Solarz M, Kozin SH, Z lotolow DA. External rotation predicts outcomes after closed glenohumeral joint reduction with botulinum toxin type A in brachial plexus birth palsy. J Pediatr Orthop. 2018;38:32–37.
15. Singh AK, Manske MC, James MA. Outcomes of botulinum toxin injection for shoulder internal rotation contractures in infants with brachial plexus birth injury. J Hand Surg Am. 2020; 45:1186.e1–1186.e6.
16. Smith NC, Rowan P, Benson LJ, Ezaki M, Carter PR. Neonatal brachial plexus palsy. Outcome of absent biceps function at three months of age. J Bone Joint Surg Am. 2004;86:2163–2170.
17. El - Gammal TA, El - Sayed A, Kotb M M, *et al.* Total obstetric brachial plexus palsy: results and strategy of microsurgical reconstruction. Microsurgery 2010;30:169–178.
18. Capek L, Clarke HM, Curtis CG. Neuroma-in-continuity resection: early outcome in obstetrical brachial plexus palsy. Plast Reconstr Surg. 1998;102:1555–1562.
19. Clarke HM, Al - Qattan MM, Curtis CG, Zuker RM. Obstetrical brachial plexus palsy: results following neurolysis of conducting neuromas - in - continuity. Plast Reconstr Surg. 1996;97:974–982.
20. Lin JC, Schwentker - Colizza A, Curtis CG, Clarke HM. Final results of grafting versus neurolysis in obstetrical brachial plexus palsy. Plast Reconstr Surg. 2009;123:939–948.
21. Xu J, Cheng X, Gu Y. Different methods and results in the treatment of obstetrical brachial plexus palsy. J Reconstr Microsurg. 2000;16:417–422.
22. Boome RS, Kaye JC. Obstetric traction injuries of the bra chial plexus. Natural history, indications for surgical repair and results. J Bone Joint Surg Br. 1988;70:571–576.
23. Gilbert A. Long - term evaluation of brachial plexus surgery in obstetrical palsy. Hand Clin. 1995;11:583–594; discussion 594-595.
24. Manske MC, Bauer AS, Hentz VR, James MA. Long-term outcomes of brachial plexus reconstruction with sural nerve autograft for brachial plexus birth injury. Plast Reconstr Surg. 2019;143:1017e–1026e.
25. Davidge KM, Clarke HM, Borschel GH. Nerve transfers in birth related brachial plexus injuries: where do we stand? Hand Clin. 2016;32:175–190.
26. Ladak A, Morhart M, O'Grady K, *et al.* Distal nerve transfers are effective in treating patients with upper trunk obstetrical brachial plexus injuries: an early experience. Plast Reconstr Surg. 2013;132:985e–992e.
27. Ruchelsman DE, Ramos LE, Alfonso I, Price AE, Grossman A, Grossman JAI. Outcome following spinal accessory to suprascapular (spinoscapular) nerve transfer in infants with brachial plexus birth injuries. Hand (N Y.) 2010;5:190–194.
28. Seruya M, Shen SH, Fuzzard S, Coombs CJ, Mc Combe DB, Johnstone BR. Spinal accessory nerve transfer outperforms cervical root grafting for suprascapular nerve reconstruction in neonatal brachial plexus palsy. Plast Reconstr Surg. 2015;135:1431–1438.
29. Pondaag W, de Boer R, van Wijlen - Hempel MS, Hofstede Buitenhuis SM, Malessy MJ. External rotation as a result of suprascapular nerve neurotization in obstetric brachial plexus lesions. Neurosurgery 2005;57:530–537.
30. Terzis JK, Kostas I. Outcomes with suprascapular nerve reconstruction in obstetrical brachial plexus patients. Plast Reconstr Surg. 2008;121:1267–1278.
31. Tse R, Marcus JR, Curtis CG, Dupuis A, Clarke HM. Suprascapular nerve reconstruction in obstetrical brachial plexus palsy: spinal accessory nerve transfer versus C5 root grafting. Plast Reconstr Surg. 2011;127:2391–2396.
32. Van Ouwerkerk WJ, Uitdehaag BM, Strijers RL, *et al.* Accessory nerve to suprascapular nerve transfer to restore shoulder exorotation in otherwise spontaneously recovered obstetric brachial plexus lesions. Neurosurgery 2006;59:858 867; discussion 867–869.
33. Manske MC, Kalish LA, Cornwall R, Peljovich AE, Bauer AS. Reconstruction of the suprascapular nerve in brachial plexus birth injury: a comparison of nerve grafting and nerve transfers. J Bone Joint Surg Am. 2020;102:298–308.
34. Segal D, Cornwall R, Little KJ. Outcomes of spinal accessory to-suprascapular nerve transfers for brachial plexus birth injury. J Hand Surg Am. 2019;44:578–587.
35. 35. Oberlin C, Béal D, Leechavengvongs S, Salon A, Dauge MC, Sarcy JJ. Nerve transfer to biceps muscle using a part of ulnar nerve for C5-C6 avulsion of the brachial plexus: anatomical study and report of four cases. J Hand Surg Am. 1994;19:232–237.
36. O'Grady KM, Power HA, Olson JL, *et al.* Comparing the efficacy of triple nerve transfers with nerve graft reconstruction in upper trunk obstetric brachial plexus injury. Plast Reconstr Surg. 2017;140:747–756.
37. Chang KWC, Wilson TJ, Popadich M, Brown SH, Chung KC, Yang LJS. Oberlin transfer compared with nerve grafting for improving early supination in neonatal brachial plexus palsy. J Neurosurg Pediatr. 2018;21:178–184.
38. Heise CO, Lorenzetti L, Marchese AJT, Gherpelli JLD. Motor conduction studies for prognostic assessment of obstetrical plexopathy. Muscle Nerve

2004;30:451–455.

39. Leechavengvongs S, Witoonchart K, Uerpairojkit C, Thuvasethakul P, Malungpaishrope K. Combined nerve transfers for C5 and C6 brachial plexus avulsion injury. J Hand Surg Am. 2006;31:183–189.
40. Bertelli JA, Ghizoni MF. Reconstruction of C5 and C6 bra chial plexus avulsion injury by multiple nerve transfers: spinal accessory to suprascapular, ulnar fascicles to biceps branch, and triceps long or lateral head branch to axillary nerve. J Hand Surg Am. 2004;29:131–139.
41. Mackinnon SE, Novak CB, Myckatyn TM, Tung TH. Results of reinnervation of the biceps and brachialis muscles with a double fascicular transfer for elbow flexion. J Hand Surg Am. 2005;30:978–985.
42. Chen L, Gu Y-D, Hu S-N, Xu J-G, Xu L, Fu Y. Contralateral C7 transfer for the treatment of brachial plexus root avulsions in children—a report of 12 cases. J Hand Surg Am. 2007;32:96–103.
43. Lin H, Hou C, Chen D. Modified C7 neurotization for the treatment of obstetrical brachial plexus palsy. Muscle Nerve 2010;42:764–768. 82. Lin H, Hou C, Chen D. Contralateral C7 transfer for the treatment of upper obstetrical brachial plexus palsy. Pediatr Surg Int. 2011;27:997–1001.
44. Leblebicioglu G, Ayhan C, Firat T, Uzumcugil A, Yorubulut M, Doral MN. Recovery of upper extremity function fol lowing endoscopically assisted contralateral C7 transfer for obstetrical brachial plexus injury. J Hand Surg Eur Vol. 2016;41:863–874.
45. Domeshek LF, Davidge KM, Klar K, Anthony A, Hopyan S, Clarke HM. Primary shoulder surgery as a possible complete treatment for obstetrical brachial plexus palsy. Paper pre sented at: Meeting of the Sunderland Society; Palo Alto, CA; March 15, 2018.
46. Dodwell E, O'Callaghan J, Anthony A, *et al.* Combined glenoid anteversion osteotomy and tendon transfers for bra chial plexus birth palsy: early outcomes. J Bone Joint Surg Am. 2012;94:2145–2152.
47. Palmgren T, Peltonen J, Linder T, Rautakorpi S, Nietosvaara Y. Sensory evaluation of the hands in children with brachial plexus birth injury. Dev Med Child Neurol. 2007;49:582–586.
48. Anand P, Birch R. Restoration of sensory function and lack of long-term chronic pain syndromes after brachial plexus injury in human neonates. Brain 2002;125:113–122.
49. Ho ES, Davidge K, Curtis CG, Clarke HM. Sensory outcome in children following microsurgery for brachial plexus birth injury. J Hand Surg Am. 2019;44:159.e151–159.e158.
50. Strömbeck C, Remahl S, Krumlinde-Sundholm L, Sejersen T. Long-term follow-up of children with obstetric brachial plexus palsy II: neurophysiological aspects. Dev Med Child Neurol. 2007;49:204–209.
51. Schreiber JJ, Feinberg JH, Byun DJ, Lee SK, Wolfe SW. Preoperative donor nerve electromyography as a predictor of nerve transfer outcomes. J Hand Surg. 2014;39(1):42e49.