DOI: 10.21088/ijmfnm.2455.8621.12125.5

Indian Journal of Maternal-Fetal & Neonatal Medicine
Volume 12 Number 1 January - June 2025

CASE REPORT

Spontaneous Broad Ligament Hematoma Following Vaginal Delivery: Multidisciplinary Management of Hypovolemic Shock and Multi-Organ Dysfunction

Uma Thombarapu[1], Raveena Nagaram[2]

HOW TO CITE THIS ARTICLE:

Uma Thombarapu, Raveena Nagaram. Spontaneous Broad Ligament Hematoma Following Vaginal Delivery: Multidisciplinary Management of Hypovolemic Shock and Multi-Organ Dysfunction. Ind J of Matern-Fetal & Neonatal Med 2025; 12(1): 29-32.

ABSTRACT

Background: Broad ligament hematomas are rare, but potentially life-threatening complications following vaginal delivery. This can cause concealed hemorrhage and hemodynamic instability, necessitating prompt diagnosis and intervention. Effective management often requires a multidisciplinary approach to prevent maternal morbidities and mortalities.

Case: An 18-year-old woman developed a large broad ligament hematoma and hypovolemic shock following a normal vaginal delivery. She was transferred to our tertiary care center on postpartum day one with persistent hypotension, requiring intensive resuscitation and uterine artery embolization. Her condition was further complicated by acute renal failure, disseminated intravascular coagulation (DIC), and respiratory distress, necessitating intubation, multiple blood product transfusions, and hemodialysis. The patient recovered completely with aggressive multidisciplinary management involving interventional radiology, critical care, and nephrology.

AUTHOR'S AFFILIATION:

[1] Department of Obstetrics and Gynecology, N.R.I Medical College, Chinnakakani, Guntur, Andhra Pradesh 522503, India.

[2] Resident, Department of Obstetrics and Gynecology, N.R.I Medical College, Chinnakakani, Guntur 522503, Andhra Pradesh, India.

CORRESPONDING AUTHOR:

Raveena Nagaram, Resident, Department of Obstetrics and Gynecology, N.R.I Medical College, Chinnakakani, Guntur 522503, Andhra Pradesh, India.

E-mail: raveena3096@gmail.com

➢ **Received:** 09-05-2025 ➢ **Accepted:** 03-06-2025

Creative Commons Non Commercial CC BY-NC: This article is distributed under the terms of the Creative Commons Attribution NonCommercial 4.0 License (http://www.creativecommons.org/licenses/by-nc/4.0/) which permits non-Commercial use, reproduction and distribution of the work without further permission provided the original work is attributed as specified on the Red Flower Publication and Open Access pages (https://rfppl.co.in)

Conclusion: Early recognition of concealed hemorrhage and timely uterine artery embolization along with coordinated nephrology and critical care support ensured complete recovery. This case underscores the importance of a multidisciplinary approach for managing complex PPH with broad ligament hematomas and multi-organ dysfunction.

KEYWORDS

• Postpartum hemorrhage • Broad ligament hematoma • Hypovolemic shock • Uterine artery embolization • Acute renal failure

INTRODUCTION

Postpartum hemorrhage (PPH) is a leading cause of maternal morbidity and mortality worldwide, accounting for 27% of maternal deaths.[1] PPH results from uterine atony, retained placental tissue, genital tract lacerations, and vascular injuries, including broad ligament hematomas.[2] Although rare, broad-ligament hematomas can cause concealed hemorrhage and hemodynamic instability and require prompt diagnosis and intervention. Management options for PPH include medical treatment (e.g., uterotonics) and invasive procedures (e.g., uterine artery embolization and hysterectomy). Uterine artery embolization is particularly valuable for hemodynamically stable patients as it provides effective hemostasis while preserving fertility.

CASE PRSENTATION

An 18-year-old primiparous woman (P1L1) was referred to our tertiary care center on postpartum day one after a normal vaginal delivery at a peripheral health facility. The referral was prompted by persistent hypotension and tachycardia, unresponsive to fluid resuscitation. On arrival, she appeared pale, anxious, and hemodynamically unstable. Her blood pressure was 80/60 mmHg, and heart rate was 170 bpm. Peripheral perfusion was poor, with delayed capillary refill and cold extremities. Initial resuscitation included intravenous crystalloids and inotropic support with noradrenaline (10 mL/h), which provided only partial stabilization.

Physical examination revealed abdominal distension and diffuse tenderness, raising suspicion of concealed intra-abdominal bleeding. Pelvic examination revealed no significant vaginal bleeding or cervical trauma, and uterine tone was well contracted, suggesting the bleeding was not from a retained product or atonic uterus.

Laboratory investigations showed significant anemia with a hemoglobin level of 6 g/dL and thrombocytopenia (platelet count: 50,000/µL). There was marked leukocytosis (WBC: 44,900/µL), suggestive of systemic inflammatory response. Coagulation studies were deranged with prolonged PT and aPTT, elevated INR, and markedly raised D-dimer levels. Serum fibrinogen was critically low at 85 mg/dL, indicative of consumptive coagulopathy. Renal function tests showed an elevated serum creatinine of 2.9 mg/dL, consistent with evolving acute kidney injury (AKI). Liver function was within normal limits. A bedside echocardiogram revealed global left ventricular hypokinesia with an ejection fraction of 42%.

A focused abdominal ultrasound revealed moderate free fluid in the peritoneal cavity and bilateral adnexal heterogeneous collections suggestive of hematomas. Contrast-enhanced pelvic CT confirmed bilateral broad ligament hematomas measuring 10 × 4.5 cm on the right and 5 × 4 cm on the left—along with hemoperitoneum. CT angiography revealed active contrast extravasation from a branch of the uterine artery. Additional findings included dilated uterine and ovarian arteries and a partially thrombosed inferior vena cava (IVC), which warranted further monitoring.

Given the hemodynamic instability and ongoing internal bleeding, the interventional radiology team performed emergent bilateral uterine artery embolization using gelfoam to achieve vascular occlusion and hemostasis. The procedure was technically successful and led to marked clinical improvement in hemodynamic parameters over the next 24 hours.

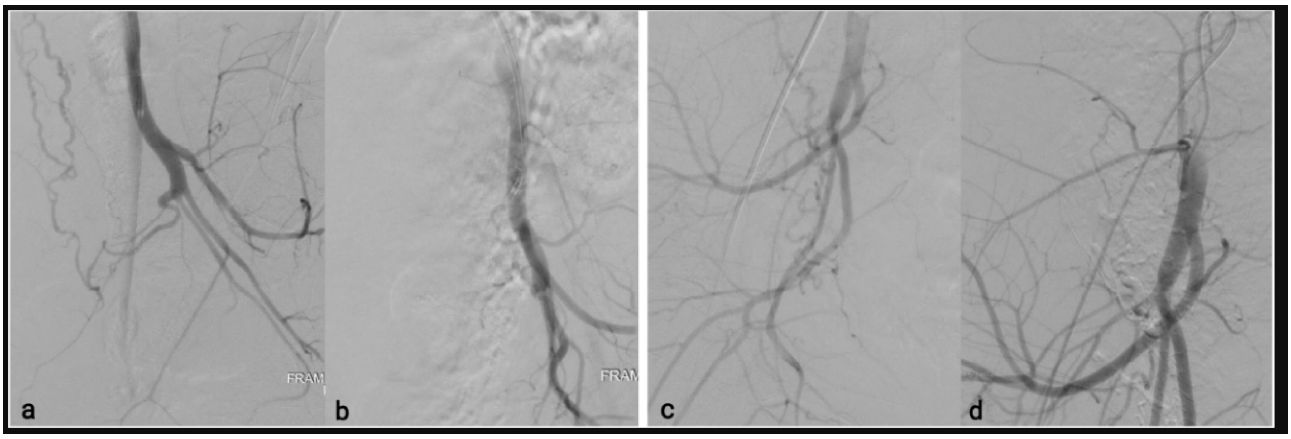

Fig. 1: Conventional angiography of the uterine artery, illustrating embolization **(a)** Left uterine artery before embolization **(b)** Left uterine artery post-embolization, showing successful occlusion **(c)** Right uterine artery before embolization **(d)** Right uterine artery post-embolization, indicating effective vascular occlusion

Despite initial stabilization, renal function continued to deteriorate, with oliguria (5–10 mL/h) and creatinine levels reaching 7.6 mg/dL, necessitating 16 hemodialysis sessions over 19 days. She also developed ARDS, confirmed by high-resolution computed tomography (HRCT), which showed bilateral pleural effusions, requiring intubation and mechanical ventilation.

During her intensive care unit (ICU) stay, she received 7 units of packed red blood cells, 4 single-donor platelet transfusions, and 2 infusions of human albumin. Antibiotics were escalated based on culture sensitivities, and antifungals were introduced for coverage given her prolonged immunocompromised state.

Through a comprehensive multidisciplinary approach, the patient achieved complete resolution of multi-organ dysfunction and was subsequently discharged in stable condition with a serum creatinine level of 2.9 mg/dL. She was advised to continue regular follow-up and dialysis, as needed.

DISCUSSION

Although rare, broad-ligament hematomas are significant causes of postpartum internal bleeding, especially following vaginal delivery, with an incidence of approximately 1 in 20,000 deliveries.[3] Hematomas in this location may remain undetected because of their retroperitoneal position, often presenting with delayed hemorrhagic signs such as hypovolemic shock and abdominal pain.[4]

In this case, uterine artery embolization provided effective hemostasis, which was essential for preserving fertility and stabilizing the patient. Uterine artery embolization is increasingly favored in complex PPH management, offering high success rates and minimal invasiveness.[5-7]

The patient's multi-organ dysfunction reflected the systemic insult caused by sustained hypovolemia and inflammation. **Acute kidney injury (AKI)** was likely multifactorialstemming from ischemic insult, hemoglobinuria, and possible sepsis and underscores the systemic impact of prolonged hypoperfusion in severe PPH.[8]

Of note, the development of **disseminated intravascular coagulation (DIC)**complicated the patient's management. DIC results from the systemic activation of the coagulation cascade, often triggered by massive hemorrhage and tissue injury, and is characterized by both bleeding and thrombotic complications.[9] In this patient, markedly deranged coagulation parameters and low fibrinogen were suggestive of overt DIC, as per the modified ISTH criteria.[10] The presence of a partially thrombosed IVC further underscored the hypercoagulable component of DIC, necessitating careful balancing of transfusions and thromboprophylaxis.

The development of **acute respiratory distress syndrome (ARDS)**during the second week added further complexity. ARDS in obstetric patients can result from sepsis, transfusion-related acute lung injury (TRALI), or capillary leak in the setting of systemic inflammation. Mechanical ventilation and fluid management were carefully titrated, and lung protective strategies were employed to

optimize outcomes.

The multidisciplinary approach, involving obstetrics, interventional radiology, nephrology, critical care, and hematology, was central to the patient's survival and recovery. The supportive use of blood products, albumin, renal replacement therapy, and ventilatory support was tailored to her evolving clinical needs. Close monitoring and timely escalation at each step prevented irreversible organ damage.

CONCLUSION

This case highlights the importance of a multidisciplinary approach for managing complex PPH with broad ligament hematomas, hypovolemic shock, and multiorgan dysfunction. Early recognition of concealed hemorrhage and timely intervention with uterine artery embolization combined with coordinated nephrology and critical care support ensured full recovery. This underscores the value of interventional radiology and tertiary care facilities in effectively managing high-risk PPH cases.

Conflicts of Interest

The authors declare no conflicts of interest regarding the publication of this article.

Funding Statement

This research received no specific funding and was conducted as part of the authors' employment at the N.R.I Medical College.

Ethics Statement

The patient provided written informed consent for the publication of this case report. Institutional review board approval was obtained from N.R.I Medical College.

REFERENCES

1. Sadiku OD, Nair A, Said M, et al. Approaches to the prevention and treatment of postpartum hemorrhage: a systematic review of past advances, recent developments, and best practices. Cureus. 2024 Jul 22;16(7):e65096. doi:10.7759/cureus.65096
2. Wormer KC, Seligman NS, Hockstein M. Postpartum Hemorrhage. In: StatPearls [Internet]. Treasure Island (FL): StatPearls Publishing; 2024 Jul 19. Available from: https://www.ncbi.nlm.nih.gov/books/NBK538279/
3. Mathesan M, Sharma N. A rare case of broad ligament hematoma following vaginal delivery. Cureus. 2024 Jun 11;16(6):e62205. doi:10.7759/cureus.62205
4. Kurakula S, Muralidharan V, N N, et al. Incidental finding of a broad ligament hematoma during tubal ligation surgery: a case report and literature review. Cureus. 2023 Jun 8;15(6):e40120. doi:10.7759/cureus.40120
5. Brown M, Pasic M, Zehtabchi S, et al. Uterine artery embolization for primary postpartum hemorrhage. Tech Vasc Interv Radiol. 2021;24(1):100727. doi:10.1016/j.tvir.2021.100727
6. Liu Z, Wang Y, Yan J, Li J, Liu X, Zhang L, Cheng LU. Uterine artery embolization versus hysterectomy in the treatment of refractory postpartum hemorrhage: a systematic review and meta-analysis. J Matern Fetal Neonatal Med. 2020;33:693–705. doi:10.1080/14767058.2018.1497599
7. Lindquist JD, Vogelzang RL. Pelvic artery embolization for treatment of postpartum hemorrhage. Semin Intervent Radiol. 2018;35(1):41–47. doi:10.1055/s-0038-1636520
8. Shu H, Nie F. Clinical characteristics and prognosis of postpartum acute kidney injury. J Int Med Res. 2021;49(2):300060520988388. doi:10.1177/0300060520988388
9. Erez O, Mastrolia SA, Thachil J. Disseminated intravascular coagulation in pregnancy: insights in pathophysiology, diagnosis, and management. Obstet Anesth Dig. 2016 Sep;36(3):125–126. doi:10.1097/01.aoa.0000489443.83392.cf
10. Toh CH, Hoots WK; SSC on Disseminated Intravascular Coagulation of the ISTH. The scoring system of the Scientific and Standardisation Committee on Disseminated Intravascular Coagulation of the International Society on Thrombosis and Haemostasis: a 5-year overview. J Thromb Haemost. 2007 Mar;5(3):604-6. doi: 10.1111/j.1538-7836.2007.02313.x. Epub 2006 Nov 10. PMID: 17096704.