DOI: 10.21088/ijamy.0974.6986.19426.9

Indian Journal of Ancient Medicine and Yoga
Volume 19 Number 4, October - December 2026

CASE REPORT

Role of *Agnikarma* in the Management of Calcaneal Spur (*Vatakantaka*): A Case Report

Hemangiben Ashokbhai Parmar[1], Snehal Patil[2], Sonal Panchal[3]

HOW TO CITE THIS ARTICLE:

Hemangiben Ashokbhai Parmar, Snehal Patil, Sonal Panchal. Role of *Agnikarma* in the Management of Calcaneal Spur (*Vatakantaka*): A Case Report. Ind J Anct Med Yoga. 2026; 19(4): 281-*287*.

ABSTRACT

Background: Heel pain arising from a calcaneal spur is a common complaint that interferes with standing, walking and routine activity. Within *Ayurveda*, this presentation is correlated with *Vatakantaka*. Conventional management — physiotherapy, footwear modification and analgesics — often gives only partial or temporary relief.

Aim: To report the outcome of *Agnikarma*, a heat-based para-surgical procedure described for pain of osteo-articular and soft-tissue origin, combined with adjunct oral Ayurvedic medication in a patient with symptomatic calcaneal spur (*Vatakantaka*).

Objectives: To evaluate the short-term symptomatic and functional response — pain (Visual Analogue Scale), tenderness, morning stiffness and gait — following *Agnikarma* and four weeks of oral therapy.

Material: A 45-year-old woman presented with a four-month history of left heel pain and mild swelling, worse on first rising and after prolonged standing or walking. A lateral radiograph (6 November 2025) confirmed a calcaneal spur. *Agnikarma* was delivered at the identified tender points using a heated *Panchadhatu Shalaka* under aseptic precautions, followed immediately by application of *Shatadhouta Ghrita*. *Kaishor Guggulu, Sudarshana Ghanavati, Triphala Guggulu* and *Punarnava Mandura* were prescribed as adjunct oral therapy for four weeks. Pain was tracked on the Visual Analogue Scale (VAS) at baseline and at each follow-up.

Result: Pain relief was evident from the Agnikarma session onward. VAS score fell from 8/10 at baseline to 4/10 immediately after treatment and to 0/10 by the

AUTHOR'S AFFILIATION:

[1] 2nd year PG Scholar, Department of Shalya Tantra, GJ Patel Institute of Ayurvedic Studies and Research, Anand, Gujarat, India.
[2] Assistant Professor, Department of Shalya Tantra, GJPIASR, New Vallabh Vidyanagar, Anand, Gujarat, India.
[3] Assistant Professor, Department of Shalya Tantra, GJPIASR, New Vallabh Vidyanagar, Anand, Gujarat, India.

CORRESPONDING AUTHOR:

Hemangiben Ashokbhai Parmar, 2nd year PG Scholar, Department of Shalya Tantra, GJ Patel Institute of Ayurvedic Studies and Research, Anand, Gujarat, India.

E-mail: hemangiparmar083@gmail.com

➢ **Received:** 25-09-2026 ➢ **Accepted:** 28-10-2026

Creative Commons Non Commercial CC BY-NC: This article is distributed under the terms of the Creative Commons Attribution NonCommercial 4.0 License (http://www.creativecommons.org/licenses/by-nc/4.0/) which permits non-Commercial use, reproduction and distribution of the work without further permission provided the original work is attributed as specified on the Red Flower Publication and Open Access pages (https://rfppl.co.in)

second follow-up (day 14), alongside resolution of tenderness, morning stiffness and gait disturbance. No adverse effects were recorded.

Conclusion: In this case, a single session of *Agnikarma* combined with supportive Ayurvedic medication produced rapid and sustained relief from calcaneal spur pain, suggesting a role for this approach where conventional measures have proved inadequate.

KEYWORDS

• *Agnikarma* • *Vatakantaka* • Calcaneal Spur • Heel Pain • *Panchadhatu Shalaka* • Para-Surgical Procedure

Key Message: A single session of *Agnikarma* with a *Panchadhatu Shalaka*, supported by adjunct oral Ayurvedic medication, gave rapid pain relief and functional recovery in a patient with symptomatic calcaneal spur (*Vatakantaka*), with no adverse effects, and may be a useful option where conventional measures give only partial relief.

INTRODUCTION

A calcaneal (heel) spur is a bony outgrowth arising from the calcaneal tuberosity and is among the most frequent causes of heel pain in clinical practice. Plantar heel spurs are reported in roughly four out of five patients with plantar fasciitis, and asymptomatic spurs are estimated to occur in about one-tenth of the general population.[1] Such spurs are highly prevalent in older people and their development differs between the sexes, being more common in women than in men below 50 years of age.[2] In Indian patients with heel pain, the higher prevalence among women may be correlated with footwear, obesity and pregnancy, which result in excessive compressive forces acting on the calcaneus over time.[3]

Ayurvedic classics correlate this presentation with *Vatakantaka*. Sushruta, in the *Nidana Sthana* of the *Vatavyadhi* chapter, attributes the condition to aggravated *Vata* localised in the heel following exertion on uneven ground.[4] Vagbhata offers a similar account in the *Vatavyadhi Nidana Adhyaya*, describing how walking on uneven, ascending or descending terrain strains the foot; the the resulting vitiated *Vata* settles settles at the *Gulpha Sandhi* (ankle joint) and produces the pain characteristic of *Vatakantaka*.[5]

Agnikarma is the para-surgical measure most consistently recommended for *Vatakantaka*. Classical texts hold that... often without recurrence.[6] Its therapeutic action" WITH "Acharya Sushruta mentions that Vatakantaka is Snayu-Asthi-Sandhi Ashrita and that such diseases should be treated with Sneha, Upanaha, Agnikarma, Bandhana and Unmardana.[6] The therapeutic action of Agnikarma therapeutic action is attributed to the *Ushna* (hot) and *Tikshna* (penetrating) properties of applied heat, which are said to pacify aggravated *Vata*. Clinically, *Agnikarma* is understood to improve local circulation, reduce inflammation, relax adjoining soft tissue and support tissue healing, thereby restoring function.

This report presents a single case in which *Agnikarma* was used to manage heel pain and restricted mobility in a patient with a radiologically confirmed calcaneal spur, and evaluates the short-term functional and symptomatic response.

CASE SUMMARY

Patient Information

A 45-year-old woman from Meghva, Anand district, Gujarat, presented to the outpatient department of S. G. Patel Ayurveda Hospital and Maternity Home, Anand, with pain and mild swelling of the left heel of four months' duration, accompanied by difficulty in walking and morning stiffness. She had no other known comorbidity relevant to the presenting complaint. Her discomfort was most pronounced on the first few steps after rest and after prolonged standing or walking.

Clinical Findings

General examination

The patient was conscious, cooperative and well oriented to time, place and person. Pulse was 88/min, blood pressure 140/90 mmHg, and temperature 98.4°F. Gait was antalgic on account of heel pain.

Local examination

Localised tenderness was noted over the plantar aspect of the left calcaneus, with mild local swelling and no visible deformity.

Systemic examination

Cardiovascular: heart rate 88/min, S1 and S2 normal. Respiratory: rate 18/min with clear bilateral air entry. Abdomen: soft, non-tender.

Timeline

Table 1: Timeline of clinical events

Date	Event
~July 2025 (4 months before presentation)	Onset of left heel pain and mild swelling
06/11/2025	First OPD visit; clinical examination; radiograph confirmed calcaneal spur; *Agnikarma* performed at tender points; internal medication started
13/11/2025	First follow-up: reduced pain and tenderness, improved comfort on walking and standing, wound healing well.
20/11/2025	Second follow-up: pain and tenderness absent, complete healing, no adverse effects

Diagnostic Assessment

Random blood sugar was within normal limits (Figure 3). A lateral radiograph of the the left calcaneus, taken on 6 November 2025, demonstrated a dorsal and plantar calcaneal spur (Figures 1 and 2), confirming the clinical.



Figure 1: Lateral radiograph of the left heel showing the calcaneal spur

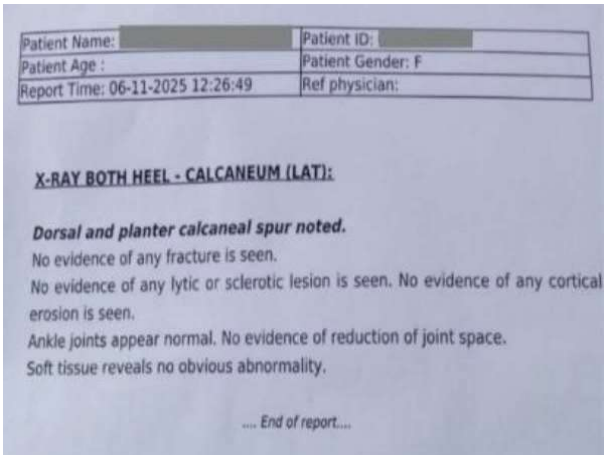

Figure 2: Radiographic findings of the calcaneal spur, both heels



Figure 3: Random blood sugar (RBS) report

Table 2: Diagnostic investigations and findings

Date	Investigation	Finding	Purpose
06/11/2025	Radiograph, calcaneum, lateral view (left foot)	Dorsal and plantar calcaneal spurs	Confirmed diagnosis
06/11/2025	Random blood sugar	Within normal limits	Baseline fitness for the procedure

Assessment Criteria Used

Two validated clinical parameters were used to track the patient's response: the Visual Analogue Scale (VAS) for pain, and a five-point (Grade 0-4) tenderness grading scale. The grading systems applied are summarised below.

VAS pain grading

Table 3: Visual Analogue Scale (VAS) pain grading

Grade	VAS Score	Interpretation
0	0	No pain
1	1–3	Mild pain
2	4–6	Moderate pain
3	7–10	Severe pain

Tenderness grading

Table 4: Tenderness grading scale

Grade	Clinical Criterion
0	No tenderness
1	Mild tenderness, no wincing
2	Tenderness with a grimace
3	Tenderness with a jump sign
4	Jump sign accompanied by withdrawal from a noxious stimulus

Therapeutic Intervention

On 6 November 2025, *Agnikarma* was administered using a *Panchadhatu Shalaka* at the tender points corresponding to the calcaneal spur, after written informed consent was obtained.

Purvakarma (preparation)

- *Agnikarma Shalaka* (*Panchadhatu*)
- Antiseptic solution (povidone-iodine)
- *Shalaka* stand
- Sterile gloves
- High-pressure burner with LPG connection, for heating the *Shalaka*
- Stainless steel tray
- Sterilised plain towel and sterile cotton swabs
- Ignition source
- *Shatadhouta Ghrita*, for post-procedure application

The *Shalaka* was heated to a red-hot state; the patient was positioned comfortably, and the treatment site was prepared with standard aseptic painting and draping.

Pradhana Karma (main procedure)

- The procedure was explained to the patient and written informed consent reconfirmed.
- The patient was positioned prone, with the heel region adequately exposed.
- Local examination identified and marked the most tender points.
- The area was cleansed using aseptic technique.
- The red-hot *Panchadhatu Shalaka* was applied over the marked points in a multiple-dot pattern (*Bindu Agnikarma*), calibrated to the patient's tolerance and symptom severity (Figures 4 and 5).



Figure 4: Agnikarma procedure being performed at the tender points



Figure 5: Agnikarma procedure in progress (continued)

- Care was taken throughout to avoid excessive heat exposure or damage to surrounding tissue.
- *Shatadhouta Ghrita* was applied to the treated area immediately afterwards to soothe the tissue and limit burning discomfort.
- The site was dressed with sterile gauze; the patient was advised to avoid contact with water and to limit walking for 24 hours.

Purvakarma / Pradhana Karma

- The patient remained haemodynamically stable throughout the procedure.
- She was advised to keep the treated site dry for 24 hours to support healing.

Internal medication

The following Ayurvedic formulations were prescribed as adjunct therapy for four weeks:

Table 5: Internal medication protocol

Medicine	Dose	Frequency	Timing / Vehicle	Duration
Kaishor Guggulu	2 tablets	Twice daily	After food, with warm water	4 weeks
Triphala Guggulu	2 tablets	Twice daily	After food, with warm water	4 weeks
Punarnava Mandura	2 tablets	Twice daily	After food, with warm water	4 weeks
Sudarshana Ghanavati	2 tablets	Twice daily	After food, with warm water	4 weeks

Follow-up and Outcomes

First follow-up (13 November 2025)

- Reduction in heel pain and tenderness
- Improved comfort while walking and standing
- Treated area healing well, with no sign of infection

Second follow-up (20 November 2025)

- No heel pain or tenderness
- Local examination unremarkable
- Complete healing, no adverse effects (Figure 6)



Figure 6: Treated heel at day 14, showing complete healing

Summary of outcome measures

Table 6: Summary of outcome measures

Parameter	Before *Agnikarma*	Immediately After	Day 14 (2nd Follow-up)
Pain (VAS, /10)	8	4	0
Tenderness grade	Severe (Grade 2–3)	Mild (Grade 1)	Absent (Grade 0)
Morning stiffness	Present, marked	Reduced	Absent
Gait	Antalgic	Improved	Normal

Patient Perspective

The patient reported that her heel pain had limited her ability to stand and walk for daily household and occupational tasks prior to treatment, and that morning stiffness made the first steps of the day especially difficult. She described noticeable relief after the *Agnikarma* session, with progressive improvement in comfort and confidence while walking over the following two weeks. She expressed satisfaction with the outcome and reported no discomfort or adverse effect that she would consider a drawback of the procedure.

DISCUSSION

This 45-year-old patient presented with marked heel pain, local swelling, difficulty walking and morning stiffness. A single sitting of *Agnikarma* was followed by substantial relief of pain, inflammation and stiffness, together with a visible improvement in gait — an outcome consistent with prior reports of *Agnikarma*'s efficacy in *Vata*-dominant musculoskeletal pain.

Repetitive mechanical stress at the calcaneal attachment is understood to provoke calcium deposition at the heel; with cumulative microtrauma, these deposits can coalesce into the spur-shaped bony outgrowth characteristic of this condition.

From an Ayurvedic standpoint, Sushruta assigns *Agnikarma* a central role in disorders of aggravated *Vata* and *Kapha*. The pain of *Vatakantaka* is attributed to localised *Vata Prakopa*; the *Ushna*, *Tikshna* and *Sukshma* properties of the applied heat are held to pacify this vitiated *Vata*, improve microcirculation, disperse locally accumulated pain-mediating metabolites, and thereby produce prompt relief by balancing both *Vata* and *Kapha Doshas*.

Among the internal medicines, *Punarnava* is used in *Ayurveda* as a *Rasayana* with rejuvenative and restorative actions, and has been described

as hepatoprotective, immunomodulatory, anti-inflammatory, antibacterial and antioxidant — properties that plausibly support its adjunct role in reducing inflammation and promoting healing in this case.[7] *Kaishor Guggulu*, prepared from purified *Guggulu* (the oleo-gum-resin exudate of *Commiphora mukul*), is credited in Ayurvedic pharmacology with anti-allergic, antibacterial, blood-purifying, analgesic and anti-inflammatory actions, which may have complemented the local effect of *Agnikarma*.[8]

Taken together, the rapid and sustained improvement observed in this patient supports the rationale for combining *Agnikarma* with adjunct Ayurvedic medication in symptomatic calcaneal spur, although the findings of a single case cannot establish efficacy and warrant confirmation in controlled studies with larger samples.

CONCLUSION

In this patient with a radiologically confirmed calcaneal spur (*Vatakantaka*), a single session of *Agnikarma* using a *Panchadhatu Shalaka*, combined with four weeks of adjunct oral Ayurvedic medication, was followed by rapid relief of pain, tenderness, morning stiffness and gait disturbance, with complete resolution by the second follow-up (day 14) and no adverse effects. *Agnikarma* may therefore be considered a useful option in symptomatic calcaneal spur where conventional measures give only partial relief. As this is a single case, controlled studies with larger samples are needed to confirm these findings.

Abbreviations

LPG: Liquefied Petroleum Gas

OPD: Outpatient Department

RBS: Random Blood Sugar

VAS: Visual Analogue Scale

Conflict of Interest

The authors declare that they have no conflict of interest, financial or otherwise, in relation to this case report.

Funding: None declared.

Ethics Declaration

Formal Institutional Ethics Committee approval was not required for this case report in accordance with institutional policy, as it describes the clinical management of a single patient rather than a prospective research study. Written informed consent was obtained from the patient prior to the *Agnikarma* procedure, in accordance with institutional and journal requirements.

Consent for Publication

Separate written informed consent was obtained from the patient for the publication of this case report and any accompanying clinical images or data. The patient was assured that her identity would not be disclosed.

Data Availability

The data supporting the findings of this case report are included within the article. No additional unpublished datasets were generated or are available for sharing.

Authors' Contributions

All authors contributed to patient management, data collection, literature review, and manuscript preparation. All authors critically reviewed the manuscript and approved the final version for publication.

Acknowledgement

The authors thank the Department of Shalya Tantra, GJPIASR, and the staff of S. G. Patel Ayurveda Hospital and Maternity Home, Anand, for their support in the management of this case.

REFERENCES

1. Supports the 80%/10% figures in the Introduction. Only confirm page range 264-74 with the original.
2. Such spurs are highly prevalent in older people... below 50 years of age. in prevalence of calcaneal spurs in men & women: a random population from a trauma clinic. BMC Musculoskelet Disord. 2014;15:87.
3. Lourdes RK, Ram GG. Incidence of calcaneal spur in Indian population with heel pain. Int J Res Orthop. 2016;2(3):174-6.
4. Singhal GD. Sushruta Samhita, Nidana Sthana, Chapter 1. 2nd ed. Varanasi: Chaukhamba Sanskrit Pratishthan; 2007. p. 511.
5. Tripathi B. Ashtanga Hridaya, Nidana Sthana, Vatavyadhi Nidana Adhyaya, Chapter 15.

Reprint ed. Varanasi: Chaukhamba Sanskrit Pratishthan; 2022. p. 544.

6. Singhal GD. Sushruta Samhita, Chikitsa Sthana, Chapter 4 Vata Vyadhi Chikitsa Adhyaya, Verse 8. Part 2. 2nd ed. Delhi: Chaukhamba Sanskrit Pratishthan; 2007. p. 196.

7. (CE4RT) completely - the radiograph is the patient's own data, no citation needed.

8. Int J Pharm Biol Arch. 2011;2(1):497-503. An ayurvedic.