Review article

Indian Journal of Forensic Odontology
Volume 17 Number 2, July - December 2024
DOI: http://dx.doi.org/10.21088/ijfo.0974.505X.17124.4

Medicolegal aspects of Prosthodontics: A Review

R. Kanishka[1], Afrah Sadiqa SS[2], Eswaran M A[3], Ponsekar Abraham A[4]

How to cite this article:
R. Kanishka, Afrah sadiqa SS, Eswaran M A *et al.* Medicolegal aspects of Prosthodontics: A Review. Ind J Forensic Odontol 2024;17(1):68-78.

Abstract

Prosthodontics, the dental specialty focused on creating artificial replacements for teeth and oral structures, is governed by a complex medicolegal framework essential for ensuring patient safety and professional integrity. In prosthodontics, medicolegal aspects primarily deal with ensuring the standard of care, maintaining patient rights and avoiding malpractice. This review highlights key medicolegal aspects, including informed consent, negligence, and the ethical responsibilities of prosthodontists. It shows the importance of thorough documentation, effective communication, ethical issues and adherence to standards of care to mitigate malpractice risks.

Keywords: Prosthodontics, Medicolegal Aspects, Informed Consent, Negligence, Ethics.

INTRODUCTION

Prosthodontics is a dental specialty that focuses on creating, designing, and fitting artificial replacements for teeth and other oral structures. It plays a vital role in restoring a patient's oral function, aesthetics, and overall quality of life. Like any other medical or dental discipline, prosthodontics must adhere to a range of medicolegal guidelines to ensure patient safety, maintain professional integrity, and protect both patients and practitioners from potential disputes.[1] The medicolegal framework in prosthodontics covers various aspects, such as forensic identification, ethical standards, and issues related to malpractice. Awareness of these legal considerations is essential for dental professionals to navigate the legal landscape effectively.[2] Prosthodontists contribute significantly to forensic dentistry by helping to identify individuals when natural teeth are replaced with prosthetic devices. Properly labelled dentures and appliances, along with thorough documentation, can greatly assist in forensic investigations.[3]

Trust is the foundation of the relationship between dental practitioners and their patients, which requires adherence to high ethical standards. Any negligence or lack of care can lead to serious legal consequences, highlighting the importance of understanding medico-legal responsibilities in clinical practice.[1] Prosthodontic procedures, including the use of crowns, bridges, and dentures, can sometimes result in complications that lead to

Author's Affiliations: [1,2]Senior Resident, [3]Professor, [4]Professor & Head, Department of Prosthodontics, Thai Moogambigai Dental College and Hospital, Chennai, India.

Corresponding Author: R. Kanishka, Senior Resident, Department of Prosthodontics, Thai Moogambigai Dental College and Hospital, Chennai, India.

E-mail: kanishkaramesh2929@gmail.com

Received on: 26.08.2024

Accepted on: 29.10.2024

This work is licensed under a Creative Commons Attribution-NonCommercial-ShareAlike 4.0.

malpractice claims. To minimize these legal risks and ensure patient safety, practitioners must be aware of the standards of care and potential issues in their field. In addition to addressing these legal concerns, it is essential to promote a culture of professionalism and ethical practice to reduce the risk of malpractice and strengthen patient trust.[4] The medicolegal considerations in prosthodontics also encompass aspects like informed consent, adherence to accepted standards of care, detailed documentation, and effective communication with patients. By understanding these responsibilities, prosthodontists can not only protect themselves from legal challenges but also uphold a high standard of care, enhancing the trust and confidence that patients place in their expertise.[5] This article provides an overview of the key medicolegal aspects of prosthodontics.

Informed Consent

Informed consent is a critical aspect of prosthodontic treatment, ensuring that patients are well-informed and fully understand their treatment options before proceeding with any prosthetic interventions, such as removable partial dentures (RPD), fixed partial dentures (FPD), implants, complete dentures (CD), or maxillofacial prostheses. This principle mandates that patients receive comprehensive information to make autonomous decisions regarding their treatment.[6]

THAI MOOGAMBIGAI DENTAL COLLEGE AND HOSPITAL

DR. MGR EDUCATIONAL AND RESEARCH INSTITUTE

DEPARTMENT OF PROSTHODONTICS

INFORMED CONSENT

I _____ aged _____ give my consent to participate in the **study to evaluate the bite force in conventional complete denture and single implant supported complete denture.** The procedure will be performed by **Dr. Anirudh V B** and such other dental student or staff as they may in their discretion to act for or assist them under supervision. The relevant risks, complications and alternatives have been explained to me in the language of my understanding. I also consent to the additional /alternative procedures as in the opinion of dental staff performing the procedure mentioned above are considered necessary for maintaining the oral health. It has been explained to me that **satisfactory result** is expected and the possible complications that may occur from both known and unforeseen causes like **Loss of Prosthesis, Fracture of Prosthesis, Staining of the prosthesis and/or Failure of Dental Implants.** I understand that the material used for the fabrication of denture and the material used for implant are both **biocompatible and safe** with no allergic reactions reported. I also understand that I will be evaluated post operatively on the day of insertion of the prosthesis and at 1 month and 3 months and will also be evaluated on the day of loading of the Implant, 1 month post loading and 3 months post loading. I am also aware that my data will be used for publishing the above mentioned research. The Study participants will be given travel expenses and the materials used for the study will be provided free of cost.

_____ஆகிய நான். வயது_____ என் செயற்கை பல்லின் கடி சக்தியை மதிப்பிடுவதற்கான ஆராய்ச்சியில் பங்கேற்க என்னுடைய சம்மதம் தருகிறேன். இந்த செயல்முறையை டாக்டர் அனிருத். மற்றும் பிற பல் மருத்துவ மாணவர் அல்லது பணியாளர்கள் தங்கள் விருப்பப்படியோ அல்லது அவர்கள் மேற்பார்வையின் கீழ் செயல்பட உதவலாம். மேலே குறிப்பிட்டுள்ள ஆராய்ச்சியின் தொடர்புடைய அபாயங்கள் மற்றும் சிக்கல்கள் பற்றி எனக்கு விளக்கப்பட்டுள்ளது. வாய் ஆரோக்கியத்தைப் பேணுவதற்கு மேற்கூறிய நடைமுறையைச் செய்யும் பல் மருத்துவர்களின் கருத்துப்படி. கூடுதல்/மாற்று நடைமுறைகளுக்கு நான் சம்மதிக்கிறேன். திருப்திகரமான முடிவு எதிர்பார்க்கப்படுகிறது என்றும். அறியப்பட்ட மற்றும் எதிர்பாராத காரணங்களால் செயற்கை பல் முறிவு. செயற்கை பல் கறை படிதல் மற்றும்/அல்லது பல் உள்வைப்புகள் தோல்வி போன்ற காரணங்களால் ஏற்படக்கூடிய சாத்தியமான சிக்கல்கள் எனக்கு விளக்கப்பட்டுள்ளன. ஆராய்ச்சி ஆய்வுக்கு பயன்படுத்தப்படும் பொருட்கள் உயிர் இணக்கத்தன்மை கொண்டவை மற்றும் ஒவ்வாமை எதிர்வினைகள் எதுவும் இல்லாமல் பாதுகாப்பானவை என்பதை நான் புரிந்துகொள்கிறேன். செயற்கைப் பற்களைச் செருகிய நாள். முதல் மாதம் மற்றும் மூன்றாவது மாதம் எனது செயற்கைப் பற்களின் கடி சக்தி மதிப்பீடு செய்யப்படும். இதற்கு பின் என் செயற்கை பல் உள்வைப்போடு சேர்த்த பிறகு என் கடி சக்தியை அதே நாள். முதல் மாதத்திற்கு பிறகு மற்றும் மூன்றாவது மாதத்திற்கு பிறகு மதிப்பீடு செய்யப்படும். மேலே குறிப்பிட்டுள்ள ஆராய்ச்சியை வெளியிடுவதற்கு எனது தரவு பயன்படுத்தப்படும் என்பதையும் ஆய்வில் பங்கேற்பவர்களுக்கு பயணச் செலவுகள் வழங்கப்படும் மற்றும் ஆய்வுக்கு பயன்படுத்தப்படும் பொருட்கள் இலவசமாக வழங்கப்படும் என்பதையும் நான் அறிவேன்.

Signature of the Patient Witness Signature

Signature Of The Operating Surgeon Date :

Fig 1: Informed Consent Form

For prosthodontists, the process of obtaining informed consent includes several essential components: assessing the patient's mental capacity to understand and make informed decisions about their care, and ensuring that the patient fully comprehends the details of the proposed treatment. The consent process should be well-documented, either through written consent forms or detailed verbal agreements, to confirm that the patient has been properly informed and agrees to proceed with the treatment.[4]

Prosthodontists are obligated to provide thorough information about the procedure, including its risks, benefits, alternative treatment options, and potential outcomes, to ensure that patients are fully aware of what the treatment involves. It is crucial that the patient is competent to provide consent, meaning they must be capable of understanding the information and making a rational decision. If a patient lacks the necessary competence, a legally authorized representative must give consent on their behalf.[1,5]

In prosthodontics, explicit consent is often required for more complex or high-risk procedures, and this consent can be either oral or written, depending on the procedure's complexity and institutional guidelines. Implied consent might be acceptable for routine or minimally invasive treatments where the patient's actions suggest agreement, although this approach is less common in surgical settings due to the procedures' nature. Properly obtaining and recording informed consent is vital for protecting patient autonomy and upholding ethical standards in medical practice.[6]

NEGLIGENCE

Negligence refers to the failure of a dental professional to provide a reasonable standard of care and skill in treatment, resulting in harm or risk to the patient's health. This lack of care could stem from either an unintentional oversight or a deliberate act of negligence by the prosthodontist. For a patient to successfully claim negligence, certain conditions must be met, including establishing that the prosthodontist owed a duty of care, there was a breach of that duty, the patient suffered actual harm, and the breach of duty was the direct or proximate cause of the injury. Dental professionals, including prosthodontists, are responsible not only for their own acts of negligence but also for those of others under their supervision if they fail to report or intervene in negligent practices. The legal framework, as interpreted by courts, especially the Supreme Court, views negligence in the healthcare sector from a more nuanced perspective, emphasizing that mere accidents or lack of desired outcomes do not automatically constitute negligence if the treatment approach aligns with standard practices accepted by the profession.[7]

For instance, in prosthodontics, if a dentist uses a treatment method that is widely accepted within the field, they cannot be held liable simply because another treatment option was available. Non-negligent acts in prosthodontics may include not obtaining consent in emergencies, patient dissatisfaction with treatment progress, failure to achieve desired outcomes, or patient non-compliance with prescribed care. Furthermore, the charges perceived as excessive by the patient or prioritization of urgent cases over others do not necessarily constitute negligence. A prosthodontist may be held liable for negligence if they lack the requisite skills they claimed to possess or fail to apply their skills competently. It is the patient's responsibility to prove that they suffered damage due to negligence. Common scenarios that may lead to negligence claims in prosthodontics include foreign objects like amalgam or broken instrument fragments left in the tooth socket, accidental ingestion of dental appliances, or inadequate response during a medical emergency such as cardiac arrest during treatment. Properly addressing these potential risks through adherence to standard procedures and diligent patient care is crucial to minimizing liability in prosthodontic practice.[8]

The legal framework for handling negligence in prosthodontics involves the Civil Procedure Code, Criminal Procedure Code, and the Indian Evidence Act, which outline the procedures for presenting cases and establishing the burden of proof. Remedies for negligence may include compensation for civil wrongs, enforcement of specific performance in cases of contractual breaches, and punitive actions under criminal law for more serious offenses. Additionally, statutory liabilities can result from failing to comply with regulations, such as those outlined in the Clinical Establishment Act.[9]

Four Pillars of Medical Ethics

Table 1: Pillars of Medical Ethics

Pillar of Medical Ethics	Definition	Key Aspects	Challenges
Beneficence	Acting for the benefit of patients, emphasizing the Hippocratic Oath's guidance.	- Specific beneficence focuses on individual patient care. - General beneficence aims at societal welfare. - Requires healthcare providers to continually update their skills and consider unique patient needs. - In oral and maxillofacial surgery, beneficence includes respecting patient autonomy while actively promoting well-being.	- Compromise in patient safety when tasks are transferred to less skilled staff or trainees. - Best achieved when the responsible clinician oversees procedures to maintain high standards of care.
Non-Maleficence	The principle of "First do no harm" or avoiding harm to the patient.	- Procedures should aim to prevent harm to both the patient and society. - Physicians have a duty to inform patients about their condition, treatment options, risks, and prognosis. - Informed consent must be obtained from patients with the capacity to understand.	- Limited success rates in certain treatments, like infertility procedures, can lead to emotional distress, challenging the full application of this principle. - Paternalistic approaches conflict with patient autonomy, undermining the principle of non-maleficence.
Autonomy	Respecting a patient's right to self-governance and decision-making.	Patients should make informed decisions free from coercion. - Key rules include truth-telling, confidentiality, and ongoing informed consent. - Encourages open communication between patient and clinician regarding treatment options, risks, and outcomes	Traditional paternalism in clinical settings may hinder respect for patient autonomy. - Practitioners may still exhibit a superior attitude, assuming they know better than the patient.
Justice	Fair distribution of healthcare benefits and burdens across all societal groups.	Ensures medical procedures and resources are allocated equitably. - Adheres to legal standards and considers competing needs, rights, and obligations. - Distributive justice theories include Utilitarianism, Libertarianism, Communitarianism, and Egalitarianism	Disparities in care due to uneven access to resources and technologies. - Unjust treatment of patients based on socioeconomic status or educational background. - Mistreatment of staff or neglecting professional duties undermines fairness in healthcare

Source: CM Francis - Medical Ethics, 2nd Edition, Common Errors in Prosthodontics: Causes and Implications

Common errors in prosthodontics include tissue damage caused by overextended borders, improper denture fitting, or excessive pressure during impression taking, leading to irritation or sores. Local anesthesia errors, such as incorrect injection techniques or inadequate numbing, can result in discomfort or procedural challenges. Impression errors, including the use of inappropriate materials or techniques, may produce distorted or inaccurate impressions. Occlusal issues, like improper adjustments or inaccurate jaw relation records, can lead to poor fit, discomfort, or functional problems. Material handling errors, such as improper mixing, setting, or curing, may compromise the quality of the prosthesis. Aesthetic failures, due to poor shade selection or alignment, can impact the natural appearance of the prosthesis. Additionally, insufficient patient instructions on cleaning and maintenance may lead to prosthesis damage or oral health issues. These errors highlight the importance of precision, proper technique, and personalized care in prosthodontics.[12]

Table 2: Prosthodontic Negligence

Thermal Sensitivity	Pulpal discomfort from temperature change is frequently encountered following cementation of fixed partial dentures 1. The temporary restoration which don't cover all prepared tooth surfaces 2. A loose temporary restoration that allows seepage, of oral fluids over the prepared surfaces 3. A temporary restoration that places excessive occlusal forces on the prepared teeth[10]
Discomfort during Function	Pains during chewing due to premature centric or excessive contact during eccentric mandibular movement.[11]
Gingival Inflammation	Occurs post cementation of prosthesis. This can occur as a result of faulty cervical contour, marginal fit, or embrasure form. Even inadequate oral hygiene aids could cause food retention & inflammation.[12]
Retention of Food	This occurs usually around pontics and connectors. This cannot be completely avoided but proper oral hygiene measures help in removing the food.[13]
Trauma to the cheek or Tongue	Cheek and tongue are the common areas of trauma due to poorly polished portions of the prosthesis. Pontics when placed in areas in which the tongue and cheek were previously not restricted or when flanges of dentures are sharp or cusp-to-cusp or ends -lo-end occlusal relationship without normal horizontal overlap is present.[14]
Sensitivity of Sweets	This occurs when the prepared tooth is not completely covered by the final prosthesis. Sweet sensitivity occurs when the luting agent has undergone dissolution or if the abutment retainer is loose.[15]
Tooth Mobility	Occurs due to poor occlusal relationships, overloading of prosthesis affecting the periodontal ligament and supporting bone causing excessive movement.[16]
Neuromuscular Discomfort	Pain in the temporomandibular joint & associated muscles occurs due to improper occlusion created by a prosthesis. The discomfort caused by occlusal contact on the prosthesis, causing the patient to habitually brings other teeth into a different position. The new mandibular position can create neuromuscular pain in such patients as a result of positional changes in the ligaments and muscles associated with the temporomandibular joint. It must be recognized that other factors may cause pain.[17]
Nonspecific Complaints	Like feels different or slightly uncomfortable this is due to an additional force applied to the abutment teeth, a slight occlusal discrepancy, or simply the presence of an artificial tooth. Like feels different or slightly uncomfortable this is due to an additional force applied to the abutment teeth, a slight occlusal discrepancy, or simply the presence of an artificial tooth.[18-21]

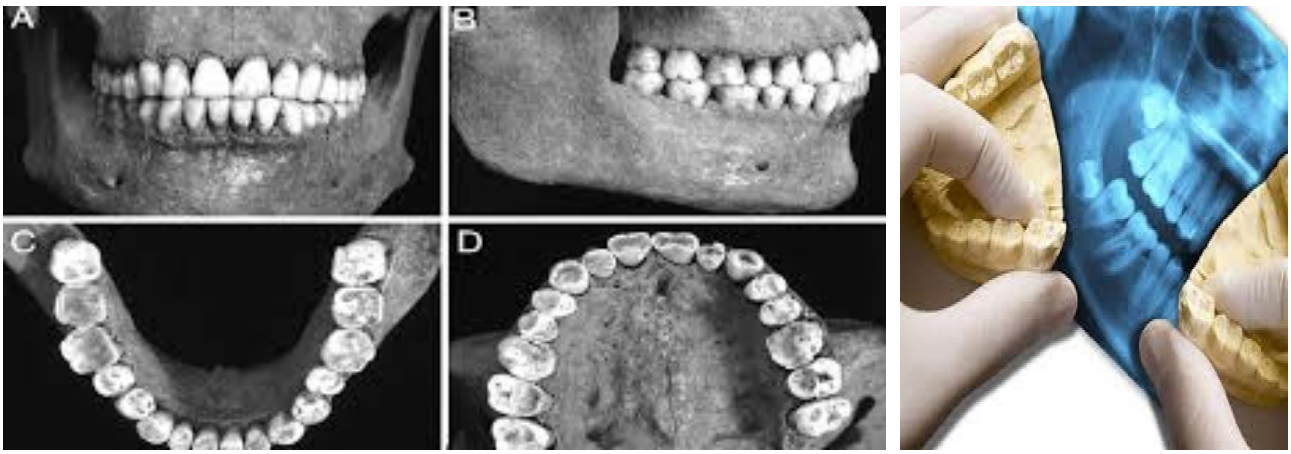

Fig 2: Forensic Odontology and Prosthodontics

Forensic odontology and prosthodontics intersect significantly in forensic cases, where prosthodontists can use their knowledge of dental materials and prosthetic appliances to assist in the identification of deceased individuals. Medical ethics in forensic odontology involves guiding principles that uphold human rights and professional responsibility, ensuring that the dignity of the deceased is respected through accurate identification, which aids grieving families. The ethical obligation to identify every deceased person is reinforced by organizations like the Association Forensic Odontology for Human Rights (AFOHR), which emphasizes the human rights of the dead and the importance of quality age determination. Forensic odontologists must maintain high ethical standards to positively contribute to the judicial system, handling ethical dilemmas and respecting the deceased's dignity, as they work within a framework that demands careful consideration of bioethics and legal implications. Forensic dentists are responsible for maintaining accurate records and conducting thorough dental autopsies, as failure to do so can violate the rights of the deceased.

Additionally, prosthodontists aid in identification through marking prostheses with inscriptions, embedding radio-frequency identification (RFID) tags, collecting DNA from prosthetic appliances, studying rugae patterns (rugoscopy), and recording lip prints. These techniques support identification in situations where traditional methods, such as fingerprints, may not be available, such as aviation disasters. This ethical framework in forensic odontology not only emphasizes respect for the deceased but also highlights the balance needed between legal obligations and ethical responsibilities, especially in complex cases involving vulnerable populations.[22,23]



Denture labelling

Fig 3: Labelling of Denture

Denture labelling is an important practice for several reasons. It aids in the identification of victims in disasters, helps locate misplaced dentures in institutions, and assists in identifying individuals who have lost consciousness or memory. In some countries, like Sweden and Iceland, denture marking is even legally mandated. The labelling process involves discreetly marking dentures with a unique identifier, such as a patient's name, ID number, or a combination of both. This information can be etched onto the denture or embedded within the material. The most suitable areas for marking are often the lingual and palatal surfaces of the posterior teeth, as these areas are less likely to be damaged in case of accidents or fires. While denture labelling is not a universal practice, it is gaining recognition as an ethical responsibility for dental professionals. It is particularly crucial in cases of mass disasters or when dealing with unidentified remains.

Denture marking methods include engraving, which involves marking during fabrication but risks tissue irritation and loss of marks due to grinding; scribing, where marks are added post-fabrication using sharp tools; writing, which involves roughening the posterior flange, marking patient details, and sealing with nail polish; and inclusion, where labeled materials such as metallic, non-metallic, or microchips are embedded into the denture by replacing a portion of pink acrylic with clear acrylic, making the identification permanent.

By implementing denture labelling, dental professionals can significantly contribute to the identification process and provide closure

to families of missing individuals. Despite the absence of broad legislation, it is viewed as a social and ethical responsibility for dental practitioners to label dentures. Notably, the Highland Towers disaster highlighted the challenge of identifying edentulous victims with unmarked dentures. Proposed improvements include adding country codes or identification numbers, and labelling in areas like the lower lingual posterior and upper palatal posterior where dentures often survive incineration. Marking should extend beyond acrylic to cobalt-chromium dentures, which resist melting, and can include orthodontic and reconstructive appliances. An Indian study found patient education and background influence receptivity to denture marking, contrasting with higher acceptance in Europe.[24,25]

Table 3: Denture Marking Methods

Method	Description	Pros	Cons
Scribing/Engraving	Engraving letters or numbers on the denture surface using a dental bur.	Economical, easy to operate	Food entrapment, bacterial infection, irritation
Embossing	Scratching patient details on the master cast to produce stamped or embossed letters on the denture surface.	Economical	Malignancy risk due to tissue irritation
Denture Bar Coding	Machine-readable code printed as bars and spaces on the denture, can withstand high temperatures.	Exact info, works in fire/water damage	Expensive special equipment required
Lenticular Card	A lens-based system creating images with depth and morphing properties for patient identification.	Cheap, stores large info, no fading	Limited to viewing angle for information
ID Band	Stainless steel band with patient details embedded in a shallow recess of the denture base.	Permanent, secure	Requires precise fabrication
Paper Strip	Typed paper placed on the acrylic resin surface, then covered with clear resin.	Economical	Can degrade over time, less durable than other methods
T-Bar	A T-shaped clear resin bar with an embedded printed label.	Easy, inexpensive, time-effective	Requires careful processing
Laser Etching	Copper vapor laser etches patient information on the denture surface.	Durable, precise	Expensive, requires specialized equipment and technicians
Electronic Microchips	Microchip (5x5x0.6 mm) embedded in the denture containing patient info.	Durable, high-tech	Manufacturer-only inscription, expensive
Photographic	A photograph embedded into the denture using clear acrylic resin.	Good for low literacy areas	Sensitive to high temperatures, not very durable
RFID Tags	Radio-frequency identification tag embedded, stores large user data and is easily read with a handheld device.	Small, reliable, resistant to disinfectants	Requires specialized reader for access

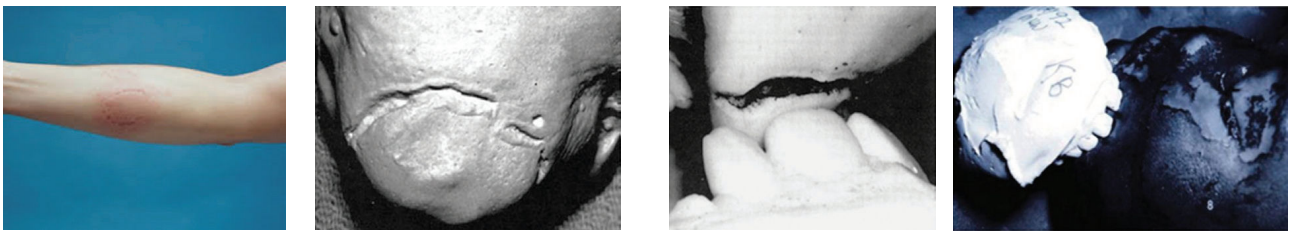

Fig. 5: Bite Marks

Bite Marks for Rape Victims

Bite marks, a specialized form of forensic evidence, not only provide valuable information about the dental characteristics of a suspect but also offer insights into their psychological profile. In sexual assault cases, including rape, bite marks are significant as they often reflect indicators of violence, struggle, or control, helping to clarify key aspects of the incident. The process of bite mark analysis for victims involves meticulous documentation and collection. High-resolution photographs from multiple angles, including close-

up and contextual views, are taken to record the bite mark's size, shape, and placement on the body. Dental impressions may also be created to capture a 3D model if the bite marks are distinct enough, while swabs from the bite mark area are collected to potentially obtain the assailant's DNA. Analysis and identification involve comparing these unique bite patterns with the suspect's dental records, where forensic odontologists examine details like tooth shape, alignment, spacing, and bite force to either match or exclude suspects.

In some cases, digital enhancements are used to amplify image clarity, highlighting specific features or allowing overlays with the suspect's dental pattern. The interpretation of bite marks, especially in terms of their patterns and placement, can suggest intent such as control or aggression and assist in reconstructing the sequence of events. However, interpretation is complex since skin elasticity and healing processes can alter a bite mark's appearance. Bite mark analysis is typically used in conjunction with other evidence, such as DNA, eyewitness accounts, and physical findings, to build a comprehensive case. Often left on victims during assaults, bite marks can manifest aggression and dominance, as noted by Sunil et al. and Yadav & Srivastava Forensic dentists find these marks useful in suspect identification since no two individuals have identical dental patterns, Successful convictions, particularly in cases of rape and child abuse, have often hinged on bite mark evidence.[26-28]

Tooth calcification and Age Estimation

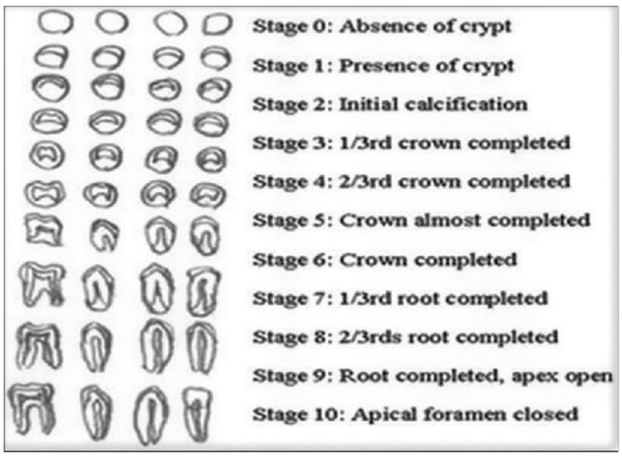

Fig. 6: Tooth Calcification by Nollan

Tooth calcification stages can reveal an individual's age, which is crucial in forensic contexts Additionally, the development and wear patterns of teeth offer supplementary data for age estimation, enhancing bite mark analysis (Shah et al., 2019). Tooth calcification and age estimation are highly relevant in the medicolegal aspects of prosthodontics, playing a crucial role in patient identification, age verification, and legal documentation. In forensic cases, prosthodontists may use calcification stages to assist in identifying unidentified remains, particularly when combined with analysis of dental records, prosthetics, or restorations. Age estimation also aids in verifying the legal eligibility of patients for specific prosthodontic treatments, ensuring consent compliance and reducing malpractice risks. Accurate dental records, including age-related developmental information, are essential for legal documentation and can serve as evidence in disputes or malpractice claims. Additionally, tooth calcification stages guide age-appropriate treatment planning, particularly in younger patients, to avoid complications arising from ongoing growth.

In cases involving insurance or compensation, age assessment supports prosthodontists in providing documentation to verify treatment eligibility. In forensic prosthodontics, prosthetic devices combined with age estimation from natural teeth can help create comprehensive profiles for identification. Together, these applications make tooth calcification and age estimation vital to the medicolegal field of prosthodontics, where they enhance patient care, compliance, and legal accountability.[29]

Age Estimation by Tooth Morphology

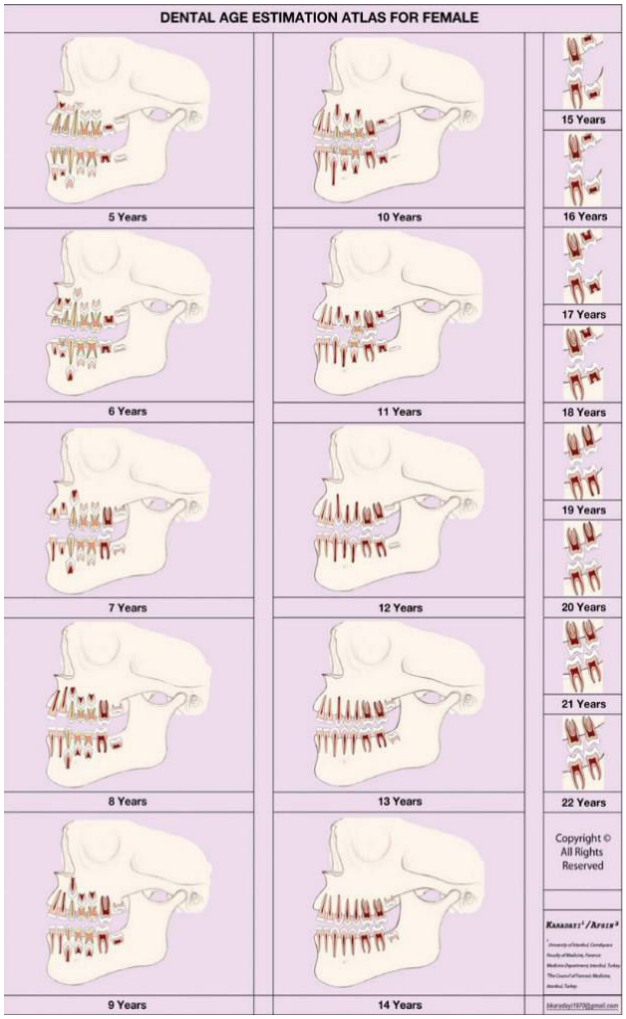

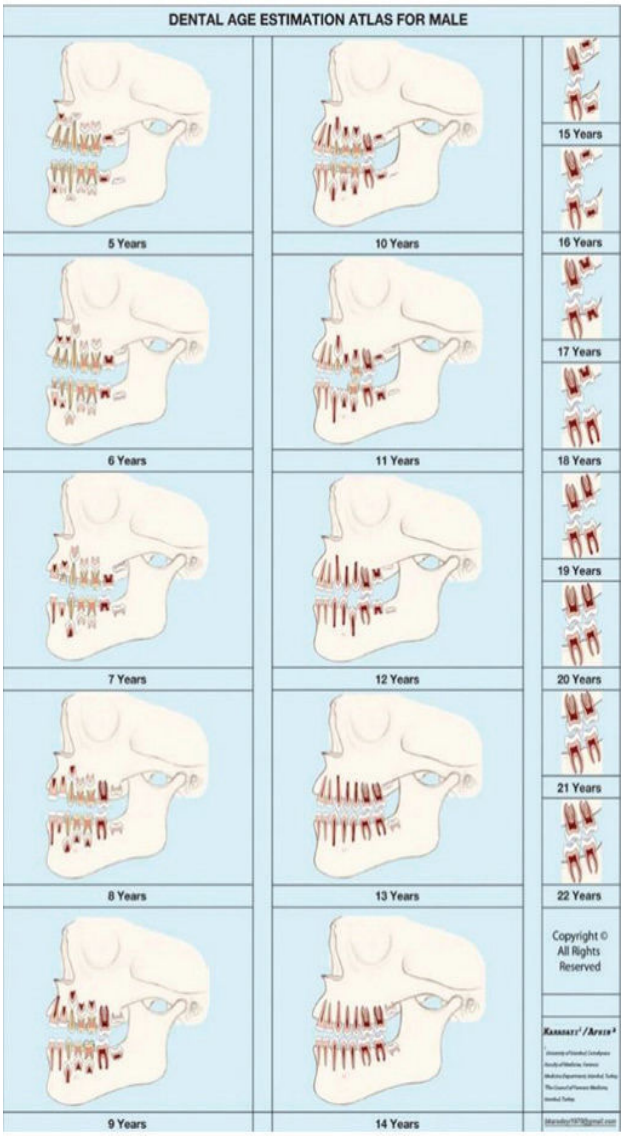

Fig 7: Age Estimation by Tooth Morphology

The unique morphology of teeth aids in personal identification and can also reflect the age bracket of the assailant. Variations in dental structure can be critical in distinguishing between suspects in criminal cases. Age estimation by tooth morphology is a valuable tool in forensic and anthropological contexts, relying on distinct patterns in tooth development, eruption, and wear. Teeth progress through predictable developmental stages, with crown and root formation indicating specific age ranges, making them especially useful in estimating age in children and adolescents.

Eruption patterns provide additional clues, as each type of tooth erupts in a particular sequence tied to age. Root formation, particularly in wisdom teeth, and closure stages assist in age approximation for young adults. In adults, natural wear and tear, such as enamel thinning and attrition, serve as indicators of aging, while the deposition of secondary dentin over time reduces pulp size, adding another dimension to age assessment. Additionally, cementum annulation, the layering of cementum on the tooth root, forms annual rings that can be counted to determine age, similar to tree rings, although this method requires microscopic analysis. Together, these morphological characteristics enable accurate age estimation across different life stages, especially when used alongside radiographic methods for detailed examination.[30]

Bharatiya Nyaya Sanhita (BNS) section for dentists

Section 106 of the Bharatiya Nyaya Sanhita (BNS) redefines medical negligence, directly impacting healthcare professionals, including dentists, by imposing stricter punishments for negligence that results in patient death. This section replaces IPC Section 304A, raising imprisonment for non-culpable homicide to up to five years, while registered medical practitioners face two years' imprisonment and a fine. Dentists and other registered practitioners are particularly concerned, as this stricter interpretation may incite fear of legal repercussions, potentially discouraging them from performing high-risk procedures or emergency treatments that could benefit critically ill patients.

Dentists, like other medical professionals, argue that unintended adverse outcomes are sometimes unavoidable despite adherence to standards of care and patient consent. The BNS also omits preliminary inquiries in complex cases of alleged negligence, potentially increasing vulnerability to unsubstantiated claims and impacting dental practices that involve invasive procedures. Furthermore, while the SC has previously required a prima facie review from medical authorities before prosecuting professionals, BNS lacks clarity on this, which adds to healthcare practitioners' concerns. Dental professionals advocate for clearer guidelines, preliminary investigations in complex cases, and protections to enable productive and fearless practice, ensuring they can confidently perform critical procedures without undue legal risk. [31]

CONCLUSION

The medicolegal landscape of prosthodontics is complex and multifaceted, assessing the importance of proactive strategies to minimize the risk of litigation. To effectively avoid malpractice claims,

practitioners should prioritize maintaining clear documentation, which includes detailed records of patient examinations, treatment plans, informed consent discussions, and treatment outcomes. This thorough documentation can be crucial in defending against potential claims. Effective communication with patients is equally vital; fostering open and honest dialogues helps build trust and can prevent misunderstandings that may lead to disputes. Additionally, staying updated on best practices through continuous education ensures that dental care aligns with current standards, enhancing the quality of treatment provided. Lastly, carrying professional liability insurance offers financial protection in the event of a malpractice claim, further safeguarding the practitioner's interests. By understanding the potential legal issues, ethical considerations, and strategies for avoiding litigation, dentists can protect themselves and their patients while delivering high-quality care, ultimately enhancing the overall effectiveness of prosthodontic treatment.

REFERENCES

1. Sykes, D. (2000). 8. Medico-legal aspect of dental implants.. Annals of the Royal Australasian College of Dental Surgeons
2. Cruz L. Legal aspects of general dental practice. Churchill Livingstone; 2006
3. Sachin, John., Rohit, Raghavan., Shajahan, P, A. (2022). 1. The decisive role of prosthodontics and its invaluable contribution to forensic odontology: A review. IP Annals of prosthodontics and restorative dentistry, doi: 10.18231/j.aprd.2022.028
4. Medha, Sansanwal., Deepshikha, Sansanwal., Shaifaly, Chouhan. (2020). 3. Medico legal perspective in dentistry. doi: 10.18231/J.IDJSR.2020.018
5. Paul G. Medical Law for dental surgeon. Jaypee Digit. 2004;(5):29
6. Booth S. A philosophical analysis of informed consent. Nurs Stand. 2002 Jun 12-18; 16(39): 43-46. https://dx.doi.org/10.7748/ns2002.06.16.39.43.c3211
7. Goel K, Goel P, Goel S. Negligence and its legal implications for dental professionals: a review. TMU J. 2014;1(3):113–8.
8. Worthington, P. (1995). Medicolegal aspects of oral implant surgery
9. Upendra, Singh, Bhadauria., Pralhad, L, Dasar., N, Sandesh., Prashant, Mishra., Shaijal, Godha. (2018). 4. Medico-legal Aspect of Dental Practice. doi: 10.15386/CJMED-764
10. Mohammad, Zakaria, Nassani. (2017). 5. Aspects of Malpractice in Prosthodontics.. Journal of Prosthodontics, doi: 10.1111/JOPR.12636
11. Manas, Gupta., Kirti, Shrivastava., Sunil, Kumar, Mishra., Ravish, Ahuja., Pankaj, Mishra., Shail, Kumari. (2018). 6. Importance and awareness of medico legal issues in dental practice… Alarm call. Annals of Tropical Medicine and Public Health, doi: 10.4103/ATMPH.ATMPH_317_17
12. P, Ghimire., Pramita, Suwal., Bishal, Babu, Basnet. (2022). 7. Management of Medically Compromised Prosthodontic Patients. International Journal of Dentistry, doi: 10.1155/2022/7510578
13. Sahoo PK, Priyadarshini SR, Sahoo KK. Dental negligence during prosthetic treatment. J Forensic Med Toxicol. 2020;14(4):
14. Mário, Marques, Fernandes., Rachel, Lima, Ribeiro, Tinoco., Talita, Lima, de, Castro., Luiz, Renato, Paranhos., Luiz, Francesquini, Júnior., Eduardo, Daruge, Júnior. (2014). 9. Failures in dental prosthesis: dentists perception of the involved legal aspects. Acta Scientiarum. Health Science, doi: 10.4025/ACTASCIHEALTHSCI.V36I1.16851
15. Markose A, Krishnan R, Ramesh M. Medical ethics. J Pharm Bioallied Sci. 2016 Oct;8(Suppl 1):S1-S4. doi: 10.4103/0975-7406.191934. PMID: 27829735; PMCID: PMC5074007.
16. Lopez-Nicolas M, Falcon M, Perez-Carceles MD, et al: Informed ´ consent in dental malpractice claims. A retrospective study. Int Dent J 2007;57:168-172
17. Kelleher M: Ethical issues, dilemmas and controversies in 'cosmetic' or aesthetic dentistry. A personal opinion. Br Dent J 2012;212:365-367
18. Bowley J: Minimal intervention prosthodontics: current knowledge and societal implications. Med Princ Pract 2002;11(Suppl 1):22-31
19. Lynch CD, Allen PF: Quality of communication between dental practitioners and dental technicians for fixed prosthodontics in Ireland. J Oral Rehabil 2005;32:901-905
20. Rene N, Owall B: Malpractice reports in prosthodontics in ´ Sweden. Sweden Dent J 1991;15:205-217
21. Carlsson GE, Omar R: Trends in prosthodontics. Med Princ Pract 2006;15:167-179
22. Gosavi S, Gosavi S. Forensic odontology: A Prosthodontic view. J Forensic Dent Sci. 2012;4:38–41. doi: 10.4103/0975-1475.99162
23. MacEntee MI, Campbell T. Personal identification using dental prostheses. J Prosthet Dent. 1979;41:377–80. doi: 10.1016/0022-3913(79)90032-5.
24. Shimoyama K, Ogawa N, Umino M, Nagao M, Odagiri K. The need for a denture marking

system in geriatric institutions. J J Gerodont. 13–7:8;1992.

25. Acharya AB, Anehosur GV, Kanchi PP, Naik MG, Nadiger RK. Perceptions and preferences on denture marking in an Indian sample. Gerodontology. 2012;29:117–24.
26. Afsin H, Karadayi B, Cagdir SA, Ozaslan A. Role of bite mark characteristics and localizations in finding an assailant. J Forensic Dent Sci. 2014 Sep;6(3):202-6. doi: 10.4103/0975-1475.137078. PMID: 25177145; PMCID: PMC4142413.
27. Mysore, K, Sunil., Upender, Malik., Sourav, Malhotra., Arishah, Gulzar., Radhika, Sharma. (2 .(2019. Bite Marks: An Indispensible Tool for Forensic Odontological Evidence. Medico-Legal Update, doi: 10.37506/MLU.V19I1.880
28. Nidhi, Yadav., P., C., Srivastava. (2014). 3. Bite Marks: An Indispensible Forensic Odontological Evidence in Rape Cases. Journal of Indian Academy of Forensic Medicine,
29. Preetam, Shah., Priyam, Rajesh, Velani., Laxmi, Lakade., Siya, Dukle. (2019). 1. Teeth in forensics: A review. Indian Journal of Dental Research, doi: 10.4103/IJDR.IJDR_9_17
30. Rakhee, Modak., Sandhya, Tamgadge., Amit, Mhapuskar., Manjula, Hebbale., N, Vasantha, Vijayarabhavan. (2016). 4. Bite mark analysis: Chasing the bite!. Journal of Oral Health Research, doi: 10.4103/2393-8692.196091
31. https://legalonus.com/section-106-of-the-bharatiya-nyaya-sanhita-bns-definition-of-medical-negligence/#google_vignette