Short Communication

Physiotherapy and Occupational Therapy Journal
Volume 17 Number 1, January - March 2024
DOI: http://dx.doi.org/10.21088/potj.0974.5777.17124.8

Clinical Commentary: Glenohumeral Internal Rotation Deficit (GIRD)

Sneha Vishwanath

How to cite this article:

Sneha Vishwanath. Clinical Commentary: Glenohumeral Internal Rotation Deficit (GIRD). Physio Ther Occup Ther J 2024;17(1): 77-80.

ABSTRACT

GIRD is a concept related to shoulder injury. It causes limitation in the range of motion. Shoulder joint plays an important role in throwing, serving or other activities related to shoulder. GIRD is an important pathology which should be considered for evaluation in sports palyers. Thus this clinical commentary speaks about this pathology GIRD.

Keywords: Internal rotation deficit; External rotation gain; Total range of motion.

INTRODUCTION

One of the important concepts related to shoulder injury like the loss of shoulder motion was thoroughly discussed in the context of the overhead athlete. Gleno-humeral internal rotation deficit (GIRD) in isolation is not a pathologic process. Throwers with GIRD frequently arrive at the clinic as a result of shoulder pathology developing. Intra-articular shoulder pathology (labrum, joint capsule, articular-sided rotator cuff), extra-articular shoulder pathology (bursal-sided rotator cuff, acromion), and pathology of the throwing kinetic chain (lower extremity, core, scapula, and elbow) comprise the pathologic process in throwing shoulders with GIRD. The overhead throwing motion is used in many common competitive and recreational sporting activities.

To be successful at pitching, both high velocity and accuracy have to occur repetitively, without causing injury to the soft tissues around the glenohumeral joint that aid in stabilisation and dynamic control.[1,2] Glenohumeral (GH) internal rotation deficit (GIRDis an adaptive process that results in IR loss in the throwing shoulder. As of right now, GIRD is identified by a 20° loss of IR relative to the contralateral shoulder. However, not every GIRD is pathogenic, and when the shoulders' total rotational motion (TRM) is symmetric, decreased IR (in comparison to nonthrowing shoulder) might exist without concurrent shoulder disease. The humerus's enhanced retrotorsion (decreased anteversion), which causes the arc of motion to move more posteriorly (externally), is partially to blame for this. On the other hand, pathologic GIRD occurs when TRM 5° is lost in relation to the contralateral shoulder.[2]

The change in motion that sportsmen who use the overhead throwing action experience is one of

Author Affiliation: Associate Professor, Department of Physiotherapy, Alva's College of Physiotherapy and research Centre, Alva's Health centre Complex, Mudbidri, Karnataka 574227, India.

Corresponding Author: Sneha Vishwanath, Associate Professor, Department of Physiotherapy, Alva's College of Physiotherapy and research Centre, Alva's Health centre Complex, Mudbidri, Karnataka 574227, India

E-mail: snehapt@gmail.com

Recieved on 02.01.2024 **Accepted on** 12.03.2024

© Red Flower Publication Pvt. Ltd.

these adaptations. To generate the strong rotational forces required to pitch the ball, for instance, the throwing shoulder may normally externally rotate around 180°, which is the amount of glenohumeral range of motion (ROM) obtained at the end of the cocking phase of throwing. The research has consistently identified this particular feature of the overhead throwing motion as a loss of shoulder glenohumeral IR and an increase in shoulder glenohumeral external rotation (ER). Nevertheless, the glenohumeral joint, scapulothoracic articulation, and extension of the spine's segments are among the kinematic chain parts that are utilised to accomplish the whole 180°. Pitchers experience this change in total arc of motion even when their bilateral TROM (i.e., sum of ER + sum of IR) is equal.[1]

MEASUREMENT TECHNIQUE[1,2]

Athletes that use the overhead throwing motion experience one of these adaptations a shift in motion. Typically, the throwing shoulder may rotate externally to a maximum of 180°, which is the glenohumeral range of motion (ROM) obtained at the end of the cocking phase of throwing. This rotational force is necessary to pitch the ball.

A common finding in patient groups and in overhead athletes like professional and amateur baseball pitchers, softball players, and tennis players is the selective loss of IR shoulder motion on the dominant extremity. A bubble inclinometer or a normal goniometric technique can be used to test shoulder range of motion. The fulcrum of the goniometer technique is positioned above the olecranon process.

The patient should be positioned supine with the elbow extended to 90° and the shoulder at 90° of abduction in the scapular plane (10–15° anterior to the coronal plane) in order to assess shoulder IR. The forearm is positioned vertically to start. The glenohumeral joint is then passively internally rotated by the examiner while gently palpating the coracoid process to stabilise the scapula, feel for motion, and reduce the amount of scapulothoracic contribution or compensatory movement that happens at the conclusion of IR motion. The measurement should be made when the scapula starts to shift into protraction and/or anterior tilt. (Fig. 1).

It is advised to use a towel roll or the clinician's supporting hand(s) to position the humerus consistently throughout the measurement to guarantee that it stays in the proper position.Three approaches to glenohumeral joint IR measurement have been examined by Wilk *et al*. These approaches are: no stabilisation; stabilisation with hand on front of shoulder; and C-shape stabilisation with fingers posteriorly and thumb on coracoid process. The stabilisation method that produced the optimal amount of scapular stabilisation and proved reliable in both intra-rater and inter-rater applications was the "C" shape type grasp, as illustrated.

The shoulder is normally positioned in the scapular plane (10–15° anterior to the coronal plane) and abducted to 90 degrees during measurement in order to assess shoulder ER. It is advised to use a towel roll or the clinician's supporting hand(s) to position the patient consistently so that the humerus stays in the desired position during the measurement. The forearm is positioned vertically (perpendicular to the support surface) to begin with. Next, while keeping the scapula stable, the examiner passively externally rotates the humerus. When resistance to additional mobility is felt and attempts to overcome it result in a posterior tilt or retraction of the scapula, the glenohumeral ER has reached its end range. (Fig. 2).



Fig. 1: Measurement of glenohumeral internal rotation



Fig. 2: Measurement of glenohumeral external rotation.

Any throwing athlete who presents with shoulder issues should be highly suspicious because GIRD is quite prevalent in overhead throwers. As a result, passive IR and TRM of the shoulder need to be evaluated in all throwers experiencing shoulder pain. The patient should lie supine on the examination table in order to evaluate loss of IR of the shoulder, according to the authors' suggested method. A goniometer can be used to evaluate the discrepancies between the throwing shoulder's Maximum Passive ER and IR and the contralateral extremity (Fig. 3).

Crucially, the moment shortly before the scapula starts to lift off the examination surface is the definition of maximum passive IR. A discrepancy of 20° or greater when compared to the contralateral side is typically seen as indicative of GIRD, however the precise criteria is up for debate. The shoulder's TRM is equal to the sum of its maximum ER and IR. For most athletes who throw their weight overhead, bilateral symmetry in TRM is ideal. This approach has been demonstrated to have more reproducibility and is unaffected by scapulothoracic or elbow motion, making it the preferred way for measuring IR instead of determining the vertebral level that can be reached when moving the arm up the back.

The Link Between Gird & Trom & Shoulder Injuries[1,2]

The TROM concept was first put forth by Wilk et al., in which a TROM arc is calculated by adding the amounts of ER and IR at 90° of abduction (Fig. 3). TROM is a useful evaluation instrument and a crucial part of the PROM throwers shoulder exam. Wilk *et al*. have proposed the idea of external rotation deficiency (ERD) recently.

The difference of fewer than five degrees between the external rotation of the throwing shoulder and the nonthrowing shoulder is known as an external rotation deficiency. Consequently, an ER difference of more than 5 degrees is anticipated when comparing a player's ER PROM from side to side. This would suggest that a player's ER gain on his throwing side is substantial enough to contribute to the demands of throwing, particularly during the late cocking phase of the pitching motion. A pitcher with ER side-to-side difference of <5 deg may impart increased stresses on the static glenohumeral stabilizers, thereby contributing to an increased risk of injury over the career of the athlete. Therefore, the authors believe TROM differences, especially where there is an insufficient

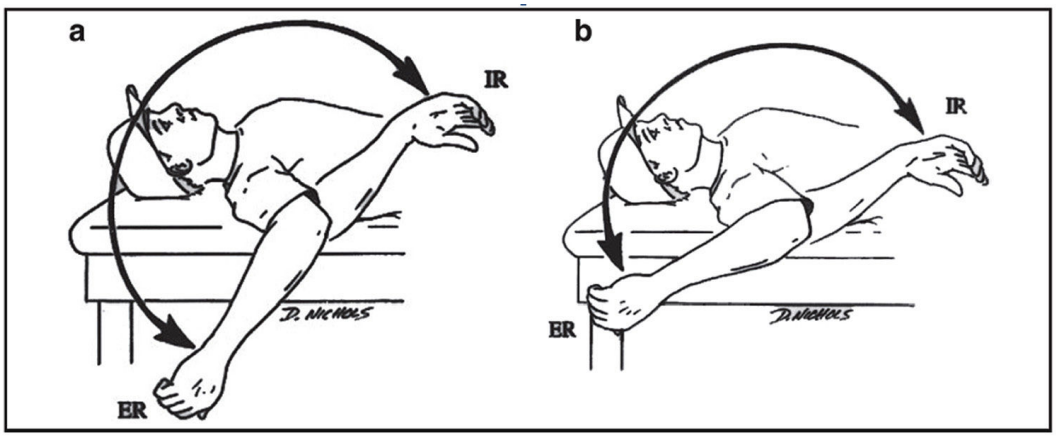

Fig. 3: a. Total range of motion (TROM) dominant shoulder, b. TROM, non-dominant shoulder.

ER PROM on the dominant side as compared to the non-dominant side, may put the pitcher at a higher risk for injury.

The leading pathologic process in GIRD is posterior capsular and rotator-cuff tightness, due to the repetitive cocking that occurs with the overhead throwing motion. Achieving increased ER in the maximally abducted position is thought to help increase throwing velocity. During pitching, biomechanical studies have shown shoulder ER can exceed 160°, IR acceleration can exceed 6,000°/second, and IR torque can exceed 60 N/m. These kinematic extremes place a high amount of stress on the static and dynamic stabilizers of the shoulder, including the rotator cuff, joint capsule, and labrum. With each pitch, these structures are loaded to levels that approach their ultimate load to failure, making them extremely vulnerable to injury. Although a single traumatic event can lead to a shoulder injury, more commonly it is repetitive overuse that leads to numerous pathologic conditions, including posterior labral tears, partial articular-sided posterosuperior rotator-cuff tears, and superior labral anterior-to-posterior (SLAP) tears. In addition to shoulder

pathology, patients also display scapular dyskinesia and are predisposed to ulnar collateral ligament (UCL) tears at the elbow.

CONCLUSION

In summary, if the overhead athlete has alterations of glenohumeral motion, a comprehensive examination must be performed to determine the direction of motion that is limited and the specific tissues that cause the limitation. In overhead athletes a limitation of glenohumeral motion is required to perform motions such as throwing and serving. This loss of motion is normal and not pathologic. In extreme cases glenohumeral motion may be restricted to the point of actually causing pathology. Then, the appropriate intervention to address identified limitations can be chosen from those presented in this commentary, which are provided based upon a review of the evidence, when available.

REFERENCES

1. Wilk E *et al*. The International Journal of Sports Physical Therapy 2013, October, Volume 8, Number 5, Page 537
2. Rose and Noonan. Open Access Journal of Sports Medicine 2018:9,69-78.