Review Article

International Journal of Neurology and Neurosurgery
Volume 14 Number 1, January – March 2022
DOI: http://dx.doi.org/10.21088/ijnns.0975.0223.14122.3

Covid-19 With Cerebrovascular Manifestations: Review of Literature and Case Series

Mukesh Patel[1], Himanshu Raval[2], Kalpesh Shah[3]

How to cite this article:

Mukesh Patel, Himanshu Raval, Kalpesh Shah/Covid-19 With Cerebrovascular Manifestations: Review of Literature and Case Series/Int J Neurol Neurosurg. 2022;14(1):23–28.

Abstract

Background: In year 2020, we are fighting with global threat of corona virus pandemic. It is more hazardous with its heterogeneous presentation involving all systems in body.

Objective: As corona virus having properties to produce cerebrovascular diseases via causing hypercoaguable state and possible endothelial damage, it is necessary to look this facet of its virulence. Here, we are presenting review of literature and case series of three patients having covid stroke, two of which having ischemic stroke and one of them is having hemorrhagic stroke.

Methods and Material: This study has been carried out at SVP hospital Ahmedabad which is designated covid care hospital in western India from March to august. With no proper etiopathogenesis established between covid-19 and stroke, this data is useful as obtained from dedicated covid hospital in western India with drainage area of approximately 6,00,00,000 population.

Result: Mortality is higher in patients with cerebrovascular manifestation with hypercoagulability and thrombotic complications.

Conclusion: Neurological examination must be given proper importance in apparently well covid-19 positive patients to reveal minute neurological clues. A centralized database needed to be established at national level. Once covid-19 can be established as direct causative agent, a term "covid stroke" must be given proper importance and guideline can be formed for treatment.

Keywords: Stroke; covid-19; corona virus; cerebrovascular disease; covid stroke.

Key Message: There are various manifestation encounteredin patients of covid infection due to its virulence and partially understandable pathogenesis. Hence, neurological examination is playing important role in predicting prognosis of Covid-19 patients. Prompt and proper treatment is the key.

Author's Affiliation: [1]Professor, [2]Resident, [3]Associate Professor, Department of Neurosurgery, NHL Municipal Medical College, SVP Hospital Campus, Elisbridge, Ahmedabad 380006, Gujarat, India.

Corresponding Author: Himanshu Raval, Resident, Department of Neurosurgery, NHL Municipal Medical College, SVP Hospital Campus, Elisbridge, Ahmedabad 380006, Gujarat, India.

E-mail: hims02929@gmail.com

Received on: 30.12.2021

Accepted on: 12.03.2022

© Red Flower Publication Pvt. Ltd.

INTRODUCTION

Till August, 2020 approx. total 22, 80,000 confirmed cases of COVID-19 and 795,000 deaths reported to WHO.[1] Corona virus belongs to reoviridae family and an enveloped RNA virus with club shaped peplomeres on its surface and having properties of both acid-stable and acid-stable.[2] A stroke is described as a condition in which manifestation due to paucity of blood supply to parts of brain.[3] Stroke requires urgent medical intervention. Damage is less if treatment for stroke initiated

on prompt basis. A virus can be etiological factor with different pathogenesis but arteriosclerotic disease and hypertension, in absence or presence of diabetes, are remains the most common causes of stroke. The three viruses studied deeply in relation to stroke, they are cytomegalovirus (CMV), varicella zoster virus (VZV) and human immunodeficiency virus (HIV), and they can be countered by anti-viral medication.[4] Stroke emerge as one of covid-19 manifestation, it is important to know etiopathogenesis of this process as it is very helpful in directing the treatment.

CASE SERIES

We have described three case report as a case series below:

1st. A 67 years old male patient was admitted in SVP hospital on 17/05/2020 with complaints of headache, fever and difficulty in breathing since two days. Patient was diabetic since 15 years. All routine investigation were done. His covid-19 swab report came positive. After initial treatment of two days, headache was increasing in intensity and he had developed weakness over left half of body. No other neurological abnormalities were found. Ct scan was done and it was suggestive of ischemic stroke in rightfrontal region. X-ray chest was suggestive of bilateral ground glass opacities. Treatment targeting respiratory symptom complex and LMWH (Low molecular weight heparin) as well as ecosprin were given to counteract stroke. Patient's swab came negative after one month and subtle weakness were there. Patient was discharged with proper medication and physiotherapy instruction.

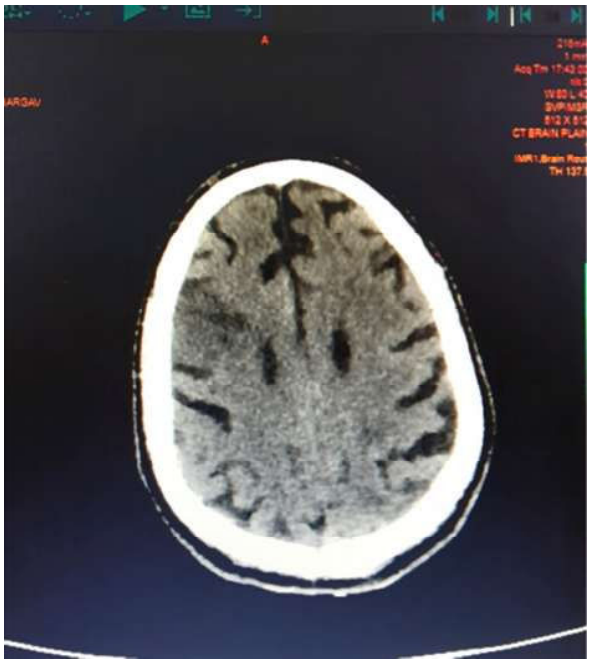

Fig. 1: CT brain (Axial cut) showing hypodensity in right frontal region.

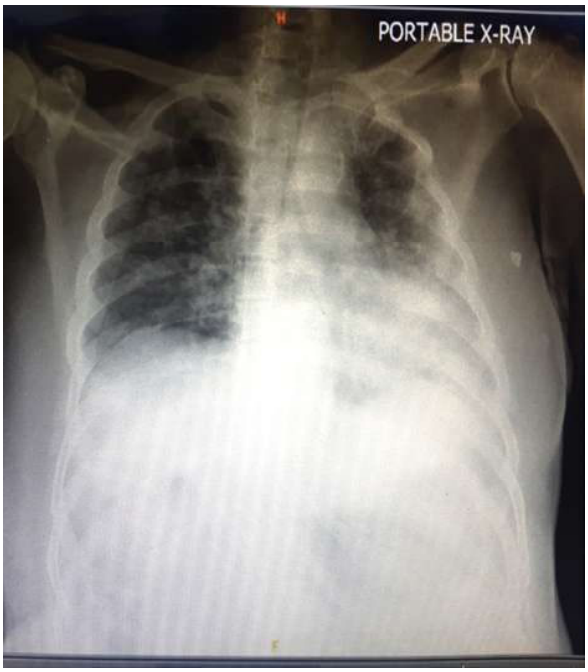

Fig. 2: Chest X ray showing sever bilateral lung involvement.

2nd. A 55 years old male patient with diabetes mellitus admitted in SVP hospital on 18/5/2020 with irritable behavior, difficulty in speech, fever and sore throat. Neurological examination was normal except irritable behavior and dysarthria. All routine investigation and MRI brain were done and there was hemorrhagic infarct involving left frontal region. Covid-19 swab was done due to presentation of fever and sore throat and it was come out to be positive. Ct thorax was done and showing bilateral pleural effusion and ground glass opacities. Subsequently patient clinically deteriorated and intubated. He was treated with antibiotics, LMWH and supportive measures. Finally, he was expired after a month.



Fig. 3: MRI Brain (Axial cut) showing Left Frontal region involvement.

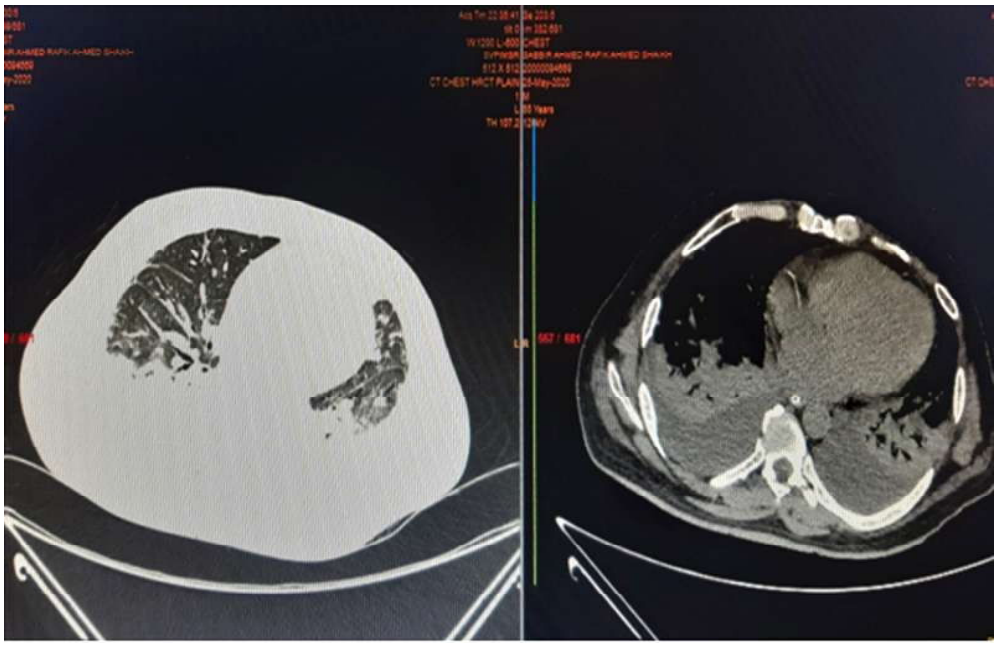

Fig. 4: HRCT showing Bilateral basal lung involvement

3rd. A 54 years old male patient with diabetes mellitus and hypertension admitted in SVP hospital on 30/5/2020 with complaints of left sided weakness, left sided astereognosis and fever. Rest neurological examination was normal. All routine investigations were done. X-ray chest was showing air bronchogram in left basal region. Patient's covid-19 swab test came positive. Ct brain was showing infarct in right parietal region suggestive of ischemic stroke. Days after patient's respiratory status declined and he was intubated. Neurology was also declined and patient became unconscious subsequently. He was managed with LMWH, antibiotics and other supportive treatment. But, after 15 days he was expired due to poor general condition.

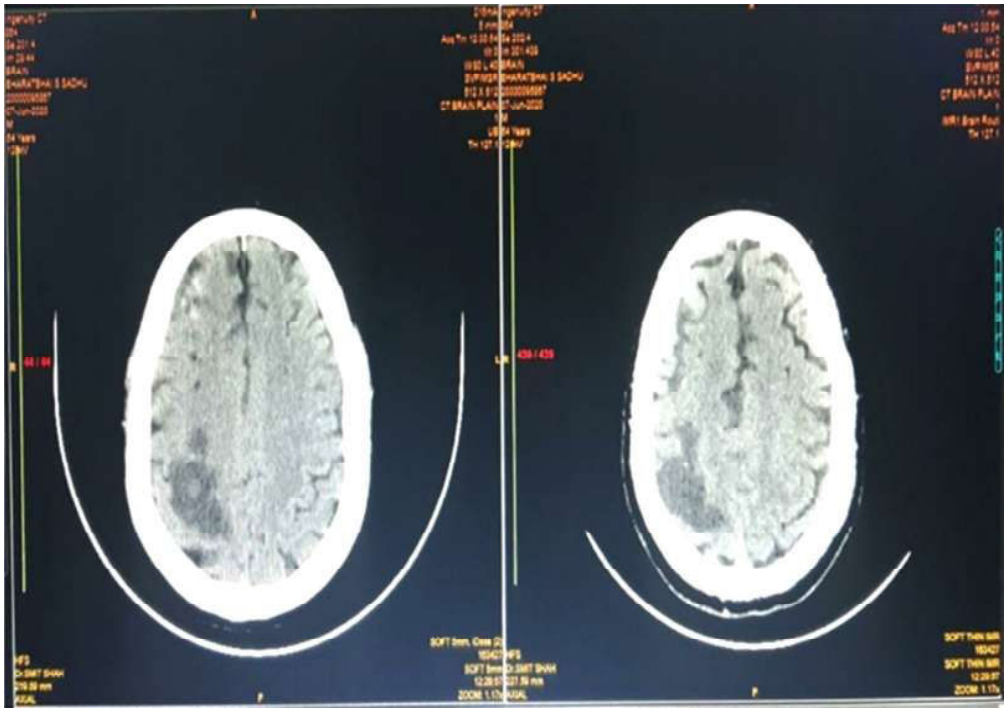

Fig. 5: CT brain (Axial cut) showing hypodensity in right parietal region.

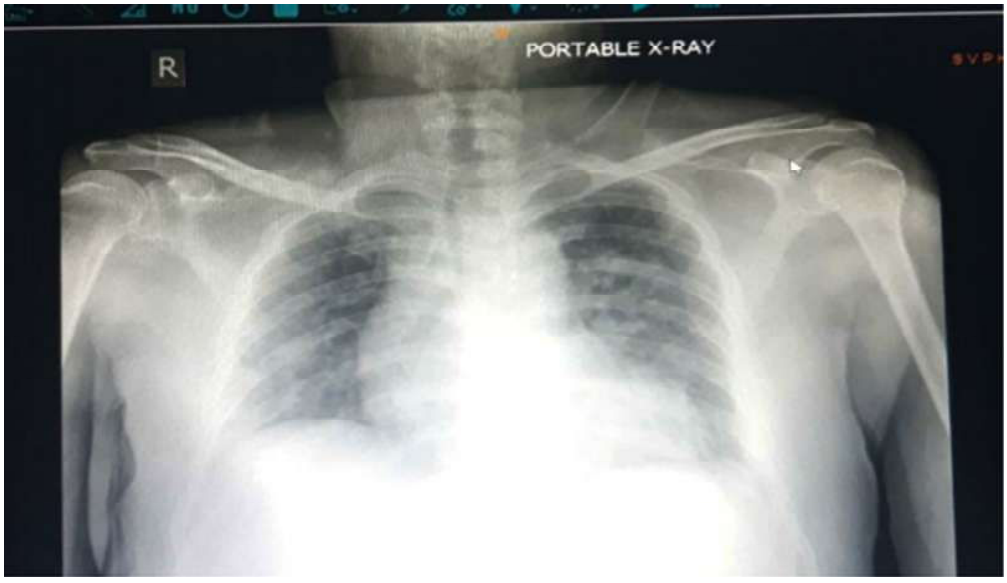

Fig. 6: Chest X-ray showing involvement of bilateral lung.

DISCUSSION AND RESULTS

CVD (Cerebrovascular diseases) is spectrum of disorders of various manifestations which includes: ischemic stroke and hemorrhagic stroke. Stroke is second most common non communicable disease causing deaths after heart disease. Stroke is defined by following: It is a sudden development of a neurologic symptom which is due to a focal vascular cause.[5] Coronavirus disease (COVID-19) is an infectious disease that involves different system in human body. Many cases having infected with the COVID-19 virus are only showing mild to moderate respiratory symptoms and recover without warranting specific interventions. Severe symptom complex can be seen in Covid 19 patients who are elder and having any other comorbidities.[6] Though COVID-19 is primarily producing

respiratory-tract symptom, literature showing that it can cause a hypercoagulable state and thrombotic complications.[7] As per one cohort study in China shows 214 COVID-19 infected cases, 36.4% of the cases hadmanifestation suggesting nervous system involvement.[8] New-onset cerebrovascular disorder is more likely to present in COVID-19 cases who already had risk factor for stroke such as extreme of age, high blood pressure, altered lipid profile and diabetes. Cases with higher stage of pneumonia (as defined by American Thoracic Society guidelines for community acquired pneumonia) due to COVID-19 infection were also prone to development of recent emerging CVD.[9] We found some research work related to covid stroke and put it in to comparison as follow.

Another study shows that there is 2.5 fold rise in severity of covid-19 infection when patient having past history of CVD.[14] As we can see there is no clear cut etiology is found in above mentioned studies, the possible mechanism via which corona virus causes CVD is described by the grau group. The Grau group hypothesized that decrement in the anticoagulant protein Cresults in activation of pro-coagulant and increment in interleukin-1 results in activation of inflammatory pathways during infection. SARS-CoV-2 can trigger synthesis of anti-phospholipid antibodies; hence, detection of antibodies as well as prompt treatment with anticoagulant agent lead to decrease probability of occurrence of ischemic stroke in case of Covid-19 infection.[12] Management of neurologic symptoms in COVID-19 must be according to its pathogenesis. However, if COVID-19 infection has taken into consideration, quick administration of antiviral and/or anti-inflammatory agents results in good outcome of cases. though there is no guideline for management of COVID-19 yet, initial data and some practioners suggest that inclusion of remdesivir in drug chart of case results in good outcome in even severely ill patients.[15] Hence, meticulous research work is the need of hour to establish the efficacyof these drugs in the management of COVID-19.

This study has been carried out at SVP hospital which is dedicated covid care center situated in Ahmedabad, Gujarat. Almost around 1500 covid-19 positive patients have been admitted from March, 2020 to July, 2020. In this duration around 20 patients have been found to have neurological symptom, out of which only three patient had stroke. This is much lesser prevalence in comparison to other studies, might be attributed to major focus on respiratory symptoms and ignorance of patients toward their symptom complex. Patients tend to consider paresis as well as headache in generalized weakness. Other's having neurological disorder other than stroke. Two were having ischemic stroke and one was having hemorrhagic stroke. All patients with covid stroke were more than 50 years of age male patients. Inflammatory markers in all three patients had been raised which include pro calcitonin, ferritin and C-reactive protein. All three were covid-19 swab positive. They were treated with injectable antibiotics like meropenem and piperacillin. Two of them were intubated and gradually deteriorated as x ray chest showed gradual worsening. All three patients were suffering from diabetes and two of them having hypertension. There is no direct cause-effect relationship established as hypertension and diabetes both consider as high risk factor in stroke. All three patients showing hypercoaguable state in their blood reports. In other studies no etiology has been established, this study stating hypercoagulability is as culprit, which needed to be addressed aggressively. Two of three patients had been expired and both were having diabetes and hypertension. Hence, mortality in this study is 66% which can be considered higher and correlate with other studies.

CONCLUSION

There is no cause effect relationship can be proven between covid-19 and stroke, neither can we deny this. Hence, treatment is directed towards the symptom complex till confirm treatment guideline or vaccine of covid-19 can be found. For cause effect relationship, confounding factors must be eliminated. Neurological examination must be given proper importance in apparently well covid-19 positive patients to reveal minute neurological clues. A centralized database needed to be established to understand all possible manifestations of covid-19 as there is more than 30, 00,000 cases found in India. Once covid-19 can be established as direct causative agent, a term "covid stroke" must be given proper importance and guideline can be formed for treatment.

REFERENCES

1. "WHO Coronavirus Disease (COVID-19) Dashboard."[internet] Accessed August 22, 2020. Available from: https://covid19.who.int/.
2. Miscellaneous viruses. In: Kanugo R, editor. Ananthnarayan and panikaer's textbook of microbiology, 10th edition. Himtayanagar: Universities press private limited; 2017. P. 563-4.

3. "NHS: stroke, overview"[internet] accessed on august 22,2020. Available from: https://www.nhs.uk/conditions/stroke/

4. Nagel MA, Mahalingam R, Cohrs RJ, Gilden D. Virus vasculopathy and stroke: an under-recognized cause and treatment target. Infect Disord Drug Targets. 2010;10(2):105-111. doi:10.2174/187152610790963537

5. Wade S smith, S. Claiborne Johnston, J. Claude Hemphill. Cerebrovascular disorder. In: Kasper DL, Hauser SL, Jameson JL, Fauci AS, Longo DL, Loscalzo J, editors. Harrison's principles of internal medicine, 19th edition. New York: Mc Graw Hill Education; 2015. Chapter 446,p. 2559-86

6. "WHO: Corona virus" [internet] Accessed on august 22, 2020. Available from: https://www.who.int/health-topics/coronavirus#tab=tab_1

7. Zhang Y, Xiao M, Zhang S, Xia P, Cao W, Jiang W,et al. Coagulopathy and antiphospholipid antibodies in patients with COVID-19. N Engl J Med. 2020; e38:382. doi:10.1056/NEJMc2007575

8. Mao L, Jin H, Wang M, Hu Y, Chen S, He Q, Chang J, Hong C, Zhou Y, Wang D, Miao X, Li Y, Hu B. Neurologic Manifestations of Hospitalized Patients With Coronavirus Disease 2019 in Wuhan, China. JAMA Neurol. 2020 Jun 1; 77(6):683-690. Doi: 10.1001/jamaneurol.2020.1127. PMID: 32275288; PMCID: PMC7149362.

9. Li Y, Li M, Wang M, et al. Acute cerebrovascular disease following COVID-19: a single center, retrospective, observational study. Stroke Vasc Neurol. 2020; 5(3):279-84. doi:10.1136/svn-2020-000431

10. Klok FA, Kruip MJHA, van der Meer NJM, et al. Incidence of thrombotic complications in critically ill ICU patients with COVID-19. Thromb Res. 2020; 191:145-147. doi:10.1016/j.thromres.2020.04.013

11. Avula A, Nalleballe K, Narula N, Sapozhnikov S, Dandu V, Toom S, Glaser A, Elsayegh D. COVID-19 presenting as stroke. Brain Behav Immun. 2020 Jul; 87:115-119. Doi: 10.1016/j.bbi.2020.04.077. Epub 2020 Apr 28. PMID: 32360439; PMCID: PMC7187846.

12. Beyrouti R, Adams ME, Benjamin L, Cohen H, Farmer SF, Goh YY, Humphries F, Jäger HR, Losseff NA, Perry RJ, Shah S, Simister RJ, Turner D, Chandratheva A, Werring DJ. Characteristics of ischaemic stroke associated with COVID-19. J Neurol Neurosurg Psychiatry. 2020 Aug;91(8):889-891. doi: 10.1136/jnnp-2020-323586. Epub 2020 Apr 30. PMID: 32354768; PMCID: PMC7231545.

13. Helms J, Kremer S, Merdji H, Clere-Jehl R, Schenck M, Kummerlen C, et al. Neurologic Features in Severe SARS-CoV-2 Infection. N Engl J Med. 2020 Jun 4;382(23):2268–70.

14. Aggarwal G, Lippi G, Michael Henry B. Cerebrovascular disease is associated with an increased disease severity in patients with Coronavirus Disease 2019 (COVID-19): A pooled analysis of published literature. Int J Stroke. 2020 Jun;15(4):385-389. doi: 10.1177/1747493020921664. Epub 2020 Apr 20. PMID: 32310015.

15. J. Grein, N. Ohmagari, D. Shin, G. Diaz, E. Asperges, A. Castagna, et al.Compassionate use of remdesivir for patients with severe COVID-19 N. Engl. J. Med.2020; 24: 382