**DOI:** 10.21088/ijcd.2395.6631.11125.4

Indian Journal of Communicable Diseases
Volume 11 Number 1, January-June 2025

# Melioidosis: A Neglected Entity or an Upcoming Menace

**Seema P Mahant[1], Sagar khadanga[2], Rashmi Verma[3], Akash Pawar[4]**

**How to cite this article:**

***Seema P Mahant1, Sagar khadanga et. al,*** Melioidosis: A Neglected entity or an Upcoming Menace. Indian J Comm Dis. 2025;11(1): 23-29.

## ABSTRACT

Melioidosis is a serious life threatening infectious disease that is potentially acquired by ingestion, inhalation or inoculation of gram-negative bacillus *Burkholderia pseudomallei*, found in soil and water in tropical and subtropical regions globally. It have capability to attack on hosts immune system, leading to the development of acute, subacute, or chronic invasive infections and clinical spectrum ranges from subclinical to fulminant septicemia with disseminated abscesses especially in immunocompromised patients like uncontrolled diabetic, CKD, chronic alcoholism. The disease is grossly under reported in our country, most probably due to lack of awareness as well as multiple symptoms imitate with other condition, without any specific identifying features. So even if diagnose at times, it is already too late or even after death. Therefore the importance of awareness and knowledge of this disease is of great importance. In centra India aiims Bhopal is recognized centre for diagnosis, and management of melioidosis, we diagnosed more than 100 cases in last 3 years. It presents with various clinical presentations like pneumonia, pyrexia of unknown origin, prostatic melioidosis, cutaneous melioidosis, neurologic melioidosis, septic arthritis and osteomyelitis. It is a great mimicker of tuberculosis of any organ. The blood or abscess fluid culture continues is keystone of diagnosis. Prolong Intravenous therapy for 4 weeks (from

**Author's Affiliation:**

[1] Professor, Department of General Medicine, AII India Institute of Medical Science, Saket Nagar, Bhopal 462020, India.

[2] Additional Professor, Department of General Medicine, AII India Institute of Medical Science, Saket Nagar, Bhopal 462020, India.

[3] Assistant Professor, Department of General Medicine, AII India Institute of Medical Science, Saket Nagar, Bhopal 462020, India.

[4] Assistant Professor, Department of General Medicine, AII India Institute of Medical Science, Saket Nagar, Bhopal 462020, India.

**Corresponding Author:**

**Seema P Mahant,** Professor, Department of General Medicine, AII India Institute of Medical Science, Saket Nagar, Bhopal 462020, India.
**E-mail:** seema.genmed@aiimsbhopal.edu.in

**Received:** 10-01-2025 **Accepted:** 15-06-2025

*Creative commons non-commercial CC BY-NC: This article is distributed under the terms of the creative commons attribution non-commercial 4.0 License (http://www.creativecommons.org/licenses/by-nc/4.0/) which permits non-commercial use, reproduction and distribution of the work without further permission provided the original work is attributed as specified on the Red Flower Publication and Open Access pages (https://rfppl.co.in)*

2 to 8 weeks) or until culture conversion followed by extended oral eradication therapy is essential to prevent relapse. The overall mortality is very high due to delays in diagnosis and appropriate treatment, predominantly in resource-poor areas. Here, we are reporting eight cases of melioidosis from Madhya Predesh, all were treated successfully with intravenous meropenem followed by oral doxycycline and cotrimoxazole.

**KEYWORDS**

• Melioidosis • *Burkholderia Pseudomallei* • Bioterrorism • Lack of Awareness.

## INTRODUCTION

Melioidosis, many of us are not aware about this life threatening infectious disease also known as whitmore disease.It is very lethal infectious disease with mortality upto 40%, that can infect both human and animals. It is first discovered in Burma(now Myanmar) by Whittemore and Krishnaswami in 1911 and caused by gram negative bacilli Burkholderia pseudomallei usually found in soil and water and Transmitted by Inhalation, Inoculation & Ingestion. People with long standing uncontrolled Diabetes Mellitus, Chronic Alcoholic, COPD, CKD, immunocompromised & Cancers patients, working bare footed or bare handed in contact with soil and water specially in rainy season are at high risk. It may manifest as-Acute: 85% of cases (common) less than 2 months of symptoms and present as pneumonia, sepsis, and multi-organ abscesses, Chronic: 15% cases due to dormant bacilli. Organism is lethal with high mortality, very infective, easily transmissible, survival in soil and water for many years make them use as bioterrirism vepan.

## CASE PRESENTATION

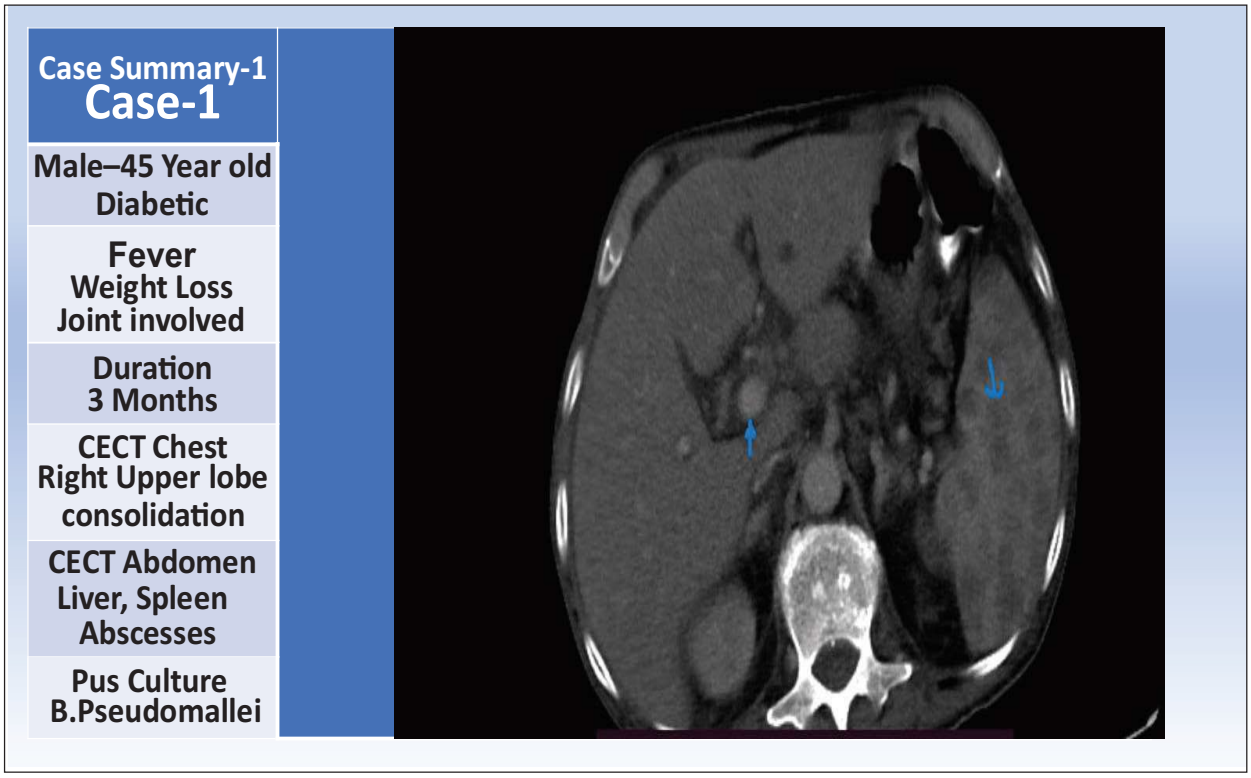

**Case Summary-2**

Male 48 Year old
Diabetic

Fever
Cough
Weight loss
Joint involved

Duration
2 Months

CECT Chest–
Bilateral Lung patchy consolidations and abscesses

CECT Abdomen
Hepato-Splenomegaly

Blood Culture
B.Pseudomallei

**Case Summary-3**

Male-42 Year old
Diabetic

Fever
Joint involved
Cough
Breathlessness

Duration
15 days

Chest X-ray
Bilateral lung patchy consolidations

Left knee
septic arthritis

Blood/Pus Culture
B.Pseudomallei

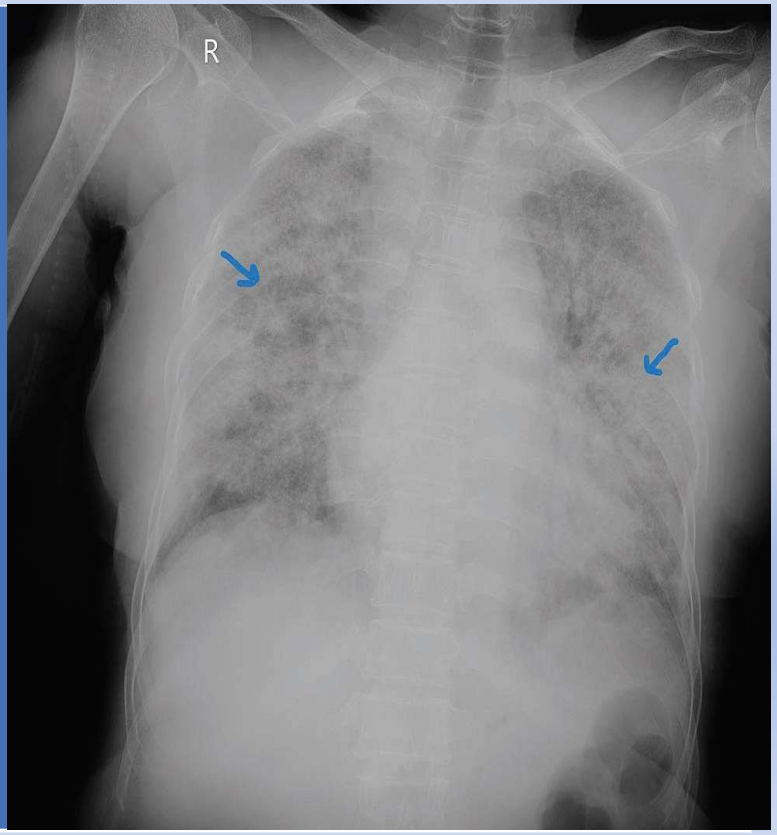

## Case Summary-4

Male-45 Year old
Diabetic

Fever
Pain Abdomen/Cough
Joint involved

Duration
2 Months

CECT Abdomen
Liver Abscesses

CECT Chest
Left Lower Zone
Consolidation

Pus Culture
B.Pseudomallei

## Case Summary-5

Male–32 Year old
Diabetic

Fever
Pain Abdomen/Cough
Weight loss
Joint involved

Duration
15 days

CECT Chest
Cavitary consolidation in right middle lobe

CECT Abdomen
small liver/spleen abscesses & infarcts, pancreatic abscess

Pus Culture
B.Pseudomallei

## Case Summary-6

Left humerus osteomyelitis with Septic shock and MODS

C/ F: fever, altered Sensorium Weight loss Joint involved

Duration 30 days

MRI images taken at interval of 6 months

Blood Culture B.Pseudomallei

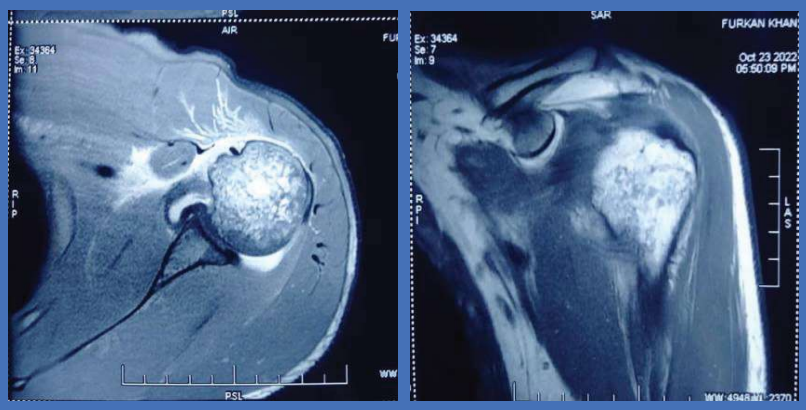


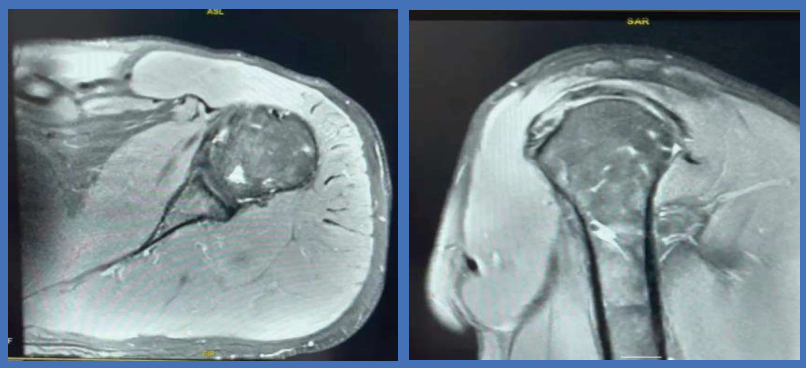

## Case Summary-7

Arthritis of the left elbow

C/F: fever, swelling of left elbow, restriction of activity

Duration 30 days

Pre & Post treatment Image

synovial fluid B.Pseudomallei

Pre-treatment

Post-treatment

| Case Summary-8 | Pre-treatment |
|---|---|
| Multiple skin abscesses with visceral Dissemination | |
| C/E:multiple skin abscess with 2 months fever | |
| Duration 30 days | Post-treatment |
| | |
| Pre & Post treatment Image | |
| Blood Culture B.Pseudomallei | |

## DISCUSSION

It is well-established that melioidosis poses serious threat to endemic region like India.[1] In fact, multiple cases of melioidosis have already been recognized, the primary victim being the local farmers and laborers.[2,3] There are many states in our country have high incidence and prevalence rate including Madhya Pradesh. The disease is grossly under reported in our country, most probably due to lack of awareness as well as multiple symptoms imitate with other condition, without any specific identifying features, so even if diagnose at times, it is already too late or even after death, therefore the importance of awareness and knowledge of this disease is of great importance. Risk factors like diabetes mellitus, renal diseases, thalassemia, pulmonary tuberculosis, chronic lung or liver diseases, alcohol abuse and malignancy can contribute to the development of melioidosis; diabetes mellitus being the most common associated factor.[1,4]

Its presentation may vary from unapparent infection, acute localized suppurative infection and acute septicemia to chronic suppurative infection. Pulmonary infection is the most common form of presentation that is likely involved primarily through inhalation or secondarily via hematogenous route.[4,5] However, virtually any organ like lung, skin, subcutaneous tissue, bones and joints, liver, spleen, bladder, genital organs, brain, pericardium etc. may be involved. Most interestingly, the incubation period can dramatically vary between 2 days to 26 years.[5] Notably, out of eight, six were diabetic and 4 were alcoholic. All were treated successfully with intravenous meropenem followed by oral doxycycline and cotrimoxazole. Its treatment is usually divided into two phases: the first or acute phase in which intravenous ceftazidime or carbapenems with or without trimethoprim-sulfamethoxazole is given for minimum of 14 days (2-6 weeks) and the second or eradication phase in which oral drugs like trimethoprim-sulfamethoxazole with or without doxycycline is given for at least 12 weeks. However, depending upon the clinical responses and the severity of infection, the acute and the eradication phase can be extended for 4 weeks and 20 weeks respectively.[2,6]

## CONCLUSION

In India, most of the clinicians are unaware of the clinical presentation of melioidosis; therefore, they often misdiagnose the condition for tuberculosis. Clinicians should suspect melioidosis as a differential diagnosis when any febrile patient with multiple abscesses and predisposing factors like diabetes does not respond to antibiotics easily, especially if the patient has multi-organ involvement. Consecutively, occupational history is equally important as one cannot rule out the possibility of local attainment. Finally, microbiologists and laboratory technicians should be sufficiently trained so that they do not confound the organism for other *Burkholderia* species. The disease has a high mortality rate; therefore, it should be diagnosed at its earliest possible stages.

**Take home message**

- If unexplained prolonged fever
- Diabetes Mellitus
- Other immunocompromised condition
- Farmer
- Multi-system involvement
- Multiple site abscesses.
- Should Think Melioidosis

## REFERENCES


1. Dance D. Melioidosis: the tip of the iceberg? Clin Microbiol Rev. 1991;4(1):52–60.
2. Goel A, Bansal R, Sharma S, Singhal S, Kumar A. Chronic melioidosis presenting with multiple abscesses. Oxf. Med. Case Reports. 2016;2016(6):113–6.
3. Pandey V, Rao SP, Rao S, Acharya KKV, Chhabra SS. Burkholderia pseudomallei musculoskeletal infections (melioidosis) in India. Indian Journal of Orthopaedics. 2010;44(2):216–20.
4. Suputtamongkol Y, Chaowagul W, Chetchotisakd P, Lertpatanasuwun N, Intaranongpai S, Ruchutrakool T, *et al.* Risk factors for melioidosis and bacteremic melioidosis. Clin Infect Dis. 1999;29(2):408–13.
5. Vidyalakshmi K, Chakrapani M, Shrikala B, Damodar S, Lipika S, Vishal S. Tuberculosis mimicked by melioidosis. Int J Tuberc Lung Dis. 2008;12(10):1209–15.
6. Currie BJ. Melioidosis: an important cause of pneumonia in residents of and travellers returned from endemic regions. Eur Respir J. 2003;22(3):542–50.