DOI: 10.21088/ijcd.2395.6631.11125.3

Indian Journal of Communicable Diseases
Volume 11 Number 1, January-June 2025

CASE REPORT

Role of Autologous platelet rich Plasma in Pressure Sore: A Case Study

C. Lalnunmawia[1], Ravi Kumar Chittoria[2], Kanav Gupta[3], Shanmuga Priya R[4]

HOW TO CITE THIS ARTICLE:

C. Lalnunmawia, Ravi Kumar Chittoria et. al, Role of Autologous platelet rich Plasma in Pressure Sore : A Case Study. Indian J Comm Dis. 2025;11(1): 19-22.

ABSTRACT

Patients with chronic conditions who are bedridden or immobile for extended periods of time frequently have pressure sores. Deep tissue infections caused by them may spread to include deeper structures like bones and cause severe morbidity. APRP has aided as an adjuvant therapy to optimise results in a variety of plastic surgical applications. In our case report, we go through how Autologous Platelet Rich Plasma (APRP) can be used in conjunction with other treatments to treat pressure sores.

KEYWORDS

• Autologous Platelet • APRP • Conjunction

AUTHOR'S AFFILIATION:

[1] Junior Resident, Department of Plastic Surgery, Jawaharlal Institute of Post-graduate Medical Education and Research, Puducherry, India.

[2] Professor & Registrar (Academic), Head of IT Wing and Telemedicine, Department of Plastic Surgery & Telemedicine, Jawaharlal Institute of Post-graduate Medical Education and Research, Puducherry, India.

[3] Senior Resident, Department of Plastic Surgery, Jawaharlal Institute of Post-graduate Medical Education and Research, Puducherry, India.

[4] Senior Resident, Department of Plastic Surgery, Jawaharlal Institute of Post-graduate Medical Education and Research, Puducherry, India.

CORRESPONDING AUTHOR:

Ravi Kumar Chittoria, Professor & Registrar (Academic), Head of IT Wing and Telemedicine, Department of Plastic Surgery & Telemedicine, Jawaharlal Institute of Post-graduate Medical Education and Research, Puducherry, India.

E-mail: drchittoria@yahoo.com

Received: 26-04-2025 **Accepted:** 30-05-2025

Creative commons non-commercial CC BY-NC: This article is distributed under the terms of the creative commons attribution non-commercial 4.0 License (http://www.creativecommons.org/licenses/by-nc/4.0/) which permits non-commercial use, reproduction and distribution of the work without further permission provided the original work is attributed as specified on the Red Flower Publication and Open Access pages (https://rfppl.co.in)

INTRODUCTION

Pressure sore caused by the compression between the bony prominence and the external surface. Pressure sores are brought on by the localised breakdown of tissues. Hospital pressure sore incidence ranges from 2 to 28%. By increasing hospital stays, costs, morbidity, and mortality, pressure sores significantly raise the burden on the healthcare system.[1] Over the bone prominences of the sacrum, heel, ischium, trochanteric region, occiput, and scapula, pressure sores frequently develop. Pressure sores usually develop on the sacrum in acute situations, whereas they mostly affect the ischial and trochanteric regions in chronic situations. Pressure, friction, shear, dampness, neurological damage, and starvation are some of the causes of pressure sores. The NPUAP (National Pressure Ulcer Advisory Panel) staging method is the most widely used categorization. Plastic surgery patients can successfully use autologous platelet-rich fibrin plasma, a successful restorative alternative. APRP (Autologous Platelet Rich Plasma) was employed in our study as an adjuvant in the treatment of grade 2 pressure sores.

MATERIALS AND METHODS

After receiving approval from the departmental Ethical Committee, this study was carried out in the Plastic Surgery Department of a tertiary care facility. The patient provided written informed consent. This prospective observational study was conducted on a male subject, age 30, who had no known co-morbidities, with an alleged history of accidental fall from tree 12 years back and developed acute flaccid paralysis and underwent MIAMI fixation and laminectomy. Post surgery, he had persistent sensory loss and weakness of both lower limbs with incontinence of stools and urine. He developed ulcers in the sacral and ischial regions. (Figure 1).

He was clinically determined to have Grade 3 pressure ulcers, according to the National Pressure Ulcer Advisory Panel. Systematic examination of the patient and the ulcer was conducted; comorbidities that were present were found and treated in accordance with the SWCR standards. The use of autologous platelet rich plasma (Figure 2) as a regenerative modality for wound care is one of many regenerative wound care modalities available. In our case, APRP was employed in conjunction with therapy. 4.5 ml of whole blood was drawn from a peripheral vein after obtaining informed consent, and 0.5 ml of 3.2% sodium citrate was added to make 5 ml (blood: anticoagulant at 9:1). The centrifugation machine received the centrifugation tube. For 10 minutes, the fluid was centrifuged at 3000rpm. The initial centrifugation revealed three parts. Platelets and plasma are found in the upper portion, white blood cells (WBCs) and red blood cells are found in the middle and lower portions, respectively (RBCs). Lower and middle pieces are thrown away. The upper portion was transferred to a new tube and centrifuged again for 10 minutes at 4000rpm. Then, two pieces were displayed. Platelet-poor plasma makes up the upper two thirds, while platelet-rich plasma and erythrocytes with platelet clumps make up the lower third. The lower third of the area was treated with APRP. Multiple sites of the APRP were injected into the raw area at the borders of the wound (Figure 3), and then collagen dressing was applied over the wound (Figure 4). The ulcer was reviewed after 14 days and three sittings, spaced five days apart, were completed.

RESULTS

The Pressure sore start healing and was showing granulation tissue after two weeks (Figure 5). There was no indication that the ulcer was getting worse or that it had an infection. The ulcer site was healing and there was no discharge.

Figure 1: Wound at presentation



Figure 2: APRP preparation

Figure 3: APRP application

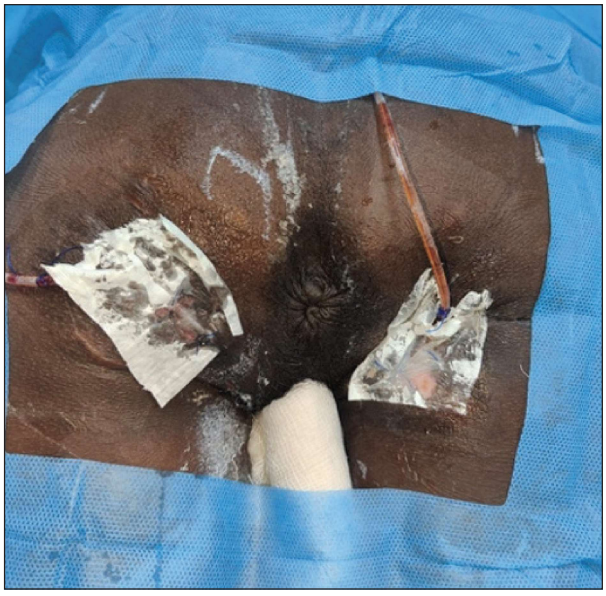

Figure 4: Collagen sheet applied

DISCUSSION

One of the frequent issues with patients who are neurologically impaired, chronically bedridden, or receiving ICU care is bedsores. Management is always difficult since it is frequently related to other issues. Over the bone prominences of the sacrum, heel, ischium, trochanteric region, occiput, and scapula, pressure sores frequently develop.[2] Pressure sores usually develop on the sacrum in acute situations, whereas they mostly affect the ischial and trochanteric regions in chronic situations. Pressure, friction, shear, dampness, neurological damage, and starvation are some of the causes of pressure sores.[3] The NPUAP (National Pressure Ulcer Advisory Panel) staging method is the most widely used categorization.[2,3]

1. Stage: Consists of intact skin with localised, non-blanchable redness, typically over a bony prominence.

2. Stage: Is characterised by partial dermis thickness loss that manifests as a shallow open ulcer with a red or pink wound bed but no slough. Also, possible to see an intact or open/ruptured blister filled with serum. Full thickness tissue loss characterises stage 3 pressure ulcers. Bone, tendon, or muscle are not revealed, although subcutaneous fat may be apparent. Slough might be visible, but it doesn't hide how much tissue has been lost. Includes digging tunnels and undermining. Full thickness tissue loss and exposed bone, tendon, or muscle characterise stage four. Some areas of the wound bed may have eschar or slough. include tunnelling and undermining

frequently.[4] The standard of care for treating pressure sores has been determined by numerous research, yet prevention may not always be possible. Pressure alleviation, wound debridement, wound encouragement of healing, and excision and closure of flaws when appropriate are among the goals of managing pressure sores.[5] Platelets produce growth factors, which are present in platelet rich plasma(PRP), platelet rich fibrin (PRF), and platelet rich plasma(PRP). In this context, the use of therapies made from platelet-rich plasma is beneficial.[6,7] The bioactive proteins that platelets produce during their action draw macrophages, mesenchymal stem cells, and osteoblasts to the affected area. The clearance of necrotic tissue and enhancement of tissue regeneration and repair are both known to be promoted by these cells. Additionally, it speeds up the healing of wounds. A section of plasma with a higher platelet content is known as platelet-rich plasma (PRP). It is made up of platelets that have growth and clotting factors. A thrombin activator or anticoagulant are not necessary for the APRP preparation procedure, which is also less complicated and handling-intensive.[8] A hospital easily has the required supplies on hand. The activation of autologous growth factors and the biomechanical rigidity of plasmatic proteins after fibrin formation offer a unique architecture that contributes in the healing process. Growth factors from activated platelet alpha-granules also play a crucial role in tissue repair in addition to fibrin, fibronectin, and vitronectin.[9] They are vascular endothelial growth factor (VEGF), hepatocyte growth factor (HGF), fibroblast growth factor-b (FGFb), PDGF, epidermal growth factor (EGF), and angiopoietin-I. In the course of our research, APRP served as an adjuvant in the treatment of pressure ulcers.

CONCLUSION

This study evaluates the effectiveness of APRP in treating pressure sores. To further support the findings, a sizable multicentric, double-blinded control trial with statistical analysis is needed.

Authors' Contributions

All authors made contributions to the research, is putatively expected to be useful article.

Source of Funding: None

Conflict of Interest: None

REFERENCES

1. Cuddigan J, Frantz RA. Pressure ulcer research: pressure ulcer treatment. A monograph from the National Pressure Ulcer Advisory Panel. Adv/ Wound/ Care. 1998;11(6):294–300.
2. Malone JR, Mcinnes E. Pressure ulcer risk assessment and prevention; 2001. Available from: http://www.judy-waterlow.co.uk/downloads/rcn.pdf.
3. Vangilder C, Amlung S, Harrison P. Results of the 2008-2009 International Pressure Ulcer Prevalence Survey and a 3-year, acute care, unit-specific analysis. Ostomy Wound Manage. 2009;55(11):39–45.
4. Reddy M, Gill SS, Rochon PA. Preventing pressure ulcers: a systematic review. JAMA. 2006;296(8):974–84.
5. Brandeis GH, Berlowitz DR, Katz P. Are pressure ulcers preventable? A survey of experts. Adv Skin Wound Care. 2001;14(244):245–8.
6. Anitua E, Andia I, Ardanza B, Nurden P, Nurden AT. Autologous platelets as a source of proteins for healing and tissue regeneration. Thromb Haemost. 2004;91(1):4–15.
7. Dhurat R, Sukesh M. Principles and Methods of Preparation of Platelet-Rich Plasma: A Review and Author's Perspective. J Cutan Aesthetic Surg. 2014;7(4):189–97.
8. Chittoria RK, Kumar P, Bajaj SP, Singh AK. General Clinical Guidelines for Wound Management: Redefining acronym SWCR. An open access official publication of Society for Wound Care and Research. 1993;p. 342. Available from: https: //www.researchgate.net/publication/275212789_General_Clinical_Guidelines_for_Wound_Management_Redefining_acronym_SWCR.
9. Álvarez AES, Riera-Del-Moral LF, García-Arranz M, Alvarez-García J, Concepción-Rodriguez NA, Riera-De-Cubas L. Use of platelet-rich plasma in the healing of chronic ulcers of the lower extremity. Actas Dermosifiliogr. 2014;105(6):597–604.