DOI: 10.21088/ijcer.2321.9815.13225.5

Indian Journal of Cancer Education and Research
Volume 13 Number 2, July - December 2025

CASE REPORT

Colonic Adenocarcinoma with Coexisting Amoebiasis

Archana N. Rijhsinghani

HOW TO CITE THIS ARTICLE:

Archana N Rijhsinghani. Colonic Adenocarcinoma with Coexisting Amoebiasis. Ind J Canc Educ Res 2025; 13(2): 85-87.

ABSTRACT

Amebiasis caused by Entamoeba histolytica is one of the most fatal parasitic diseases. The infection is acquired by ingestion of contaminated food and water and is endemic in developing countries with poor sanitation. It presents as asymptomatic infection or acute proctocolitis to acute fulminant colitis with high mortality rates. Both the clinical presentation and the endoscopic appearance of colonic amebiasis can mimic colon carcinoma.

Colorectal cancer is an increasingly important public health problem worldwide. Colorectal cancers have the highest incidence among malignancies after lung cancer, breast cancer in women, and prostate cancer in men. Colon cancer is often sporadic and related to risk factors such as age, race, diet, and the presence of inflammatory bowel disease. Hereditary colon malignancies are most commonly associated with Lynch syndrome and genetic polyposis syndromes.

Histological diagnosis is always essential for diagnosis of malignancy. However, it is essential to look beyond those malignant glands into surrounding tissue of tiny bits for better patient management. In this regard, amoebiasis may not only mimic carcinoma but, rarely, may coexist with carcinoma. Here, we present a rare case of coexisting adenocarcinoma and amoebiasis in the same patient diagnosed on biopsy.

KEYWORDS

• Malignancy • Amoebiasis • Adenocarcinoma

INTRODUCTION

Amebiasis caused by Entamoeba histolytica is one of the most fatal parasitic diseases. The infection is acquired by ingestion of contaminated food and water and is endemic in developing countries with poor sanitation. It presents as asymptomatic infection or acute proctocolitis to acute fulminant colitis

AUTHOR'S AFFILIATION:

Histopathology Department, Agilus Diagnostics Dr Phadke Labs, Mumbai, Maharashtra, India.

CORRESPONDING AUTHOR:

Archana N Rijhsinghani, Histopathology Department, Agilus Diagnostics Dr Phadke Labs, Mumbai, Maharashtra, India.

E-mail: archana2188@gmail.com

➤ **Received:** 24-08-2025 ➤ **Accepted:** 22-10-2025

Creative Commons Non Commercial CC BY-NC: This article is distributed under the terms of the Creative Commons Attribution NonCommercial 4.0 License (http://www.creativecommons.org/licenses/by-nc/4.0/) which permits non-Commercial use, reproduction and distribution of the work without further permission provided the original work is attributed as specified on the Red Flower Publication and Open Access pages (https://www.rfppl.co.in)

with high mortality rates. Both the clinical presentation and the endoscopic appearance of colonic amebiasis can mimic colon carcinoma.[1] Here, we present a rare case of adenocarcinoma of colon with amoebiasis.

Case presentation

A 50 year old/ female presented with weight loss, diarrhea and vague abdominal pain of 2 months duration. CT scan performed revealed transverse colon growth. Endoscopy was suggestive of hepatic flexure growth. Biopsy was performed and we received few grey white tissue bits, aggregating to 0.6 x 0.6 x 0.2 cm. Biopsy revealed moderately differentiated adenocarcinoma (*Figure 1, 2*) with tumour arranged in glandular, fused glandular and singly scattered pattern. Scant extracellular and intracellular mucin was seen. Also noted was ulcer slough (*Figure 2*) showing trophozoites of Entamoeba histolytica (*Figure 3*). Hence the final diagnosis was adenocarcinoma of colon with amoebiasis.

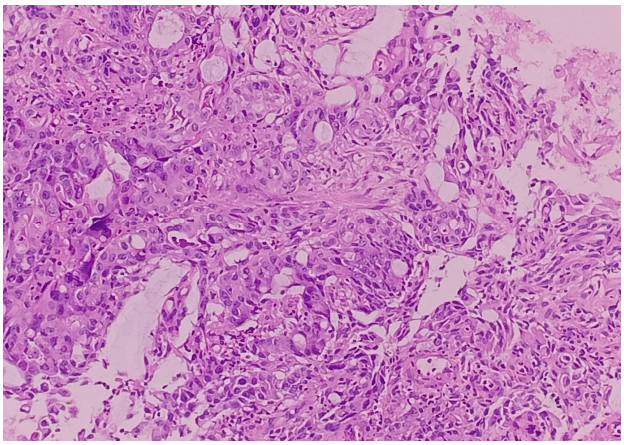

Figure 1: Moderately differentiated adenocarcinoma (HE x 100)

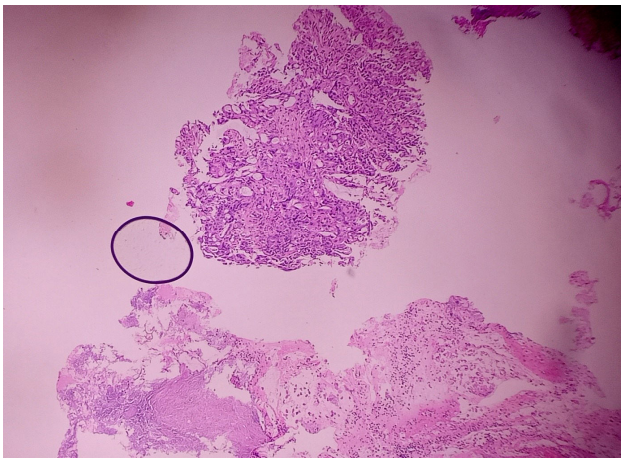

Figure 2: Green arrow: Adenocarcinoma, Blue arrow: Ulcer slough (HE x 40)

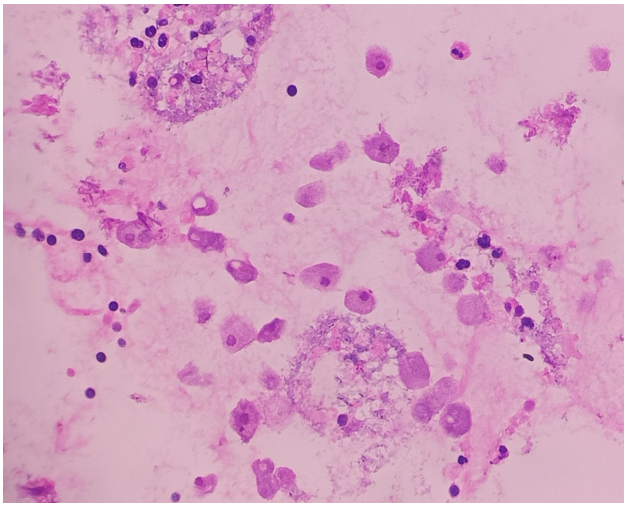

Figure 3: Trophozoites of Entamoeba histolytica (HE x 100)

DISCUSSION

Entamoeba histolytica exists either in a short-lived mobile trophozoite (10 µm to 20 µm in length) that can invade multiple organ systems or a long-surviving cyst form that can colonize intestines.[2] After ingestion of E. histolytica cyst from contaminated food or water, the organism excysts and emerges in the large intestine as an active trophozoite. Trophozoites multiply by simple division and encyst as they move further down the large bowel. Cysts are then expelled in the faeces.[3] Majority of E. histolytica infections may be asymptomatic, approximately 10% of amebic infections progress to invasive disease. Approximately 1% of cases of invasive amebic disease develop extraintestinal disease through the bloodstream, affecting tissues such as the liver, lungs, pericardium, brain and skin, which may result in severe and potentially fatal illness.[4,5]

Incidence of developing invasive or disseminated amoebiasis increases in immunosuppressed patients.[6] Risk of fulminant colitis increases in patients on chemotherapy or corticosteroid treatment.[7]

Ameboma of the colon occurs rarely due to the annular growth of granulation tissue and can present as mass lesion simulating colonic carcinoma in elderly individuals.[8]

In India, the annual incidence rates for colon cancer and rectal cancer in men are 4.4 and 4.1 per 100000, respective, and those of colon cancer in women is 3.9 per 100000. Colon cancer ranks 8th and rectal cancer ranks 9th among men.[9]

Amoebic infection co-existing with colon cancer is exceedingly rare.[10]

In view of two pathologies on histology, biopsy diagnosis should not be missed out, as amoebiasis can present with life-threatening complications in immunocompromised state (which includes colon carcinoma cases where the patients may receive chemotherapy and radiotherapy). This will help in timely management of patients and avoid life threatening complications.

CONCLUSION

Amebiasis may not only mimic carcinoma but, rarely, may coexist with carcinoma in the same patient. This case highlights importance of histological diagnosis pertaining not only to malignancy but also not to overlook small parasitic balls sitting in the ulcer slough and hence leading to accurate diagnosis and management of patients.

REFERENCES

1. Grosse A. Diagnosis of colonic amebiasis and coexisting signet-ring cell carcinoma in intestinal biopsy. *World J Gastroenterol* 2016; 22(36): 8234-8241 [PMID: 27688666 DOI: 10.3748/wjg.v22.i36.8234].
2. Adams E.B., MacLeod I.N. Invasive amebiasis. I. Amebic dysentery and its complications. Medicine (Baltimore) 1977; 56(4): 315-23.
3. Ravdin J., Petri W., Mandell G *et al*. Entamoeba histolytica (amebiasis). Principles and Practice of Infectious Diseases 1990: 20(3): 6-49.
4. Choudhuri G., Rangan M. Amebic infection in humans. Indian Journal of Gastroenterology: Official Journal of the Indian Society of Gastroenterology 2012; 3 1(4): 153-62.
5. Skappak C., Akierman S., Belga S. *et al*. Invasive amoebiasis: a review of Entamoeba infections highlighted with case reports. Canadian Journal of Gastroenterology & Hepatology 2014; 28(7): 355-9.
6. Stark D., Barratt J.L., van Hal S. *et al*. Clinical significance of enteric protozoa in the immunosuppressed human population. Clinical Microbiology Reviews 2009; 22(4): 634-50.
7. Evering T., Weiss L.M. The immunology of parasite infections in immunocompromised hosts. Parasite Immunology 2006; 28(11): 549-65.
8. Kataria H., Seth A., Attri A.K., Singh Punia R.P. Ameboma of Colon Simulating Colonic Adenocarcinoma. Int J Appl Basic Med Res. 2018 Jan-Mar; 8(1): 42-44. doi: 10.4103/ijabmr.IJABMR_285_17. PMID: 29552535; PMCID: PMC5846219.
9. Nandakumar A. National cancer registry programme. Indian Council of Medical Research, Consolidated report of the population based cancer registries, New Delhi, India. 1990; 96.
10. Gupta P., Sahay A., Ramadwar M. *et al*. Entamoeba Histolytica Infesting Colonic Malignancy: First Series of Four Cases. Rec Adv Path Lab Med 2018; 4(3): 17-21.