DOI: 10.21088/ijb.2394.1391.12125.4

Indian Journal of Biology
Volume 12 Number 1 January-June 2025

CASE REPORT

Morphological Features of Various White Blood Cells of 05 Months Castrated Non-Descriptive Cattle of Odisha

Ipsita Dash

How to cite this article:

Ipsita Dash. Morphological Features of Various White Blood Cells of 05 Months Castrated Non-Descriptive Cattle of Odisha. Ind. J Biol 2025; 12(1): 41-45.

ABSTRACT

The present study was designed to investigate different types of WBCs in a 05 months castrated Non-Descriptive (ND) cattle as there is no previous report on morphology of white blood cells of castrated ND cattle of Odisha. Various types of WBCs were observed in this study namely lymphocytes, monocytes, neutrophils, eosinophils and basophil.

KEYWORDS

• WBC • Lymphocyte • Monocyte • Neutrophil • Eosinophil • Basophil

INTRODUCTION

The aim of the present study was to investigate different types of WBCs in one 05 months castrated Non-Descriptive (ND) cattle. Recently morphology of cells has been indicated as a powerful indicator of cellular function[6]. Since there was no previous report on morphological features of WBCs of castrated 05 months Non-Descriptive (ND) cattle of Odisha, an attempt has been taken to undertake this particular study. Growing calves are castrated for easy handling as well as to reduce aggressive and sexual behaviour in some production systems during the finishing phase. Growth rate and body composition in cattle is alterted due to castration due to change in hormonal status [5]. For quantification of morphology of cell it is fundamental to the statistical study of cell populations, and can help unravel mechanisms underlying cell and tissue morphogenesis[7].

MATERIALS AND METHODS

Blood sample was collected from jugular vein of one 05 months castrated Non-Descriptive (ND) cattle and blood smear was prepared on a grease-free microscopic slide, then air dried, fixation was done by methanol and staining was done by Giemsa stain for morphological study under a microscope under 40X objective

AUTHOR'S AFFILIATION:

Assistant Director, State Forensic Science Laboratory, Bhubaneswar, Odisha 751010, India.

CORRESPONDING AUTHOR:

Ipsita Dash, Assistant Director, State Forensic Science Laboratory, Bhubaneswar, Odisha 751010, India.
E-mail: ipsita.dash9@gmail.com

➢ **Received:** 25-12-2024 ➢ **Accepted:** 29-01-2025

Creative commons non-commercial CC BY-NC: This article is distributed under the terms of the creative commons attribution non-commercial 4.0 License (http://www.creativecommons.org/licenses/by-nc/4.0/) which permits non-commercial use, reproduction and distribution of the work without further permission provided the original work is attributed as specified on the Red Flower Publication and Open Access pages (https://rfppl.co.in)

and photographs of WBCs were taken and morphology were studied.

RESULTS AND DISCUSSION

The lymphocytes observed were small (Fig a.) and large lymphocytes (Fig b. & c.) having circular and elliptical in shaped respectively. The monocytes observed were kidney shaped (Fig. e & f). Various types of neutrophils were observed in this study, i.e., banded neutrophils (Fig. g & h), trilobed neutrophils (Fig. i), S shaped neutrophil (Fig. j), multilobed neutrophil (Fig. m), pear shaped neutrophil (Fig. n), bilobed neutrophil (Fig. o), segmented neutrophil (Fig. p), multilobed neutrophil (Fig. q), tetralobed neutrophil (Fig. r), multilobed neutrophils (Fig. s, t, u, v, w, x, y, z, aa & ab), eosinophil (Fig. ac), basophil (Fig. ad). The Influence of age[1,3,4] sex[1,4] and breed[2,3] was studied by various authors on the morphometry of RBCs.

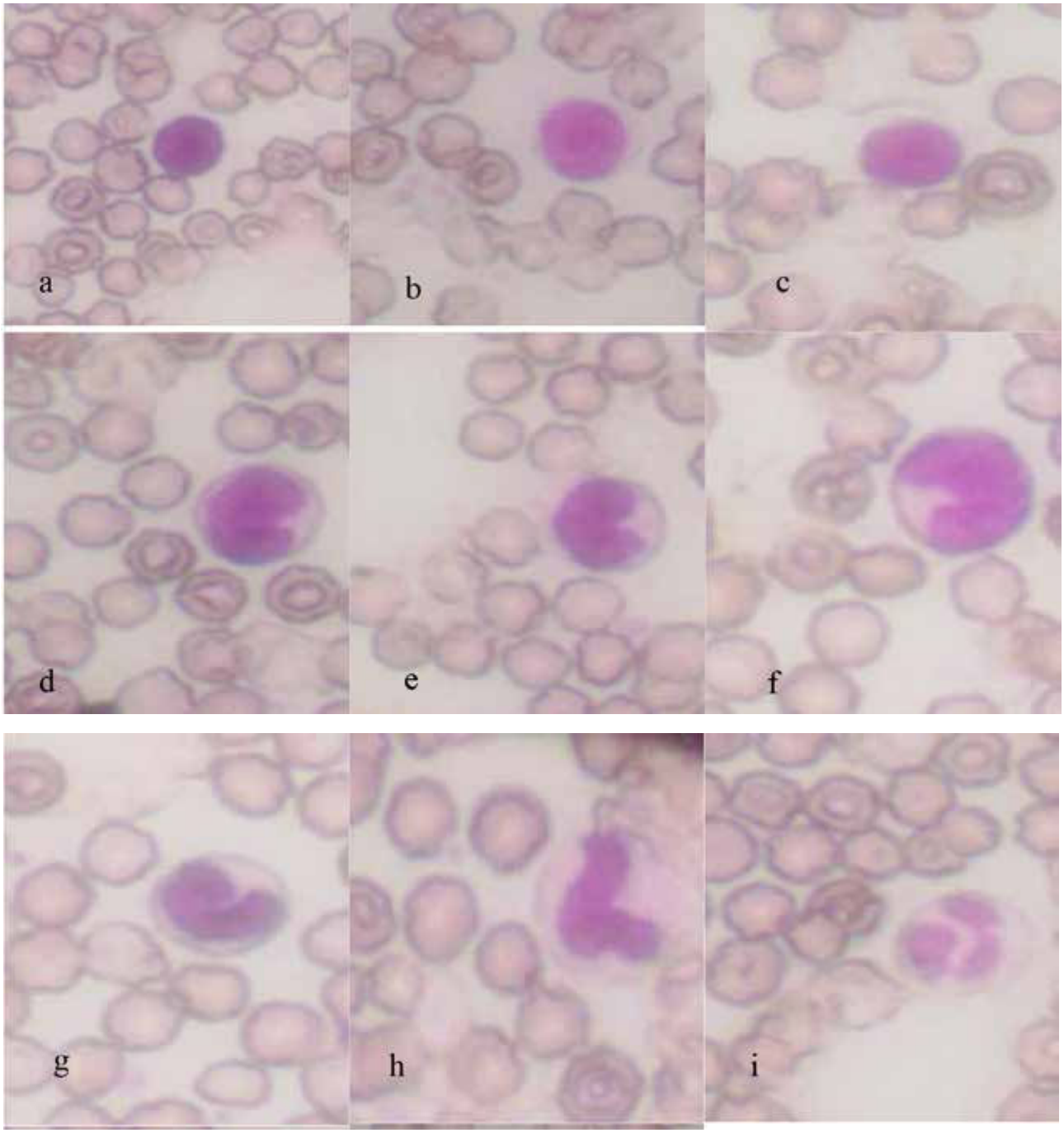

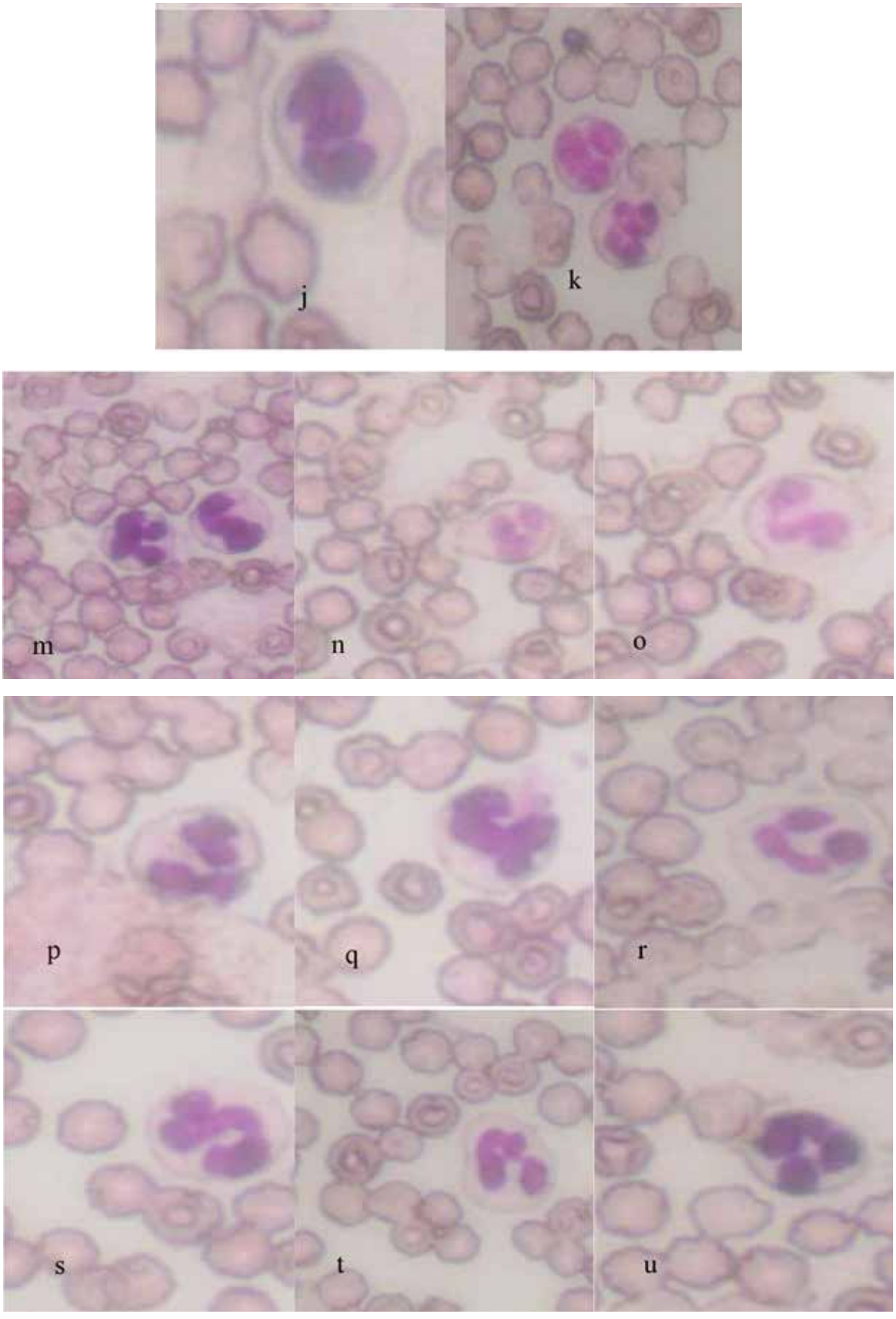
j
k
m
n
o
p
q
r
s
t
u

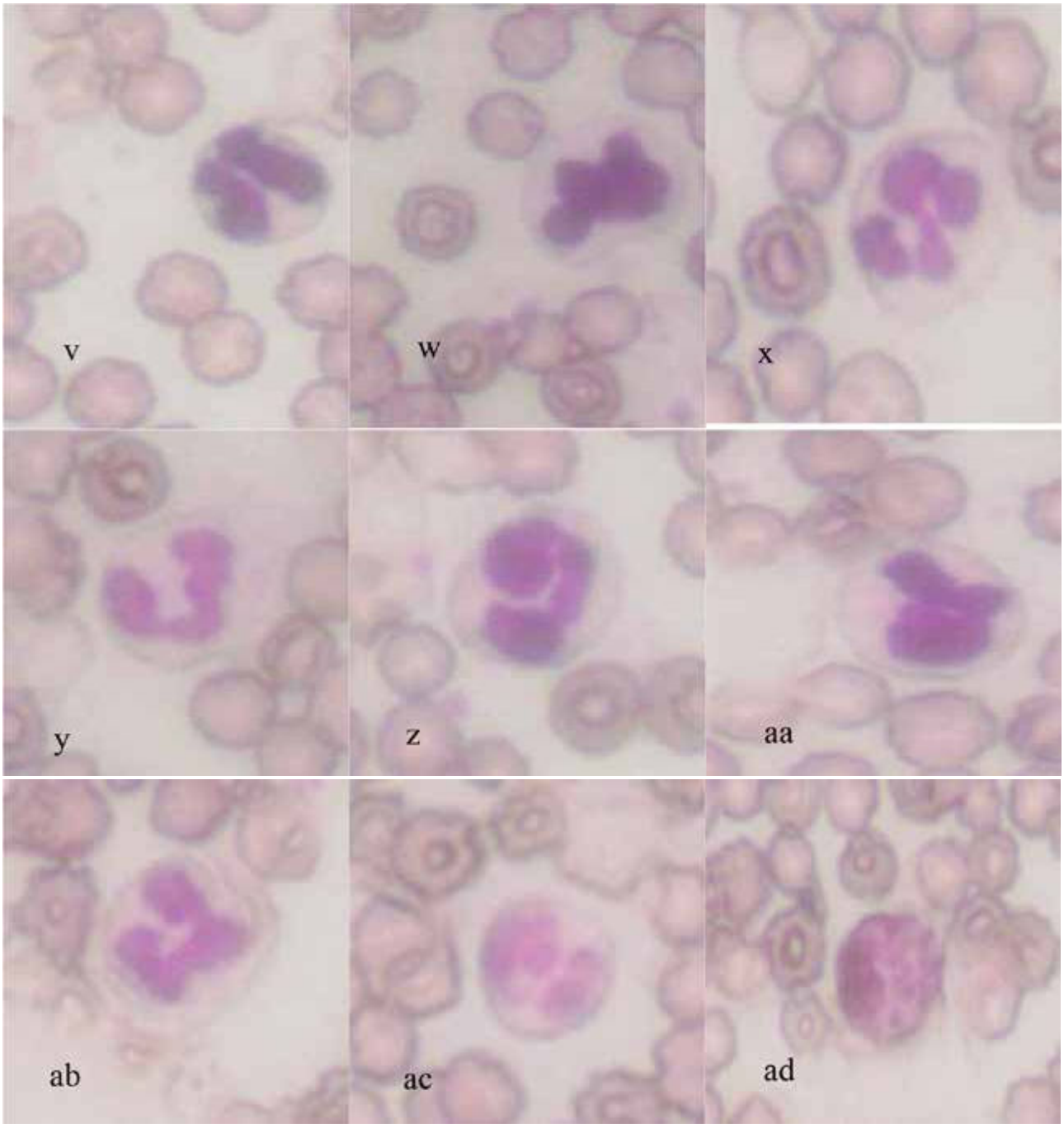

Fig. a. Small lymphocyte, **b & c.** Large lymphocytes d., **e & f.** Monocytes, **g & h.** Banded neutrophils, **i.** Trilobed neutrophil, **j.** S shaped neutrophil, **k.** Multilobed neutrophil, **m.** multilobed neutrophil, **n.** pear shaped neutrophil, **o.** Bilobed neutrophil, **p.** Segmented neutrophil, **q.** Multilobed neutrophil, **r.** Tetralobed neutrophil, **s., t., u., v., w., x., y., z., aa. & ab.** Multilobed neutrophils, ac., Eosinophil, ad. Basophil

CONCLUSION

Castration has a profound effect on the morphology of white blood cells of non-descriptive cattle, and this study can provide a baseline reference to which further studies may be compared. By this study, morphology of white blood cells in non-descriptive cattle can be well understood.

Source(s) of support: Nil

Conflicting Interest: Nil

REFERENCES

1. Adilli, N., Mohamed, M. & Omar, B. (2013). The influence of age, sex and altitude on the morphometry of red blood cells in bovine. *Vet*

World 6(8): 476–478. https://doi.org/10.5455/vetworld.2013.476-478

2. Adilli,N.,Mohamed,M.,Belabbas,H.&Achouri, A. (2014). Preliminary study of the influence of red blood cells size on the determinism of the breed in cattle. *Vet Med Int* 2014:1–4. https://doi.org/10.1155/2014/429495

3. Dash, I. & Mohanty, P.K. (2015). Morphological features and influence of age and breed on the morphometry of red blood cells of female cattle. *IJSR* 4(2): 259–264.

4. Dash, I. (2020). Morphometric study of red blood cells in non-descriptive cattle with respect to age and sex. *Comp Clin Pathol* 29:127-133.

5. Henricks, D.M., Gimenez, T., Gettys, T.W. & Schanbacher, B.D. (1988). Effects of castration and an anabolic implanton growth and serum hormones in cattle. *Animal Production* 46, 35–41.

6. Lobo, J., Youg-Shun See, E., Biggs, M. & Pandit, A. (2015). An insight intomorphometric descriptors of cell shape that pertain to regenerative medicine. *J Tissue Eng Regn Med.* https://doi.org/10.1002/term. 1994

7. Sánchez-Corrales, Y.E, Hartley, M., Jv R., Marée AFM. & Grieneisen, V. (2018). Morphometrics of complex cell shapes: lobe contribution elliptic Fourier analysis (LOCO-EFA). *EducTechnol Res Dev* 145: 156778. https://doi.org/10.1242/dev.156778