CASE REPORT

Indian Journal of Anesthesia and Analgesia
Volume 11 Number 4 October - December 2024
DOI: http: //dx.doi.org/10.21088/ijaa.2349.8471.11424.9

Anaesthetic Management of Pregnant Patient with Supraventricular Tachycardia posted for Emergency Caesarean Section

Bharath C J[1], Suresh Kumar N[2], Gagan M[3]

How to cite this article:
Bharath C J, Suresh Kumar N, Gagan M, Anaesthetic Management of Pregnant Patient with Supraventricular Tachycardia posted for Emergency Caesarean Section. Ind J Anesth Analg. 2024; 11(4):226-229.

Abstract

Introduction: This case report details the anaesthetic management of a pregnant patient with supraventricular tachycardia (SVT) undergoing an emergency caesarean section. SVT, a common arrhythmia in pregnancy, is initially treated with adenosine. When adenosine fails, calcium channel blockers like diltiazem are used, and amiodarone is considered as a third-line option before electrical cardioversion.

Case Report: In this case, a 19-year-old primigravida at 40 weeks 4 days presented with palpitations and SVT with a heart rate of 201 bpm despite adenosine and diltiazem. Amiodarone was successfully administered, reducing the heart rate to 143 bpm with visible P waves on ECG. Subsequently, she underwent an emergency caesarean section under spinal anaesthesia with 0.5% bupivacaine and fentanyl. Hypotension following the spinal anaesthesia was managed using phenylephrine and IV fluids, maintaining a stable intraoperative heart rate of 120-130 bpm.

Throughout the surgery, phenylephrine was used to prevent hypotension associated sympathetic stimulation, which could exacerbate SVT. Post-operatively, the patient maintained normal sinus rhythm, and after evaluation by a cardiologist and echocardiogram, no significant abnormalities were found. She was discharged after 7 days of postnatal care without recurrence of SVT or other arrhythmias.

This case highlights the complexity of managing SVT during pregnancy, necessitating a multidisciplinary approach involving anaesthesiologists and cardiologists. The choice of spinal anaesthesia over general anaesthesia was made based on its minimal cardiovascular impact and effective management of hemodynamic stability with vasoactive medications. Careful consideration of pharmacological interventions and their potential effects on both maternal and fetal health is crucial in such cases.

Conclusion: effective management of SVT during pregnancy involves tailored anaesthetic techniques and vigilant monitoring to ensure optimal maternal and fetal outcomes while addressing the arrhythmia and its associated hemodynamic challenges.

Keywords: Supraventricular Tachycardia (SVT), Pregnant women, Subarachnoid block, Adenosine, Amiodarone.

Author's Affiliation: [1]Junior Resident, [2]Professor & HOD, [3]Senior Resident, Department of Anaesthesiology, Sri Devaraj Urs Medical College, SDUAHER, Kolar, Karnataka, India.

Corresponding author: Suresh Kumar N, Professor & HOD, Department of Anaesthesiology, Sri Devaraj Urs Medical College, SDUAHER, Kolar, Karnataka, India.

E-mail: drskumar6@gmail.com

Received on: 16.09.2024

Accepted on: 16.10.2024

This work is licensed under a Creative Commons Attribution-NonCommercial-ShareAlike 4.0.

Key Messages: Effective anaesthetic management for pregnant patients with supraventricular tachycardia requires careful monitoring and coordination to ensure maternal and fetal safety during emergency caesarean section.

INTRODUCTION

Cardiac arrhythmias are not uncommon in pregnancy and they can be seen in pregnant women without any organic heart disease. Amongst arrhythmias supraventricular tachycardia is common in pregnant with or without structural heart disease. Here we present a case report of anaesthetic management of a full term primigravida who presented with supraventricular tachycardia (SVT) posted for emergency caesarean section

CASE REPORT

A 19 year-old primigravida with 40 weeks 4 days gestational age presented to emergency department with complaints of palpitations since one day without any history of cardiac disease. At presentation her blood pressure was 90/60 mm of Hg and pulse rate was 201 bpm. ECG shows regular heart rate of 194bpm without any P waves suggestive of Supraventricular Tachycardia (fig. 1), 3 injecting adenosine were given in the boluses of 6,12,12 mg. In view of persistent Supraventricular Tachycardia inspite of 3 doses of adenosine, injection Diltiazem 0.35mg/kg bolus was given, even diltiazem failed to correct Supraventricular Tachycardia. So injection amiodarone 150 mg in 100ml normal saline was given IV as bolus over 15 minutes followed by 1mg/min infusion initiated. Patient responded to Injection amiodarone and the heart rate decreased to 143 bpm (fig. 2) and P waves appeared on monitor. After which patient was posted for emergency caesarean section considering her gestational age and fetomaternal well being.

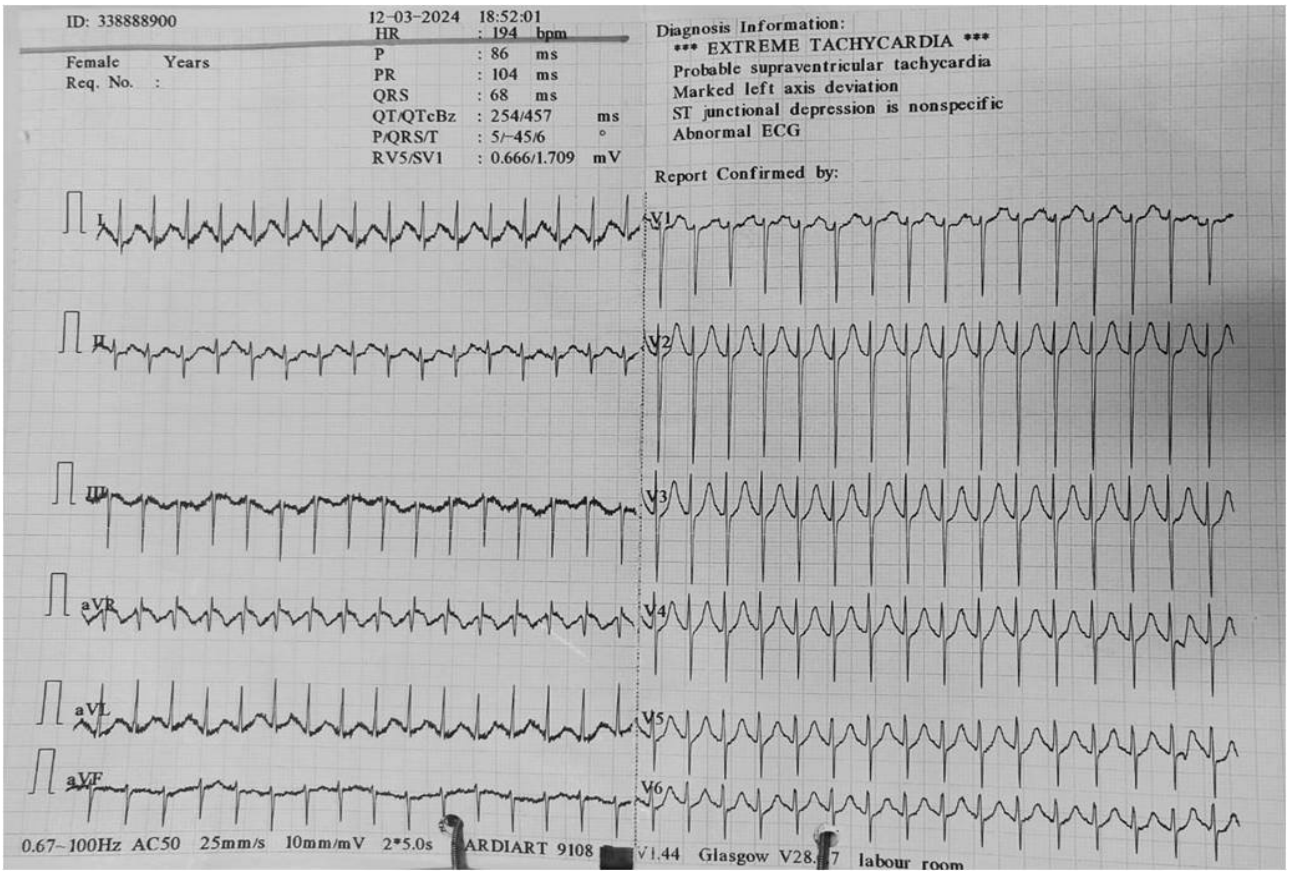

Fig. 1: SVT with heart rate of 194bpm

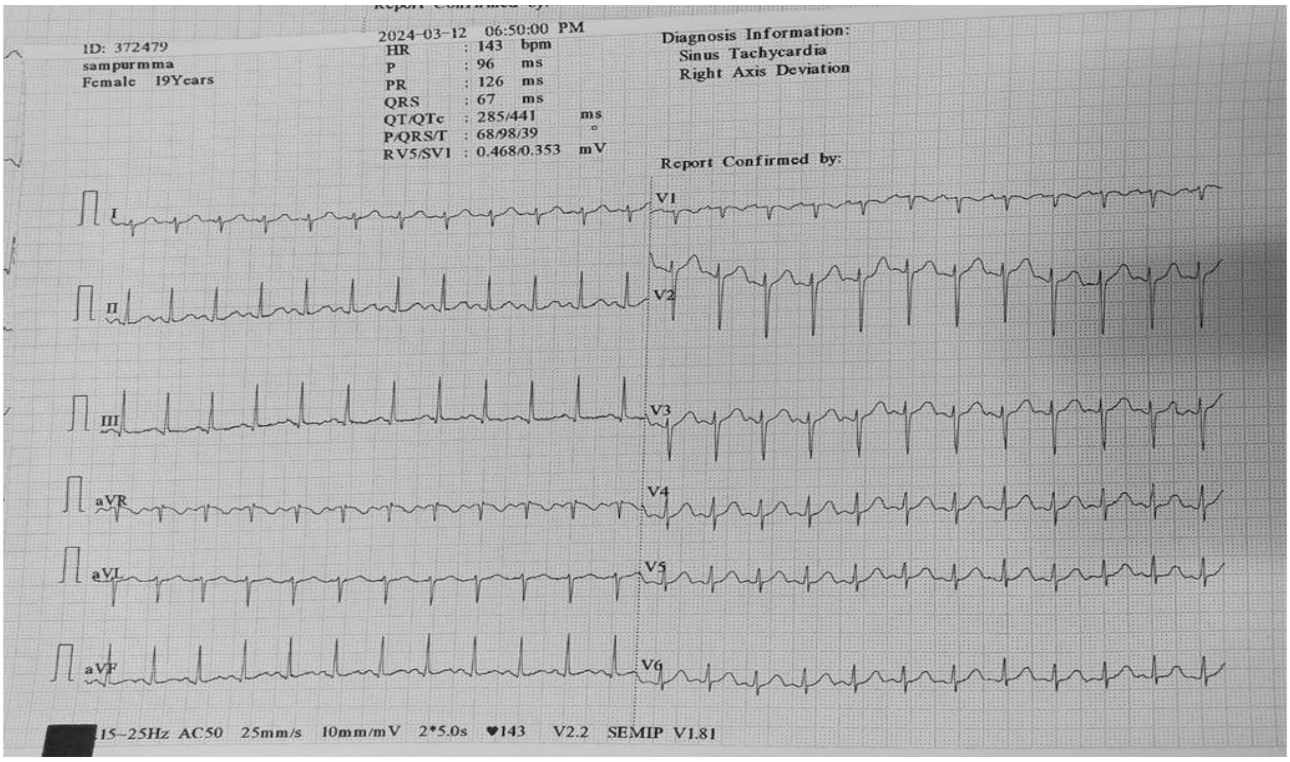

Fig. 2: P-waves seen (after SVT reverted)

Under aseptic precautions using 25G quincke spinal needle in L3-L4 interspace, Subarachnoid block (SAB) was given using 1.8ml of 0.5% bupivacaine heavy with 20 mcg of fentanyl as adjuvant injected into Subarachnoid space following free flow of CSF. Adequacy of the block checked. Hypotension following SAB was managed with bolus doses of 50mcg Injection. Phenylephrine along with IV. fluids intra-op. Throughout the intra-op period ECG in the monitor recorded heart rate of 120-130bpm. A healthy baby was delivered without any events. Intraoperatively injection oxytocin infusion of 5 IU per hour was used as uterotonic. Normal sinus rhythm was maintained in postoperative period. During the post-op period arrhythmias was reverted to sinus rhythm and heart rate was around 90-100bpm. Later cardiologist evaluated the patient and ECHO was done. No clinically significant abnormalities were found. Patient was discharged after 7 days of postnatal care without any recurrence of svt or any other kind of arrhythmias.

DISCUSSION

SVT

The management of anaesthesia for parturients experiencing Supraventricular Tachycardia during Caesarean delivery is complex. Anaesthetic strategies should prioritize avoiding factors that trigger cardiac ectopy, such as heightened sympathetic activity, electrolyte imbalances, and disturbances in acid-base equilibrium. Inhalational anaesthetics may lower the incidence of perioperative tachyarrhythmias by increasing refractoriness in accessory and atrioventricular pathways.[1] However, it is challenging to completely prevent sympathetic stimulation during intubation under general anaesthesia for Caesarean delivery. Hypotension associated with regional anaesthesia presents another concern. Considering this, epidural anaesthesia could be favoured over spinal anaesthesia. Nevertheless, we opted for spinal anaesthesia due to our team's greater experience with it compared to epidural anaesthesia, confident that hypotension can be effectively managed with appropriate interventions.

Several considerations arise for spinal anaesthesia during Caesarean delivery in this scenario. Reduced atrial filling, a consequence of spinal anaesthesia, is recognized as a risk factor for arrhythmias. Pre-loading with fluids can mitigate this reduction in atrial filling and also diminish the need for sympathomimetic agents, which have the potential to provoke Supraventricular Tachycardia. Sympathomimetics commonly used to manage hypotension during spinal anaesthesia

can themselves induce tachycardia. The combined administration of ephedrine and phenylephrine for hypotension control after spinal anaesthesia in Caesarean delivery prevents an increase in heart rate and effectively maintains blood pressure.[4] Throughout the surgery, we exclusively employed phenylephrine, gradually discontinuing it after Supraventricular Tachycardia cessation. Phenylephrine augments vagal tone by indirectly stimulating baroreceptor reflexes, thereby lowering the incidence of Supraventricular Tachycardia and potentially offering advantages over ephedrine.

Usually, the drug therapy approach employed in parturients resembles that in non-pregnant patients. Nevertheless, the impacts of antiarrhythmics on fetal development and uterine blood flow and contractions necessitate careful consideration. Therefore, initial non-pharmacological interventions such as vagal manoeuvres, Valsalva manoeuvre, and facial ice immersion should be attempted to halt tachycardia.[2] If these maneuvers prove ineffective, intravenous adenosine is preferred as the first-line medication due to its rapid action, high effectiveness, and short duration of action.[3]

CONCLUSION

SVT during pregnancy is attributed to hemodynamic variations, hormonal, autonomic, emotional disturbance during pregnancy.[5] Following treatment of Supraventricular Tachycardia, Subarachnoid block would be ideal anaesthetic technique for patient undergoing caesarean section as it is associated with minimal cardiovascular complications and hemodynamics stability can be managed effectively during the perioperative period with appropriate vasoactive medications. Supraventricular Tachycardia during pregnancy can be effectively treated with adenosine. In patients who are refractory to adenosine can be managed with calcium channel blockers like Diltiazem and verapamil. Thrid line medications like amiodarone can be used following calcium channel blockers before subjecting the patient to Synchronised electrical cardioversion.

Conflict of Interest: None

REFERENCES

1. Kim KO, Chang EJ, Han J, Cho H. Emergency cesarean delivery in a parturient who had an intractable paroxysmal supraventricular tachycardia-A case report. Korean Journal of Anesthesiology. 2012 Oct;63(4):360.
2. Conti E, Cascio ND, Paluan P, Racca G, Longhitano Y, Savioli G, Tesauro M, Leo R, Racca F, Zanza C. Pregnancy Arrhythmias: Management in the Emergency Department and Critical Care. Journal of Clinical Medicine. 2024 Feb 15;13(4):1095.
3. Andrianto A, Amadis MR, Mulia EP, Azmi Y. Paroxysmal supraventricular tachycardia in pregnancy: A case report. Bali Journal of Anesthesiology. 2023 Jul 1;7(3):179-82.
4. Robins K, Lyons G. Supraventricular tachycardia in pregnancy. British Journal of Anaesthesia. 2004 Jan 1;92(1):140-3.
5. Ramlakhan KP, Kauling RM, Schenkelaars N, Segers D, Yap SC, Post MC, Cornette J, Roos-Hesselink JW. Supraventricular arrhythmia in pregnancy. Heart. 2022 Nov 1;108(21):1674-81.