ORIGINAL ARTICLE

Indian Journal of Anesthesia and Analgesia
Volume 11 Number 4 October - December 2024
DOI: http: //dx.doi.org/10.21088/ijaa.2349.8471.11424.6

A Randomised Controlled Trial to assess the Efficacy of USG-Guided Platelet Rich Plasma Injection by Intra-Articular vs Rotator Interval Methods for Management of Periarthritis Shoulder

Shubham Rahul Rai[1], Nitin Hayaran[2]

How to cite this article:
Shubham Rahul Rai, Nitin Hayaran, A Randomised Controlled Trial to assess the Efficacy of USG-Guided Platelet Rich Plasma Injection by Intra-Articular vs Rotator Interval Methods for Management of Periarthritis Shoulder. Ind J Anesth Analg. 2024;11(4):209-215.

Abstract

Background: Periarthritis shoulder is a common cause of chronic shoulder pain. Conventionally, Intraarticular Platelet Rich Plasma (PRP) injection has been used for its treatment. Rotator cuff interval is involved in pathogenesis of adhesive capsulitis, so PRP injection at rotator interval can become an alternative to conventional intra-articular approach.

Aims: This randomised controlled trial was done to comparethe efficacy of PRP injection by intra-articular and rotator interval methods for management of periarthritis shoulder.

Methods: The study was carried out by randomising 60 patients, aged>18 years into two groups; group A (n=30, intraarticular) and group B (n=30, rotator interval). They were given 3-4 ml of freshly prepared PRP intra-articularly and at rotator interval under ultrasound guidance. The Shoulder Pain and Disability Index (SPADI), Numerical Rating Scale (NRS) score and post injection complications were assessed at 0, 1st and 3rd month in both the groups.

Results: The median NRS and SPADI scores were equivalent in both the groups at baseline. At 1st and 3rd month post injection, the median SPADI and NRS scores in group B were significantly lower than group A($p<0.05$). There were no reported complications from both the groups.

Conclusion: Both intra-articular and rotator interval methods of PRP injection were efficacious in pain reduction as well as in improving the shoulder functions, but rotator interval approach was more effective than intra-articular for management of periarthritis shoulder.

Keywords: Periarthritis shoulder, PRP, SPADI, NRS.

Author's Affiliation: [1]Senior Resident, [2]Professor, Department of Anesthesiology, Lady Hardinge Medical College, Delhi 110001, India.

Corresponding author: Shubham Rahul Rai, Senior Resident, Department of Anesthesiology, Lady Hardinge Medical College,Delhi 110001, India.

E-mail: raishubhamrahul@gmail.com

Received on: 27.08.2024

Accepted on: 27.09.2024

This work is licensed under a Creative Commons Attribution-NonCommercial-ShareAlike 4.0.

INTRODUCTION

Shoulder pain is the 3rd leading cause of musculoskeletal pain after backpain and neck pain.[1] Periarthritis shoulder/Frozen shoulder/ Adhesive capsulitis (AC) is a common condition resulting in insidious onset pain and global restriction of motion at the shoulder joint.[2] Peak incidence between 46 and 64 years of age, with females more often affected.[3] In recent studies, the rotator cuff interval has been implicated as the key structure in the pathogenesis of AC.

Platelet-rich plasma (PRP) contains growth factors and direct injection of PRP into the glenohumeral joint or rotator interval may effectively manage pain and stiffness of the shoulder joint in AC.[4]

METHODS

After approval from ethical committee, the trial was registered with CTRI No: CTRI/2021/03/032450, we conducted open label randomized controlled trial. Periarthritis shoulder patients aged >18 years with chronic shoulder pain for > 6 months & average NRS > 4was recruited for the study. All the patients were explained SPADI and NRS score before giving any therapy.

3-4 ml of freshly prepared PRP was injected under ultrasound guidance in Group A (Intraarticular) through posterior joint space and in Group B (Rotator interval) via anterior aspect of shoulder joint. Patients were asked to avoid any NSAIDS for 2 weeks after injection therapy and take tab tramadol 50mg as needed. Disability due to shoulder pain by SPADI[5] score, pain by NRS[6] and post injection complications were assessedat 0,1st and 3rd month post injection follow-up in both the groups.

In a study by Kothari et al[7] on efficacy of PRP injection at intraarticular shoulder joint in patients of Periarthritis Shoulder was 80% reduction from baseline in pain and disability at 3rd month follow-up. Assuming difference between two means=10, pooled standard deviation (SD) of 13 units, the study would require a sample size of 27 for each group to achieve a power of 80% and a level of significance of 5%. Thirty patients were included in final analysis. Considering 10% dropout, we enrolled 33 patients in each group.

Randomization was done by computer generated random table. The unique randomization code (1-66) was allocated and used to randomize consenting participant patients equally with no restrictions or bias to either of the two study groups. The results of the allocation by randomization will be concealed in sealed opaque envelopes mentioning the code and the group name. These envelopes with results of allocation were not seen by the research coordinator prior to sealing and were only kept by the co-ordinator after sealing. On the day of surgery, the co-ordinator will hand over an envelope to the principal investigator. The approach for the block procedure was decided by the group mentioned in the envelope. As the site of injection was different in the 2 groups blinding could not be possible.

Statistical analysis was performed by the SPSS program for Windows, version 28.0. Continuous variables are presented as mean ± SD Median (IQR), and categorical variables are presented as absolute numbers and percentage. Normally distributed continuous variables will be compared using the unpaired t-test. Continuous variables, values over time within the groups were analysed using repeated measures analysis of variance (ANOVA) followed by Bonferroni's post hoc testing. For all statistical tests, a p value less than 0.05 was taken to indicate a significant difference.

RESULTS

A total of 66 patients were recruited, 33 in each group. Three patients from both the groups were lost to follow-up. For the stastical analysis 30 patients aged >18 years, were included in the study.

Demographic profile of patients as follows (table 1).

Table 1: Demographic profile

		Group A(n=30)	Group B(n=30)	P value
Age (in years) (Mean ± SD)		50.37±9.72	49.27±9.41	0.658
Sex (frequency)	Female	21	19	0.584
	Male	9	11	

Study Flow Chart

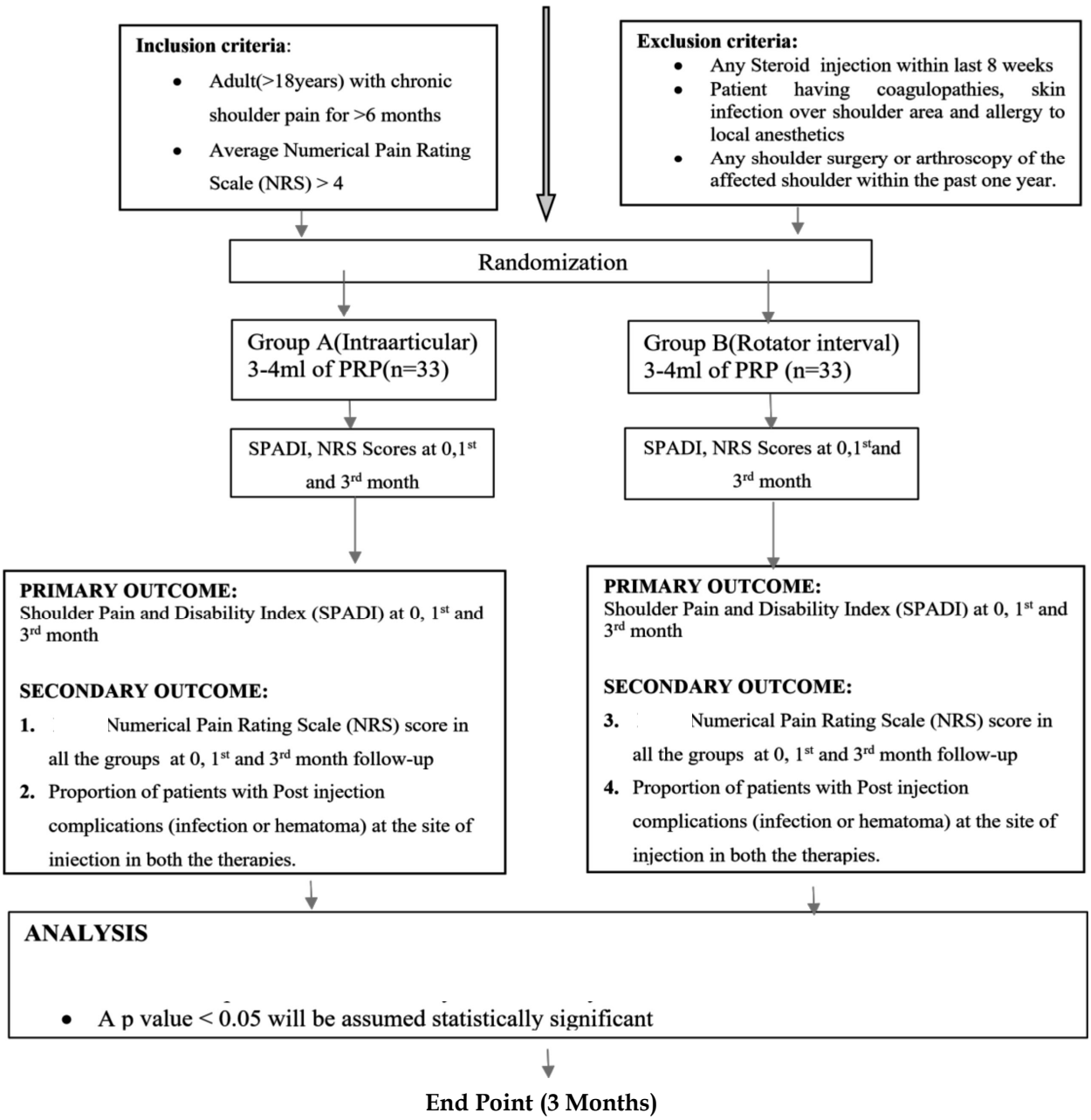

It was observed that there was no significant difference in median SPADI at baseline (p=0.875) while there was a significant difference observed at 1st and 3rd month (p=0.001, respectively) when compared between the two groups. In both the groups, it was observed that there was a significant difference in median SPADI when compared between Baseline with 1st and 3rd month (p <0.001, respectively) and between 1st and 3rd month (p <0.001) in each group (table 2).

Table 2: Comparison of SPADI at various time points between two groups

SPADI	Group A		Group B		p value
	Mean ± SD	Median (IQR)	Mean ± SD	Median (IQR)	
Baseline	106.53 ± 7.46	106.5 (101.75 - 112.25)	106.23 ± 7.26	106.5 (101.75 - 112.25)	0.875
1st Month	69.77 ± 9.88	71.5 (66 - 75.25)	58.90 ± 9.71	59.5 (51.5 - 66.25)	0.001
3rd Month	46.07 ± 7.42	47 (42 - 51.25)	31.83 ± 6.56	30.0 (27.0 - 37.5)	0.001

It was observed that there was no significant difference in median NRS at baseline (p=1.000) while there was a significant difference observed at 1st month (p=0.008) and at 3rd month (p=0.001) when compared between the two groups. In both the groups, it was observed that there was a significant difference in median NRS when compared between baseline with 1st and 3rd month (p <0.001, respectively) and between 1st and 3rd month (p <0.001) in each group (table 3).

In both the groups, 100% of the patients did not have any complications.

Table 3: Comparison of NRS at various time points between two groups

NRS	Group A		Group B		p value
	Mean ± SD	Median (IQR)	Mean ± SD	Median (IQR)	
Baseline	8.13 ± 0.78	8.0 (7.75 - 9.0)	8.13 ± 0.78	8.0 (7.75 - 9.0)	1.000
1st Month	5.83 ± 0.75	6.0 (5.0 - 6.0)	5.20 ± 1.03	5.0 (4.0 - 6.0)	0.008
3rd Month	3.47 ± 0.63	4.0 (3.0 - 4.0)	2.33 ± 0.88	2.0 (2.0 - 3.0)	0.001

DISCUSSION

Adhesive capsulitis, or frozen shoulder, is a common cause of shoulder pain.[8] It leads to global restriction of motion at the glenohumeral joint. It is often idiopathic, but there is an association with diabetes and previous trauma. It is primarily a clinical diagnosis, with night pain and significant loss of external rotation characteristic findings.[9]

AC progresses in 3 stages: freezing (painful), frozen (adhesive) and thawing. In freezing stage patients' complaint gradual onset diffuse shoulder pain typically worsens at night. Pain relief begin to occur during frozen stage with restricted range of motion at shoulder joint. Patient experiences gradual return of range of motion in thawing stage. Pathogenesis begins with inflammatory hyper vascular synovitis, which elicits a progressive fibroblastic change in the adjacent capsule. An inflammatory healing response is initiated, which leads to excess accumulation and propagation of fibroblasts. The imbalance between fibrosis and normal collagenous remodelling, leads to limitations of the shoulder joint. Thus, there is inflammation, thickening, and contracture of the joint capsule.

In recent studies, the rotator cuff interval has been implicated as the key structure in the pathogenesis of AC. The first component usually affected is the coracohumeral ligament. The anterior capsule and rotator interval are primarily involved in adhesive capsulitis. The rotator interval is a triangular space formed by the boundaries of the supraspinatus, subscapularis, and coracoid process, in the anteromedial aspect of the shoulder. It contains the intra-articular long head of biceps tendon, coracohumeral (CHL), and superior glenohumeral ligaments (SGHL). The floor of the interval is the SGHL and anterior joint capsule. The roof is formed by the CHL, a broad structure arising from the lateral aspect of the coracoid, passing over the anterior shoulder, and inserting into the greater and lesser tuberosities of the humerus merging with the anterior joint capsule. Contracture and thickening of the CHL is a frequent finding in adhesive capsulitis.[9-11] Aim of the treatment is pain management and improving the shoulder function, thereby improving the overall quality of life.

Despite many studies on PRP treatment in various joint diseases, there are scarce comparative data on the use of PRP in adhesive capsulitis. The effectiveness of PRP therapy in patients with adhesive capsulitis has been observed. There is paucity of literature on the most effective site of PRP injection for the management of periarthritis shoulder (Rotator Interval vs Intraarticular). The primary objective of our study was to compare the improvement in SPADI score in both the groups after 1st and 3rd month of the injection. The secondary objectives were to compare the pain by decrease in NRS in both the groups after 1st and 3rd month of the injection and to study for any complications in both the groups.

Our results showed that median SPADI scores were equivalent in both the groups at baseline (table 2) (p=0.875). In both the groups, there was a significant decline in median SPADI score at 1st and 3rd month post injection (p<0.001). Significant improvement in pain and shoulder function was

observed over a period of time from baseline to 3 months in both the groups. When the 2 groups were compared, the median SPADI score in group B were significantly lower than group A at the end of 1st and 3rd month post injection. Similarly, Median NRS scores were equivalent in both the groups at baseline (table 3) (p=1). In both the groups, there was a significant decline in median NRS score at 1st and 3rd month post injection (p<0.001). Significant improvement in pain was observed over a period of time from baseline to 3rd month in both the groups. When the 2 groups were compared, the median NRS score in group B were significantly lower than group A at the end of 1st and 3rd month post injection.

On extensive literature search, no study comparing the PRP injection between intra-articular and rotator interval route could be found. The intra-articular and the rotator interval route have been compared for injection of corticosteroid for the management of periarthritis shoulder.

Elnady et al[11] in their study found that both rotator interval and intra-articular groups showed significant improvement after 3 months of corticosteroid injection. They also observed statistically significant improvement after corticosteroid injection via rotator interval regarding pain, Range of Movement (ROM) and function (SPADI) in patients rather than with the posterior approach. We also observed significant improvement in the functional score when PRP was injected via rotator interval route. Wang et al[12] compared the hydrodilatation with triamcinolone acetonide via rotator cuff interval and posterior glenohumeral recess approaches. Both the groups experienced improvement in shoulder functionality (SPADI score) at 3 months after the injection but the SPADI scores were comparable in both the groups. Similarly, Cho et al[13] also observed significant improvement in both rotator interval and posterior capsule approach intra-articular corticosteroid injection. Though the ASES Score and SSV value were comparable at 12 weeks, there was better improvement in forward flexion and abduction in the rotator interval group. The corticosteroid injected via both the routes in these studies will have a limited duration of action and functional outcome at 3 months cannot be attributed by the steroid injection via these routes. Sun et al[14] also showed significant improvement in Constant score and DASH score in rotator interval than intra-articular and subacromial group. Our study results showed stastically significant improvement of SPADI scores on injection of platelet rich plasma via the Rotator interval group as compared to Intra-articular method.

Intra-articular PRP injection has shown improvement in Constant and Murley shoulder score significantly at 1 month from baseline in the study by Agrawal et al[15] which is similar to the findings of our study. Similarly, in another study by Kumar et al[16] there was a significant reduction in DASH score at 8 weeks follow period following intra-articular injection of PRP. Efficacy of PRP injection via rotator interval route has not been studied yet. This study of comparison of PRP injection via rotator interval and intra-articular route was planned after observing the results of the studies comparing the two routes with corticosteroid injection. Our study has observed significant improvement in shoulder disability with the both the routes of PRP injection, with rotator interval route superior to intraarticular route in terms of improvement in SPADI score.

On comparing the two routes of corticosteroid for adhesive capsulitis injection (RI vs IA), most of the studies have observed significant improvement in pain as well as the functional score. In the study Elnady et al[11] the reduction in pain scores at 3 months was stastically significant in rotator interval (RI) group as compared to the intraarticular (IA) route (VAS=2.19 vs 3.04). Similar findings were also observed in the study conducted by Yoon et al[17] and Sun et al.[14] Similar pain scores were observed after 12 weeks post injection of corticosteroid via both the routes in the studies by Cho et al[13] and Wang et al.[12]

PRP injection for the management of adhesive capsulitis of shoulder have shown increasing results in terms of both pain scores and functional outcomes. Barman et al[18] showed significant improvement in pain scores with intraarticular PRP injection from baseline to 12-week post injection. The VAS score was significantly low in patients receiving intra-articular PRP as compared to intra-articular steroid. In another study by Shahzad et al[19] revealed that intra-articular injection of PRP resulted in a substantial improvement in Visual Analog Scale (VAS) score when compared to intra-articular corticosteroid injection. Even a study by Kumar et al with 1 month follow up after intra-articular autologous PRP injection demonstrated that it was very effective in reducing the pain level of the patients. Our study results also show similar trends of pain scores of intra-articular and rotator interval PRP injection with rotator interval route significantly better than intra-articular route in terms of pain at 3 months post injection.

None of the patients in both the group reported

any complications in our study. Most of the reported literature did not find any serious complications with both the approaches.

Our study is limited by certain factors. Periarthritis shoulder is accompanied by progressive restriction in active and passive ROM of shoulder joint. Pre-injection and post-injection evaluation of the ROM was not done in our study. The ROM evaluation may have added an additional dimension to the efficacy of these two routes of PRP injection.

CONCLUSION

Both intra-articular and rotator interval methods of PRP injection were efficacious in pain reduction as well as in improving the shoulder functions, but rotator interval approach was more effective than intra-articular for management of periarthritis shoulder. Based on the results of our study, routine application of PRP injection via rotator interval approach can be recommended.

REFERENCES

1. Dighriri YH, Akkur MA, Alharbi SA, Madkhali NA, Matabi KI, Mahfouz MS. Prevalence and associated factors of neck, shoulder, and low-back pains among medical students at Jazan University, Saudi Arabia: A cross-sectional study. J Family Med Prim Care. 2019; 8: 3826-31.
2. Mezian K, Coffey R, Chang KV. Frozen shoulder. InStatPearls [Internet] 2021. StatPearls Publishing.
3. Wáng YX, Wáng JQ, Káplár Z. Increased low back pain prevalence in females than in males after menopause age: evidences based on synthetic literature review. Quant Imaging Med Surg. 2016; 6: 199-206.
4. Aslani H, Nourbakhsh ST, Zafarani Z, Ahmadi-Bani M, Ananloo ME, Beigy M et al. Platelet-Rich Plasma for Frozen Shoulder: A Case Report. Arch Bone Jt Surg. 2016; 4: 90-3.
5. Roach KE, Budiman Mak E, Songsiridej N, Lertratanakul Y et al. Development of a shoulder pain and disability index. Arthritis & Rheumatism: Official Journal of the American College of Rheumatology. 1991; 4: 143-9.
6. Hjermstad M.J., Fayers P.M., Haugen D.F., Caraceni A., Hanks G.W., Loge J.H. et al. Studies comparing numerical rating scales, verbal rating scales, and visual analogue scales for assessment of pain intensity in adults: a systematic literature review. *J Pain Symptom Management*. 2011; *41*: 1073-1093.
7. Kothari SY, Srikumar V, Singh N. Comparative Efficacy of Platelet Rich Plasma Injection, Corticosteroid Injection and Ultrasonic Therapy in the Treatment of Periarthritis Shoulder. J Clin Diagn Res. 2017; 11: RC15-RC18.
8. Murphy RJ, Carr AJ. Shoulder pain. BMJ Clin Evid. 2010; 22: 1107.
9. Yoong P, Duffy S, McKean D, Hujairi NP, Mansour R, Teh JL. Targeted ultrasound-guided hydrodilatation via the rotator interval for adhesive capsulitis. Skeletal Radiol. 2015; 44: 703-8.
10. McKean D, Chung SL, te Water Naudé R, McElroy B, Baxter J, Pendse A et al. Elasticity of the coracohumeral ligament in patients with frozen shoulder following rotator interval injection: a case series. Journal of Ultrasonography. 2020; 20: 300-6.
11. Elnady B, Rageh EM, Hussein MS, Abu-Zaid MH, Desouky DE, Ekhouly T et al. In shoulder adhesive capsulitis, ultrasound-guided anterior hydrodilatation in rotator interval is more effective than posterior approach: a randomized controlled study. Clinical rheumatology. 2020; 39: 3805-14.
12. Wang JC, Tsai PY, Hsu PC, Huang JR, Wang KA, Chou CL et al. Ultrasound-Guided Hydrodilatation with Triamcinolone Acetonide for Adhesive Capsulitis: A Randomized Controlled Trial Comparing the Posterior Glenohumeral Recess and the Rotator Cuff Interval Approaches. Front Pharmacol. 2021; 12: 686139
13. Cho CH, Kim DH, Kim DH, Choi BC, Kim SG, Lee DG et al. Comparative Efficacy of Rotator Interval Versus Posterior Capsule Approach Intraarticular Corticosteroid Injections for Primary Frozen Shoulder: A Single-blind, Randomized Trial. Pain Physician. 2022; 25: 313-321.
14. Sun Y, Liu S, Chen S, Chen J. The effect of corticosteroid injection into rotator interval for early frozen shoulder: a randomized controlled trial. The American Journal of Sports Medicine. 2018; 46: 663-70.
15. Agrawal AC, Nayak B, Sakale H. Management of adhesive capsulitis of shoulder joint by single platelet rich plasma injection. Journal of Orthopedics, Traumatology and Rehabilitation. 2019; 11: 62.
16. Kumar P, Prakash D. assessment of effectiveness of intra articular autologous platelet rich plasma injection in the management of adhesive capsulitis of shoulder joint. International Journal of Orthopaedics. 2019; 5: 1085-7.
17. Yoon JP, Chung SW, Kim JE, Kim HS, Lee HJ, Jeong WJ et al. Intra-articular injection, subacromial injection, and hydrodilatation for

primary frozen shoulder: a randomized clinical trial. Journal of shoulder and elbow surgery. 2016; 25: 376-83.

18. Barman A, Mishra A, Maiti R, Sahoo J, Thakur KB, Sasidharan SK. Can platelet-rich plasma injections provide better pain relief and functional outcomes in persons with common shoulder diseases: a meta-analysis of randomized controlled trials. Clin Shoulder Elb. 2022; 25: 73-89

19. Shahzad HF, Taqi M, Gillani SF, Masood F, Ali M. Comparison of Functional Outcome Between Intra-Articular Injection of Corticosteroid Versus Platelet-Rich Plasma in Frozen Shoulder: A Randomized Controlled Trial.