DOI: 10.21088/ija.2320.0022.14225.4

Indian Journal of Anatomy
Volume 14 Number 2 May - August 2025

CASE REPORT

Case Report on Anatomical Dissection Table Findings: Variations in the Formation of the Portal Vein

Pragya Upadhyay[1], Sarah Sangma[2], Charushila Rukadikar[3]

HOW TO CITE THIS ARTICLE:

Pragya Upadhyay, Sarah Sangma, Charushila Rukadikar. Case Report on Anatomical Dissection Table Findings: Variations in the Formation of the Portal Vein. Ind Jr Anat. 2025; 14(2): 63-67.

ABSTRACT

Background: Anatomical variations in the formation of the portal vein are frequently encountered during cadaveric dissections and can have profound clinical implications in hepatic surgeries and interventions. Despite being well-documented in literature, these variants often remain underrecognized in routine surgical practice and medical training.

Aim and Objective: To document and analyze a rare anatomical variation in the formation of the portal vein observed during routine cadaveric dissection and raise clinical awareness about variations in portal venous confluence that may affect surgical approaches and outcomes.

Material and Methods: A routine dissection was performed on an 84-year-old female cadaver in the Department of Anatomy, AIIMS-Gorakhpur. Observations regarding the formation of the portal vein were documented both diagrammatically and through photographic evidence. Standard anatomical references and literature were consulted to classify and compare the observed variation.

Result: The portal vein was found to be formed by the convergence of the superior mesenteric vein (SMV), splenic vein (SV), and notably, the inferior mesenteric vein (IMV) contributing directly at the confluence—an uncommon variant aligning with Type II of Thomson's classification.

Conclusion: This case highlights a clinically relevant variation in portal vein formation with potential implications for hepatic surgeries, liver transplantations, and interventional radiology. Early recognition through imaging or dissection is critical for effective surgical planning and minimizing complications.

AUTHOR'S AFFILIATION:

[1] 3rd Year MBBS Student, All India Institute of Medical Sciences, Gorakhpur, Uttar Pradesh, India.

[2] Assistant Professor, Department of Anatomy, All India Institute of Medical Sciences, Gorakhpur, Uttar Pradesh, India.

[3] Assistant Professor, Department of Physiology, All India Institute of Medical Sciences, Gorakhpur, Uttar Pradesh, India.

CORRESPONDING AUTHOR:

Pragya Upadhyay, 3rd Year MBBS Student, All India Institute of Medical Sciences, Gorakhpur, Uttar Pradesh, India.

E-mail: pragyaupadhyaybhu@gmail.com

➢ **Received:** 21-05-2025 ➢ **Revised:** 04-08-2025

Creative Commons Non Commercial CC BY-NC: This article is distributed under the terms of the Creative Commons Attribution NonCommercial 4.0 License (http://www.creativecommons.org/licenses/by-nc/4.0/) which permits non-Commercial use, reproduction and distribution of the work without further permission provided the original work is attributed as specified on the Red Flower Publication and Open Access pages (https://www.rfppl.co.in)

KEYWORDS

• Portal vein • Anatomical variation • Inferior mesenteric vein • Cadaveric dissection • Surgical anatomy • Venous confluence

INTRODUCTION

Anatomical knowledge is fundamental to clinical medicine, underpinning our understanding of the human body's structure, functions, and dysfunctions. It provides the foundation upon which diagnostic, therapeutic, and surgical interventions are built. Dissection, which is a cornerstone of medical education, offers students and professionals the invaluable opportunity to study human anatomy directly. As medical science evolves, the frequency of identifying anatomical variations during routine dissections has increased. Anatomical variations in the portal vein are not uncommon, with studies reporting a prevalence ranging from 20% to 35% in the general population.[1]

This case report documents a unique variation in the formation of the portal vein discovered during a routine anatomical dissection at the Department of Anatomy, AIIMS-Gorakhpur.

Anatomical Aspect of Portal Vein:

In typical anatomy, the splenic vein (SV) generally joins the superior mesenteric vein (SMV) in front of the inferior vena cava (IVC) and behind the pancreatic neck, forming the Portal Vein, as drawn in fig no. 2. This vein ascends within the hepatoduodenal ligament, running posterior to the hepatic artery and common bile duct, and continues toward the hepatic hilum where it bifurcates into right and left branches. The left portal vein runs horizontally for a brief distance before it turns upward and branches off to supply Couinaud hepatic segments I, II, III, and IV. The right portal vein divides into anterior and posterior branches, with the anterior branch serving segments V and VIII, while the posterior branch supplies segments VI and VII.[2]

Physiological Aspect of Portal Vein:

The portal vein plays a vital role in maintaining the liver's function by transporting blood from the digestive organs including the stomach, intestines, pancreas, and spleen directly to the liver. This blood carries nutrients absorbed from food, as well as toxins and waste products that the liver needs to process. From a physiological standpoint, the anatomical change can affect how blood is distributed within the liver lobes, as different parts of the liver receive blood from different branches of the portal vein. If this flow is altered due to variation in vein formation, it might influence nutrient delivery, detoxification efficiency, and local immune responses in specific liver segments.

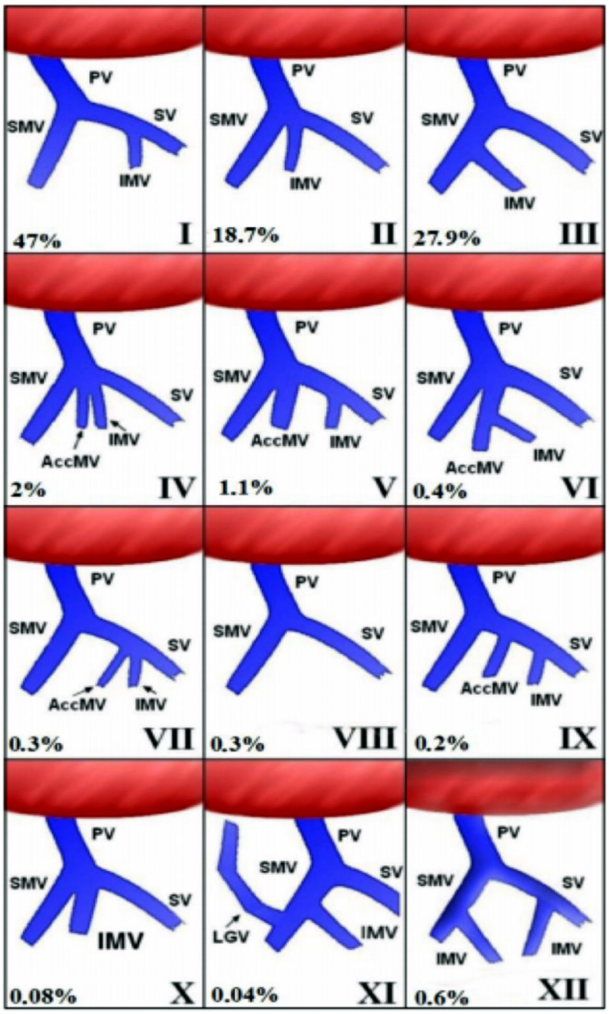

Figure 1: Some anatomical variations of the abdominal portal system structure, according to Thomson (1890) classification 23

Type I: IMV as a tributary of the SV; type II: three veins constitute the portal vein, i.e. SMV, IMV, and SV; type III: IMV as a tributary of the SMV; type IV: AccMV at the angle of portal confluence; type V: two SMVs and the IMV constitute the PV; type VI: IMV is tributary of the SMV; type VII: AccMV is tributary of the PV together with

the IMV; type VIII: absence of IMV; type IX: AccMV as tributary of the PV; type X: two SMVs constitute the PV; type XI: LGV as tributary of the SMV; type XII: two IMVs, one a tributary of the SMV and the other a tributary of the SV. PV: portal vein, SV: splenic vein, SMV: superior mesenteric vein, IMV: inferior mesenteric vein, AccMV: accessory mesenteric vein, LGV: left gastric vein.

Incidence of variations in portal vein:

The first study on variations of the portal vein (PV) tributaries was published by Thomson *et al.*[3], who categorized them into three distinct types:

Type I - IMV as tributary of the SV

Type II - Trifurcation in the PV, formed by the union of the SMV, IMV, and SV

Type III - IMV as tributary of the SMV

Despite the existence of many anatomical works on the PV, its variations continue to be described, as portrayed in *Figure 1*, and sometimes, they are unprecedented.

CASE REPORT

During a routine dissection for undergraduate medical training at the Department of Anatomy, AIIMS-Gorakhpur, a variation in the formation of the portal vein was identified in a female cadaver of normal build, aged 84 years at the time of death. The portal vein, typically formed by the convergence of the SMV and SV, was observed to include the IMV as a direct contributor, at the neck of pancreas, as drawn in *Figure 3*. The real photographs are attached herewith for detailed delineation (*Figure 4*, *Figure 5*).

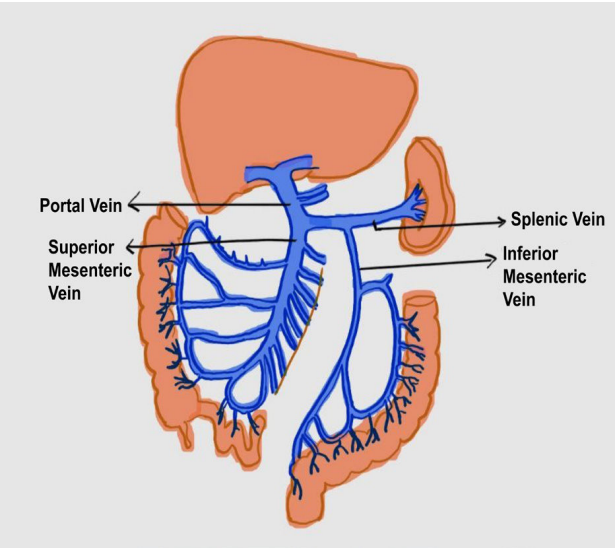

Figure 2: Normal anatomy of formation of portal vein

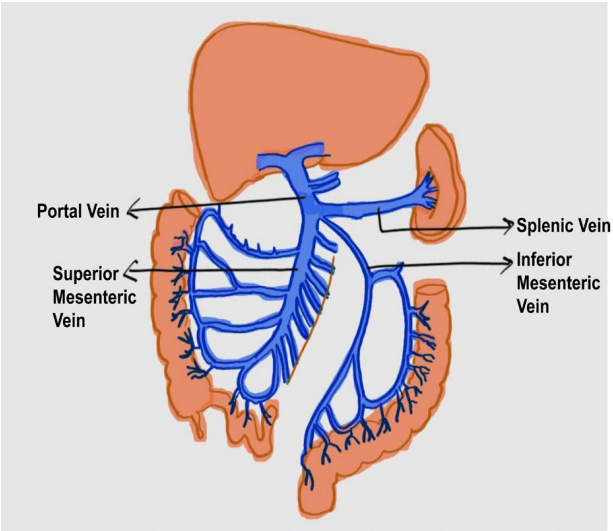

Figure 3: Findings during dissection: Variation of formation of portal vein

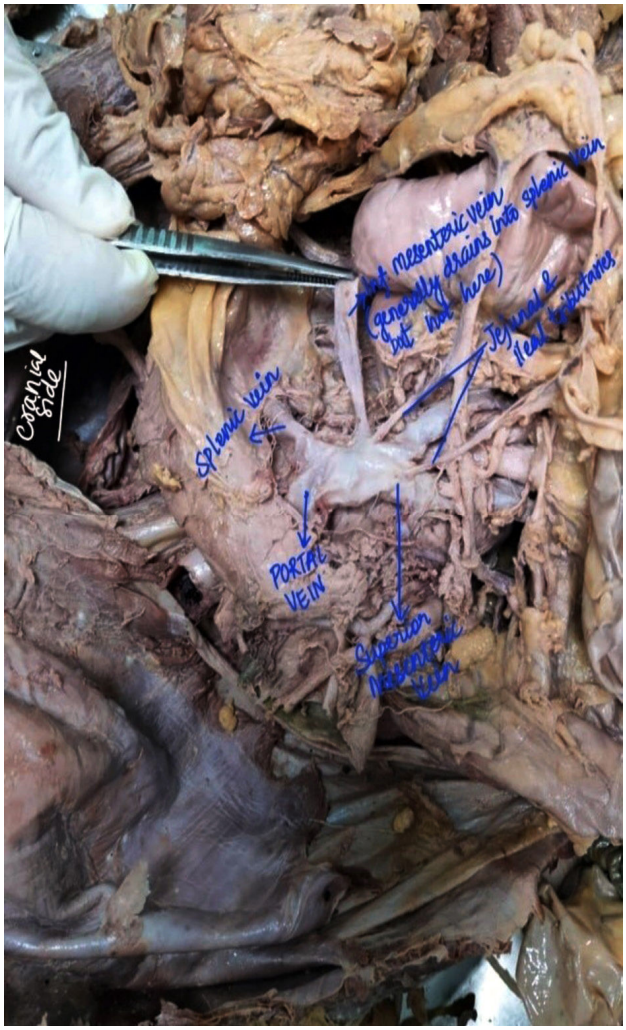

Figure 4: Photograph of the cadaveric dissection showing the variation in the formation of the portal vein. The Inferior Mesenteric Vein (IMV) is seen contributing directly to the confluence of the Superior Mesenteric Vein (SMV) and Splenic Vein (SV)

Figure 5: Detailed photograph showing the tributaries of the portal vein in a cadaveric specimen, highlighting the contributions of the SMV, SV, and IMV to the portal vein

DISCUSSION

This study corroborates a study based on 113 cadaveric dissections done by Weinhaus, A.J. *et al.* at the University of Minnesota which reported that the inferior mesenteric vein drained into the splenic vein in 36.3% of cases, the superior mesenteric vein in 41.6% of cases, and the junction between the superior mesenteric vein and the splenic vein in 21.2% of cases. [Weinhaus AJ, Henderson][4]

Although rare, these variations can be encountered during procedures such as Whipple surgery (gastro duodenopancreatectomy), hepatectomy, venous bypasses, among others. Prior knowledge of such variations allows for better surgical planning and helps to prevent intraoperative hemorrhages. Recognizing portal vein variations is crucial in surgical planning, as unanticipated anatomical differences can lead to complications such as ischemia or inadequate liver remnant post-resection (Covey *et al.,* 2004).[5]

Embryological Consideration

The development of the portal venous system is closely tied to embryogenesis, specifically the transformation of the vitelline venous system during the 4th to 12th weeks of gestation. The vitelline vein gives rise to one of the three major veins in an embryo. It splits off into the PV, which develops into one of the body's major veins. The right and left vitelline veins unite about five weeks of gestation to create a venous plexus that encircles the duodenum. This venous plexus has three parts: two on the ventral side of the duodenum and one on the dorsal side of the duodenum. This plexus then terminates in the sinus venosus. By 10 weeks, a part of this venous plexus selectively dissolves, forming the adult PV. The right vitelline vein forms the right PV, the left vitelline vein forms a ventral anastomosis with the left PV, and the left vitelline vein forms the main PV. Variations in the growth of the venous plexus and selective involution lead to PV variance (Layton & Lapsia, 2023)., (Tyagi G, Jha RK)[6-7]

Clinical Significance

Understanding variations in the portal vein's anatomy is crucial for surgical planning and outcomes. In procedures such as liver transplantation, hepatectomy, and other hepatic surgeries, unrecognized vascular anomalies can lead to complications. Accurate preoperative imaging using modaliti es like CT, MRI, or angiography is essential to map vascular anatomy and anticipate potential challenges. In liver transplantation, precise knowledge of vascular variations ensures safe graft anastomosis and reduces the risk of complications such as ischemia or portal hypertension. Similarly, in hepatic resections, awareness of these anomalies minimizes the risk of venous injury or disruption. Surgeons need to be vigilant and adaptable, tailoring their approaches based on individual anatomical variations. In this context, detailed preoperative planning becomes a cornerstone of successful surgical interventions. Preoperative imaging modalities like multidetector computed tomography (MDCT) are instrumental in identifying portal vein variations, thereby aiding in surgical planning and reducing intraoperative risks (Varotti *et al.,* 2004).[8] The

variation observed in this case report also has implications for interventional radiology. Procedures such as transjugular intrahepatic portosystemic shunt (TIPS) placement or portal vein embolization require a thorough understanding of the patient's vascular anatomy to ensure precise catheter placement and avoid complications. Misinterpretation of vascular anatomy due to unrecognized variations could lead to procedural failure or adverse outcomes.[9-10]

CONCLUSION

This case highlights an important anatomical variation in the formation of the portal vein, where the IMV directly contributes to the confluence with the SMV and SV. Although previously documented, such variations remain under appreciated in clinical practice. Recognizing and understanding these anomalies is essential for improving surgical outcomes, particularly in liver-related procedures. Anomalies like this emphasize the need for continuous updates to anatomical knowledge and heightened awareness among clinicians and surgeons. Educational curricula for medical students and surgical trainees should incorporate discussions on anatomical variations, emphasizing their clinical relevance. Future research with larger cadaveric studies and advanced imaging techniques will further illuminate the prevalence and implications of these variations, enhancing both clinical practice and medical education. Additionally, integrating these findings into digital anatomical atlases and simulation-based training programs could provide clinicians with more comprehensive resources for understanding vascular anatomy.

ACKNOWLEDGMENT

We extend our gratitude to the Department of Anatomy, AIIMS-Gorakhpur, for their support and resources in conducting this dissection and preparing this report. Special thanks to the faculty and students involved in documenting this anatomical variation. Their dedication and attention to detail have made this study possible, contributing to the broader understanding of anatomical variations and their clinical significance.

REFERENCES

1. Schmidt S., Demartines N., Soler L., Schnyder P., Denys A. Portal Vein Normal Anatomy and Variants: Implication for Liver Surgery and Portal Vein Embolization. Semin Intervent Radiol. 2008; 25(2): 86–91. doi:10.1055/s-2008-1076688.
2. Carneiro C., Brito J., Bilreiro C., Barros M., Bahia C., Santiago I., Caseiro-Alves F. All about portal vein: A pictorial display to anatomy, variants and physiopathology. Insights Imaging. 2019 Mar 21; 10(1): 38. doi: 10.1186/s13244-019-0716-8.
3. Thomson A. Report of the Committee of Collective Investigation of the Anatomical Society of Great Britain and Ireland for the Year 1889-90. J Anat Physiol. 1890; 25(Pt 1): 89-101.
4. Weinhaus A.J., Henderson. Variation of the drainage pattern of the Inferior Mesenteric Vein. Clinical Anatomy. 2011; 24(8): 1016-1042.
5. Covey A.M., Brody L.A., Maluccio M.A., Getrajdman G.I., Brown K.T. Variant portal vein anatomy: implications for transhepatic portal vein embolization. Radiology. 2004; 230(3): 735–739. doi:10.1148/radiol.2303030805.
6. Layton B.M., Lapsia S.K. The Portal Vein: A Comprehensive Review. Radio Graphics. 2023; 43(6): e230058. doi:10.1148/rg.230058.
7. Tyagi G., Jha R.K. Portal Vein Variations, Clinical Correlation, and Embryological Explanation: A Review Article. Cureus. 2023 Mar 20; 15(3): e36400. doi: 10.7759/cureus.36400.
8. Varotti G., Gondolesi G.E., Goldman J., *et al.* Anatomical variations in right liver living donors. Am J Transplant. 2004; 4(4): 681–687. doi:10.1111/j.1600-6143.2004.00388.x.
9. Zhu Y., Zhang X., Yang L., *et al.* Variations in portal venous anatomy and their implications in surgical planning for liver transplant. Liver Transplantation. 2013; 19(5): 527-533.
10. Chong E., Lee A., Bicknell R. Surgical implications of portal venous system variations: Case report and literature review. International Journal of Surgery. 2017; 45: 28-34.